

ORIGINAL ARTICLE

DYING ARTERIOVENOUS FISTULAS - ALL IS NOT LOST YET!

Kishwar Ali, Humera Latif, Nauman Imtiaz Khan, Hafiz Khalid Parvaiz Butt, Rai Ahmad Khan, Fazal e Haider

Vascular & General Surgery, Combined Military Hospital, Rawalpindi-Pakistan

Background: The aim of this study was to see the efficacy of different surgical procedures performed for the salvage of failing arteriovenous fistulas. **Study design:** Prospective observational study. Study was conducted at Department of Vascular surgery, CMH Rawalpindi from 1st August 2017 to 31st December 2018 **Methods:** Those surgical procedures were included which were done for the AVFs that failed to mature due to stealing veins or developed complications like thrombosis, hematoma, pseudo or true aneurysm, steal syndrome, stenosis and venous hypertension. The procedures like stealing vein ligation, hematoma evacuation, thrombectomies, redo-anastomosis, pseudo aneurysm excision, aneurysmorrhaphies, excision of stenotic segment, RUDI for steal syndrome and central veno venous bypasses for central vein occlusion were assessed for their efficacy. **Results:** Sixty-two patients were included. 21 stealing veins were ligated, 15 for fistula maturation and 6 for venous hypertension. Twelve out of these 15 non-maturing AVFs, matured after ligation of stealing vein (80%). In case of reverse vein ligation for venous hypertension all the 6 patients showed reduction in their limb swelling (100%). Nine thrombectomies were performed, 7 were successful (78%). Nine patients presented with stenosis. In 3 patients with stenosis near the anastomotic site, a proximal AVF was formed. In 2 patients the stenotic segment was excised and end to end anastomosis was done. In 1 patient an interposing vein graft was used. In 3 patients, the flow was redirected to basilic vein. All the patients had patent AVF on follow up (100%). In 8 non-infected pseudo aneurysms, excision and end to end anastomosis was done in 3, aneurysmorrhaphies in 2 and revision of the anastomosis in 3 cases. Seven out of 8 (87.5%) had good patency on follow up. In 7 patients with true aneurysm and 3 with bleeding from needle prick site sinus, aneurysmorrhaphies were performed. Two wound site hematomas were evacuated. Two patients presented with severe limb swelling due to central venous occlusion for whom a veno venous cross over bypass was done with good results. In 1 patient with steal syndrome, RUDI was done with acceptable results. **Conclusion:** Failing arteriovenous fistula can be salvaged by a variety of techniques provided that it is picked up in time.

Keywords: Arteriovenous fistula; Arteriovenous graft; Fistula salvage

Citation: Ali K, Latif H, Khan NI, Butt HKP, Khan RA, Haider F. Dying arteriovenous fistulas - all is not lost yet! J Ayub Med Coll Abbottabad 2019;31(2):162-7.

INTRODUCTION

A patient who develops acute or chronic renal failure requires renal replacement therapy. This includes renal transplant, peritoneal dialysis and haemodialysis (HD). A vascular access (VA) is mandatory for HD which can be achieved with central venous catheter (tunnelled or non-tunnelled), arteriovenous fistula (AVF) and arteriovenous grafts (AVG). An AVF is created by anastomosing the patient autogenous vein and artery to let the vein arterialized and then subsequently used for HD. In patients whose native veins are not suitable for AVF, a prosthetic graft can be used in place of vein. The graft is bridged between artery and vein and is readily available for HD.¹

A good functioning VA is necessary for successful HD. An ideal VA is the one which is resistant to infection, have minimal chances of thrombosis, have a blood flow of at least 300 ml/min and is superficial enough to allow easily cannulation with two needles. The primary option for VA is an autogenous AVF, secondary is AVG and tertiary is central venous

catheters. The reason being lesser infections and morbidity associated with autogenous AVF. In order of priority an autogenous AVF can be a radio cephalic, brachiocephalic or brachio basilic (staged).^{2,3} An autogenous AVF takes at least 4-6 weeks to get matured.^{4,5} The rule of 6's may be used to assess maturation (at least 6 mm vein diameter, 600 ml/min flow, less than 6 mm vein depth).⁶

A well-functioning VA is the life line for the HD patients. Proper monitoring in the maturation phase, after cannulation and long-term surveillance is necessary for early diagnosis of any complications and their timely treatment. There are a lot of factors which can lead to failure of the AVF in the pre and post cannulation phases. In the early post-operative period, complications like bleeding, surgical site infections, wound hematomas, seromas, wound disruption, early thrombosis, technical errors, inflow issues, oedema, steal syndrome and stealing veins can place the AVF at risk for failure. With a balanced approach, by keeping the patient safety and fistula salvage in mind, these

AVFs can be rescued. In the post cannulation phase, the factors which can endanger it are; development of infected pseudoaneurysms, true aneurysms, reverse stealing veins or central vein occlusion causing venous hypertension, bleeding from needle prick site, congestive heart failure, compression neuropathies, stenosis, thrombosis and steal syndrome. By adhering to strict surveillance, these late complications can be picked up early and the AVF saved from failing.⁷⁻⁹

The aim of this study was to see the efficacy of the various surgical procedures which we carried out at our institution for rescuing failing AVFs.

MATERIAL AND METHODS

This prospective observational study was carried out from 1st August 2017 to 31st December 2018 at the department of Vascular Surgery, Combined Military Hospital Rawalpindi. Approval was taken from the hospital ethical review board. Written informed consent was taken from all the patients. All those surgical procedures were included which were done for VA salvage under local anaesthesia (LA) in the following conditions. The AVF which failed to mature after 8 weeks of creation due to stealing veins, which developed complications like thrombosis, wound hematoma and pseudo aneurysm endangering the fistula, early steal syndrome needing to ligate/ revise the fistula, draining veins aneurysms or stenosis and venous hypertension secondary to reverse stealing veins or central vein occlusion not amenable to venoplasty. The patients whose AVFs were ligated in the first instance due to any of the mentioned complications were excluded from the study. The various surgical procedures carried out like stealing vein ligation, hematoma evacuation, vein/graft thrombectomies, redo-anastomosis, pseudo aneurysm excision, aneurysmorrhaphies, excision of stenotic segment and redirecting the draining veins, procedures for AVF associated distal ischemia and central veno venous bypasses for central vein occlusion were noted down and their efficacy assessed. The results so collected are presented here.

RESULTS

A total of 62 patients were included in this study. Among them 30 were male and 32 were females. The age range was 14–75 with a mean of 50 years. Stealing vein ligation was the commonest procedure performed in this series. A total of 21 stealing veins were ligated. Among them, 15 were for fistula maturation (10 cases of radiocephalic and 5 cases of brachiocephalic AVF) and 6 for venous hypertension. All these veins were identified by performing a preoperative venous mapping and were then ligated with small incision under LA. These patients were followed up at 2 and 4 weeks with ultrasound venous mapping. The size of the draining

vein improved with arm exercises and attained the required size at 4 weeks in 12 out of the 15 stealing veins ligated for fistula maturation (80%). The remaining 3 AVFs failed to mature due to inflow issues. In case of reverse vein ligation for venous hypertension all the 6 patients showed reduction in their limb swelling in 2 weeks (100%)

9 VA thrombectomies were performed in this series, 4 for AVG and 5 for autogenous AVF thrombosis. 7 among them were successful (78%). All the four patients of AVG thrombosis presented within 3 days of the blockage. Thrombectomies were performed under LA using Fogarty's catheter which were successful. Among the 5 thrombectomies of native AVF thrombosis, 3 were done within 24 hours of AVF formation and the patency restored while 2 patients presented 4 days after the onset of thrombosis in an AVF already being used for HD in which case the procedure was not successful.

Nine patients presented with stenosis either at the anastomotic site or somewhere along the draining vein. Four were after radio cephalic and 5 after brachiocephalic AVF. In 3 patients with stenosis at or near the anastomotic site, the vein distal to the stenosis was disconnected and a new AVF formed with the artery (radial or brachial) just proximal to the previous anastomosis. In 2 patients the stenotic segment was excised, the vein mobilized and end to end anastomosis was done. In 1 patient an interposing vein graft taken from the nearby vein was used after resecting the stenotic segment. In 3 patients, with stenosis of the draining cephalic vein at mid-level, the basilic vein was mobilized from the medial side, tunnelled subcutaneously and anastomosed just proximal to the stenotic segment (patent segment toward the anastomosis) of the vein. All the patients had patent AVF with good flow on follow up (100%).

8 patients presented with non-infected pseudoaneurysm (1 AVG and 7 AVF related). They were explored, hematoma evacuated after taking proximal and distal controls, wound washed and the rent in vein/AVG/anastomotic site identified. Resection of the segment containing rent and end to end anastomosis was done in 1 case of AVG and 2 cases of AVF. Debridement of the segment and aneurysmorrhaphies was done in 2 cases of AVF. Revision of the anastomosis was done in 3 cases of anastomotic related leaks. Seven out of 8 (87.5%) cases had good patency on follow up while 1 case of anastomotic revision thrombosed and was offered a new AVF.

Seven patients presented with true aneurysm of the draining veins. Aneurysmorrhaphies were performed under LA and the size of the veins was reduced to their half. Three patients presented with bleeding from needle prick sites. A sinus plugged by a small clot was found due to repeated cannulation at one

site (buttonhole technique). This was debrided after taking controls and aneurysmorrhaphy done. 2 patients presented with wound site hematoma within 2 weeks of AVF formation. The wounds were explored, hematoma evacuated, wound washed and closed. AVFs were functional in all these cases.

Two patients presented with severe swelling of their limbs due to venous hypertension secondary to central venous occlusion. Subclavian vein angioplasties were attempted but not successful. A veno venous cross over

bypass from ipsilateral to the contralateral subclavian vein was done using reinforced PTFE graft, tunneled subcutaneously in necklace fashion. At 2 weeks follow up their swelling reduced to half and their AVFs also remained functional. One patient presented with grade 3 steal syndrome (rest pain) after brachiocephalic AVF. We performed RUDI (revision using distal inflow) procedure on him. His early follow up showed resolution of ischemic symptoms with functioning AVF. The compiled results are shown in table-1.

Table-1: Procedures performed for failing VAs

Reason of Failing Vascular Access	Rescued By	No	Efficacy
Stealing veins (non-maturing AVFs)	Stealing vein ligation	15	80%
Reverse stealing vein causing venous hypertension	Stealing vein ligation	6	100%
Thrombosis of the draining vein/AVG	Thrombectomy	9	78%
Stenosis at anastomosis/draining vein	Revision of AVF	9	100%
Non-infected pseudoaneurysm	Resection & anastomosis: 3 Aneurysmorrhaphy: 2 Revision of AVF: 3	8	87.5%
True aneurysm of the draining vein	Aneurysmorrhaphy	7	100%
Needle site puncture bleed/sinus	Aneurysmorrhaphy	3	100%
Wound hematoma	Evacuation	2	100%
Extremity swelling/ venous hypertension secondary to central vein occlusion	Veno-venous bypass	2	100%
Steal syndrome	Revision using distal inflow (RUDI)	1	100%

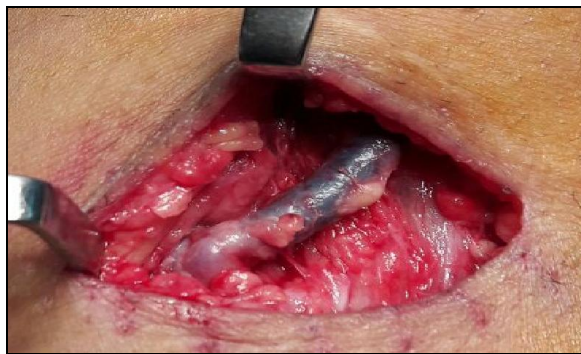

Figure-1: AVF vein thrombosis managed by thrombectomy

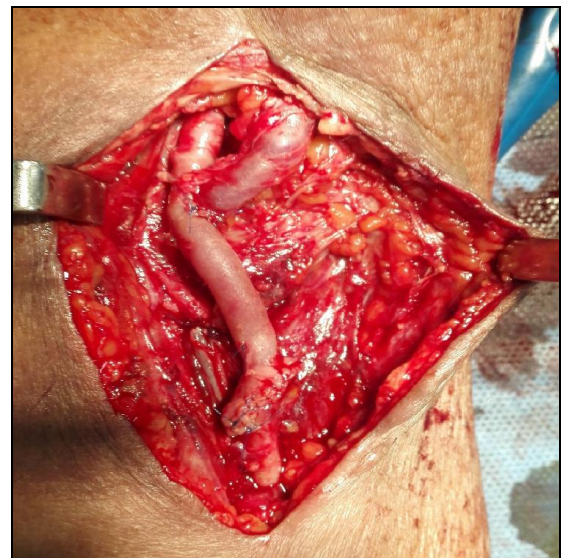


Figure-3: Case in fig 2 managed by excision of pseudoaneurysm and refashioning the AVF proximally

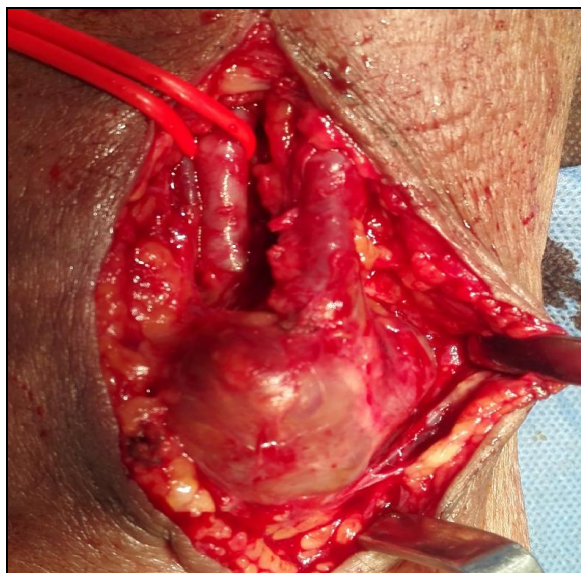


Figure-2: Anastomotic related pseudoaneurysm

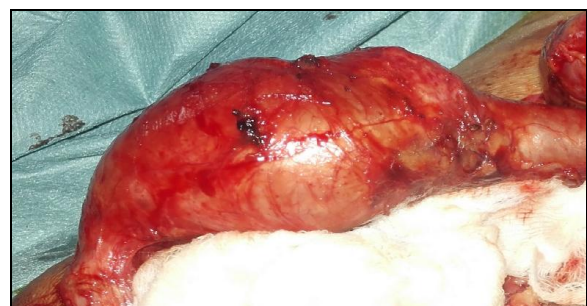

Figure-4: True aneurysm of the draining AVF vein

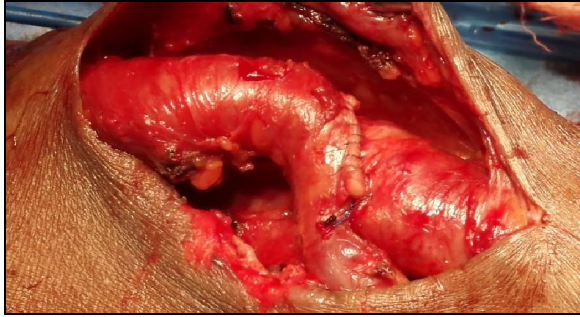


Figure-5: Case in figure 4 managed by aneurysmorrhaphy

DISCUSSION

Patients undergoing regular haemodialysis are dependent upon a well-functioning vascular access. Any complication associated with the VA can be a potential threat to its function and if not treated in time, can ultimately lead to its failure. A failed AVF is a great source of agony and depression for these patients as they are well aware of the long waiting time in order to have another mature AVF. Keeping in view these facts, it is very necessary to keep a close surveillance of AVFs in order to prolong their life. This process of care and close observation should start soon after the fistula is created. The patient should be given instruction about care of the AVF, exercise program, early warning signs like bleeding, infection, significant swelling, loss of thrill and distal ischemia. The patient should self-examine the fistula for thrill and should immediately report back to the hospital in case the thrill disappears or any of the warning sign appears. This can help in the early rescue of an endangered AVF.¹⁰

After creation the fistula usually take 4-6 weeks to mature. A mature fistula is one which is suitable for cannulation with minimal complications, and can deliver the required blood flow throughout the HD. Maturity of AVF can be assessed by physical examination and imaging. Many AVFs fail to mature ranging from 10% in brachiocephalic up to 33% in radiocephalic AVF. The most common causes of non-maturation are stenosis at arterial, anastomotic or venous side, small calibre vessels and large competing/stealing veins. These can be identified on duplex imaging. Up to 80% of non-maturing AVFs can be salvaged after secondary procedures like large stealing vein ligation and correction of stenosis.^{11,12} We also found this effective in our series. We ligated 21 stealing veins (15 for non-maturing AVFs and 6 for venous hypertension). The efficacy of stealing vein ligation in non-maturing AVF was 80% in our case which is comparable with the international reported literature. The role of exercise in maturation cannot be ignored.¹³ We also found it effective after

stealing vein ligation in helping our AVF to get matured.

Stenosis at the draining vein, anastomosis or arterial inflow can be another reason of a failing AVF. They can either present with non-maturing AVF or in the post cannulation period with reduced AVF flow, prolonged bleeding time and increased venous pressures with ipsilateral limb swelling. Subclavian vein stenosis may be due to thrombosis/narrowing due to previous double lumen catheter placement. They all can respond well to angioplasty and open surgical revision.^{14,15}

In our series we had 9 patients with stenotic lesions in the arm veins while 2 patients had central vein occlusion. We did a variety of procedures for the salvage of these AVFs. For anastomotic stenosis we made a proximal new AVF using the same already matured vein. For stenosis along the draining vein in the arm we resected the stenosed segment and either did end to end anastomosis or interposing venous grafting. In a few cases we mobilized the basilic vein from the medial side and incorporated it into the draining vein just below the stenotic segment of the cephalic vein, thus redirecting the flow from the stenotic part towards the basilic vein. In 2 cases where the central vein occlusion was not responding to angioplasty and the patient had severe limb swelling secondary to venous hypertension, we did veno venous bypass from ipsilateral axillary vein to contra lateral axillary vein using ringed PTFE graft in necklace fashion. The purpose was to relieve the venous hypertension and salvage the AVF both at the same time. The efficacy of all these revision procedures was 100 % in our study. All of these AVFs improved and was subsequently used for HD. The studies of Chen JC. *et al*¹⁶, Kian K & Asif A. *et al*¹⁷, Kian K & Unger SW. *et al*¹⁸ and Wang S. *et al*¹⁹ also concluded that these revision procedures for such stenotic lesions are effective in fistula salvage.

Aneurysms associated with AVF may be true where they have all the layers of the vessel or false where there is a rent in the wall. False aneurysm needs intervention to evacuate the hematoma and repair the rent otherwise infection can lead to destruction of the AVF.

True aneurysm can be observed and selectively intervened. Resizing of the vein with aneurysmorrhaphy can be effective in these cases.⁷ The procedures which we did in non-infected pseudoaneurysm were resection of the rent containing segment and re end to end anastomosis of the vein/graft, revising the AVF to a proximal location in anastomotic related pseudoaneurysm and aneurysmorrhaphy for small rents. For true aneurysm and needle site sinus we did aneurysmorrhaphy. These procedures had good outcome in terms of

fistula salvage in our series. Same results were also shown by Georgiadis GS *et al*²⁰ in their study. Patient on HD have an increased bleeding tendency due to defective coagulation. They can present with early post-operative bleeding which may need re exploration. They may present with wound hematomas in which case the bleeding has stopped but there is blood collection. Clinically significant hematomas need evacuation to decrease the risk of infection and skin necrosis which ultimately jeopardize the AVF.²¹ We had 2 patients with post-operative wound hematoma which were re explored and hematoma evacuated. The AVF in both the cases was functional.

Thrombosis in an AVF/AVG is a known complication. It may be early, which is defined as thrombosis occurring within 30 days of AVF creation or it may be delayed, in which case thrombosis occurs in an AVF already being used for HD. The reasons for this may be technical errors, an episode of transient hypotension or any underlying stenosis. Treatment within 7 days can have good results in fistula salvage. Beyond this time, the thrombus become adherent to the wall and propagates, making its removal difficult. Fogarty balloon thrombectomy or endovascular means like pharmacological or mechanical thrombolysis or a combination of these can be used.²² We did 9 thrombectomies; 4 for AVG and 5 for AVF. Seven patients were with early onset thrombosis (less than 7 day of creation of AVF) and the patency was restored in all of them successfully. Two patients presented 4 days after onset of thrombosis in an AVF already being used for HD. Their patency could not be restored by thrombectomies. Overall efficacy was 78%. Tordoir *et al*²³ and Green LD *et al*²⁴ showed in their results that thrombectomy is a valuable option in cases of AVF/AVG thrombosis.

Access steal syndrome or AVF induced limb Ischaemia is a condition that occurs because of decreased blood flow to the limb distal to the AVF. It occurs in 5–10% of brachiocephalic and in less than 1% of radio cephalic AVFs. Predisposing factors are increase in age, diabetes, peripheral vascular disease, inflow stenosis and proximal AVFs. It has four clinical stages. In stage I there is pale and cold hand without pain, in stage II, there is pain in the hand on exercise and during HD. In stage III there is rest pain while in stage IV there is ulceration and gangrene. Urgent treatment is necessary in stage III and IV to avoid limb loss. The simplest treatment is to ligate the AVF but if one wants to save the AVF and treat the steal both at the same time then the options are; narrowing the outflow vein, DRIL (distal revascularization interval ligation) and RUDI (revision using distal inflow) procedures²⁵ We had

one patient with stage III steal syndrome post brachiocephalic AVF. We performed RUDI procedure for him. In this approach the AVF vein is detached from its original position on the brachial artery and extended onto the radial artery 2–3 cm from its origin using a vein graft. This permits the hand perfusion through the ulnar artery and the AVF is also salvaged at the same time. Loh TM²⁶ in his study suggested that RUDI is an effective procedure for access steal syndrome.

CONCLUSION

AVF related complications are important in the sense that if they are ignored, they can ultimately lead to a failed vascular access. Every complication related to an AVF does not always require ligation of the access. The vascular surgeon toolbox has many remedial strategies for them which at the same time save the AVF and treat the complication as well.

AUTHORS' CONTRIBUTION

KA: Concept, data collection, write-up. HL: Analysis. NI: Supervision. HKP: Interpretation. RAK: Proof reading. FH: Study design.

REFERENCES

- Schmidli J, Widmer MK, Basile C, de Donato G, Gallieni M, Gibbons CP. *et al*. Editor's Choice - Vascular Access: 2018 Clinical Practice Guidelines of the European Society for Vascular Surgery (ESVS). *Eur J Vasc Endovasc Surg* 2018;55(6):757–818.
- Almasri J, Alsawas M, Mainou M, Mustafa RA, Wang Z, Woo K, *et al*. Outcomes of vascular access for hemodialysis: A systematic review and meta-analysis. *J Vasc Surg* 2016;64(1):236–43.
- Al-Jaishi AA, Liu AR, Lok CE, Zhang JC, Moist LM. Complications of the arteriovenous fistula: a systematic review. *J Am Soc Nephrol* 2017;28(6):1839–50.
- Ives CL, Akoh JA, George J, Vaughan-Huxley E, Lawson H. Preoperative vessel mapping and early post-operative surveillance duplex scanning of arteriovenous fistulae. *J Vasc Access* 2009;10(1):37–42.
- Jemcov TK. Morphologic and functional vessels characteristics assessed by ultrasonography for prediction of radiocephalic fistula maturation. *J Vasc Access* 2013;14(4):356–63.
- Vascular Access 2006 Work Group. Clinical practice guidelines for vascular access. *Am J Kidney Dis* 2006;48:S176–247.
- Kumbar L. Complications of arteriovenous fistulae: beyond venous stenosis. *Adv Chronic Kidney Dis* 2012;19(3):195–201.
- Gulati S, Sahu KM, Avula S, Sharma RK, Ayyagiri A, Pandey CM. Role of vascular access as a risk factor for infections in hemodialysis. *Ren Fail* 2003;25(6):967–73.
- Li PK, Chow KM. Infectious complications in dialysis-epidemiology and outcomes. *Nat Rev Nephrol* 2012;8(2):77–88.
- Fontsero N, Mestres G, Yugueros X, Lopez T, Yuguero A, Bermudez P, *et al*. Effect of a postoperative exercise program on arteriovenous fistula maturation: A randomized controlled trial. *Hemodial Int* 2016;20(2):306–14.
- Malovrh M. Non-matured arteriovenous fistulae for haemodialysis: diagnosis, endovascular and surgical treatment. *Bosn J Basic Med Sci* 2010;10(Suppl 1):S13–7.

12. Singh P, Robbin ML, Lockhart ME, Allon M. Clinically immature arteriovenous hemodialysis fistulas: effect of US on salvage. *Radiology* 2008;246(1):299–305.
13. Oder TF, Teodorescu V, Uribarri J. Effect of exercise on the diameter of arteriovenous fistulae in hemodialysis patients. *ASAIO J* 2003;49(5):554–5.
14. Ravani P, Quinn RR, Oliver MJ, Karsanji DJ, James MT, MacRae JM, *et al.* Pre-emptive correction for haemodialysis arteriovenous access stenosis. *Cochrane Database Syst Rev* 2016;1:CD010709.
15. Jimenez-Almonacid P, Gruss-Vergara E, Jimenez-Toscano M, Lasala M, Rueda JA, Portoles J, *et al.* Surgical treatment of juxtaanastomotic stenosis in radiocephalic fistula. A new proximal radiocephalic anastomosis. *Nefrologia* 2012;32(4):517–22.
16. Chen JC, Kamal DM, Jastrzebski J, Taylor DC. Venovenostomy for outflow venous obstruction in patients with upper extremity autogenous hemodialysis arteriovenous access. *Ann Vasc Surg* 2005;19(5):629–35.
17. Kian K, Asif A. Cephalic arch stenosis. *Semin Dial* 2008;21(1):78–82.
18. Kian K, Unger SW, Mishler R, Schon D, Lenz O, Asif A. Role of surgical intervention for cephalic arch stenosis in the “fistula first” era. *Semin Dial* 2008;21(1):93–6.
19. Wang S, Almeghi A, Asif A. Surgical management of cephalic arch occlusive lesions: are there predictors for outcomes? *Semin Dial* 2013;26(4):E33–41.
20. Georgiadis GS, Lazarides MK, Panagoutsos SA, Kantartzi KM, Lambidis CD, Stamos DN, *et al.* Surgical revision of complicated false and true vascular access-related aneurysms. *J Vasc Surg* 2008;47(6):1284–91.
21. Padberg FT Jr, Calligaro KD, Sidawy AN. Complications of arteriovenous hemodialysis access: recognition and management. *J Vasc Surg* 2008;48(5 Suppl):S55–80.
22. Sidawy AN, Gray R, Besarab A, Henry M, Ascher E, Silva M Jr, *et al.* Recommended standards for reports dealing with arteriovenous hemodialysis accesses. *J Vasc Surg* 2002;35(3):603–10.
23. Tordoir JH, Bode AS, Peppelenbosch N, van der Sande FM, de Haan MW. Surgical or endovascular repair of thrombosed dialysis vascular access: is there any evidence? *J Vasc Surg* 2009;50(4):953–6.
24. Green LD, Lee DS, Kucey DS. A metaanalysis comparing surgical thrombectomy, mechanical thrombectomy, and pharmacomechanical thrombolysis for thrombosed dialysis grafts. *J Vasc Surg* 2002;36(5):939–45.
25. Malik J, Tuka V, Kasalova Z, Chytilova E, Slavikova M, Clagett P, *et al.* Understanding the dialysis access steal syndrome. A review of the etiologies, diagnosis, prevention and treatment strategies. *J Vasc Access* 2008;9(3):155–66.
26. Loh TM, Bennett ME, Peden EK. Revision using distal inflow is a safe and effective treatment for ischemic steal syndrome and pathologic high flow after access creation. *J Vasc Surg* 2016;63(2):441–4.

Submitted: 27 January, 2019

Revised: 6 February, 2019

Accepted: 13 February, 2019

Address for Correspondence:

Dr. Kishwar Ali, Senior Registrar Vascular Surgery, Combined Military Hospital, Rawalpindi-Pakistan

Cell: +92 333 9474480

Email: drkaish1@gmail.com