

CASE REPORT

LUPUS VASCULITIS

Nauman Ismat Butt, Fahmina Ashfaq, Khalid Mahmood, Sabeen Aftab, Ali Anwar, Minhal Saeed

Department of Medicine & Allied, Azra Naheed Medical College, Superior University Lahore-Pakistan

We present the case of a 30-year-old woman who presented with 8-month history of intermittent fever, joint pains with morning stiffness, recurrent oral ulcers, photosensitivity, weight loss and hair fall. For the last 2 months, she had developed a dry cough with progressive shortening of breath. On examination, a cachexic lady with malar hyperpigmentation, alopecia, pallor, nail dystrophy and erythema over her hands and feet were noted. There were multiple punched-out skin ulcers of variable size over legs, arms and abdomen usually round in shape with well-defined even wound margins and scant serous discharge. Musculoskeletal examination revealed synovitis of both elbows and a few metacarpophalangeal and proximal interphalangeal joints. Chest X-ray and HRCT showed bilateral ground-glass opacification. Anti-Nuclear Antibody (ANA) was positive, 1:320, homogenous nuclear pattern. Anti-Ro antibody was highly positive and serum complement (C3, C4) levels were reduced. She was diagnosed with Lupus Vasculitis and started on steroids, mycophenolate mofetil and hydroxychloroquine.

Keywords: Systemic Lupus Erythematosus; ANA; Cutaneous Vasculitis; Pulmonary Vasculitis

Citation: Butt NI, Ashfaq F, Mahmood K, Aftab S, Anwar A, Saeed M. Lupus Vasculitis. J Ayub Med Coll Abbottabad 2023;35(3):475-8.

DOI: 10.55519/JAMC-03-10849

INTRODUCTION

Lupus Vasculitis, a poorly understood secondary Vasculitis associated with poor prognosis, affects up to 50% of patients with active Systemic Lupus Erythematosus (SLE).¹ The clinical presentation varies from mild illness to severe multi-system involvement with life-threatening conditions like mesenteric ischemia and pulmonary alveolar haemorrhage. Approximately 90% patients of with Lupus Vasculitis involve the skin.² Pulmonary, renal, gastrointestinal, neurological and cardiac involvement is less frequently seen.² Treatment is dependent on the severity of vasculitis and the systems involved requiring a prompt diagnosis to contain the severe and life-threatening complications. European Alliance of Associations for Rheumatology (EULAR) treatment recommendations are employed clinically although management may be tailored according to severity and systems involved.³ Mild to moderate disease is treated by oral steroids and immunosuppressive therapy like methotrexate and azathioprine. However aggressive disease may require potent therapy with intravenous steroids, mycophenolate mofetil, cyclophosphamide, rituximab, intravenous immunoglobulin and plasmapheresis.³

CASE REPORT

We present the case of a 30-year-old woman who presented with 8-month history of low-grade intermittent fever having no specific aggravating or relieving factors. Along with this she had bilateral symmetrical joint pains with swelling and morning stiffness lasting more than 60 minutes that started

from the small joints of the hands but then progressed to involve wrists, elbows, knees and foot joints. She had seen local doctors for this numerous times, work up for infections was normal and an ANA negative initially. She had been prescribed multiple courses of antibiotics and analgesics without relief. She also had a history of recurrent oral ulcers, photosensitivity, marked hair fall, generalized weakness with fatigue and lethargy, weight loss of 10 kgs and reddish-purple painless mottling of skin over all four limbs. For the last 2 months, she developed a dry cough with shortening of breath that gradually worsened to the extent that she became bedbound and eventually had dyspnoea at rest also. There was also a history of multiple painful skin ulcers over the legs, arms and abdomen for the last 2 months. She was married with 5 children and had a history of 1 abortion at 8 weeks of gestation. She did not smoke or use illicit drugs. On examination, a cachexic lady, conscious and oriented, with normal vitals and O₂ 98% on room air with malar hyperpigmentation, alopecia, pallor, nail dystrophy and erythema over hands and feet was noted. In the oral cavity, a white coated tongue and multiple oral ulcers were seen. There were multiple punched-out skin ulcers of variable size over legs, arms and abdomen usually round in shape with well-defined even wound margins and scant serous discharge. There was no calcinosis, digital ulcers or evidence of Raynaud's phenomena. Musculoskeletal examination revealed synovitis of both elbows and few metacarpophalangeal and proximal interphalangeal joints.

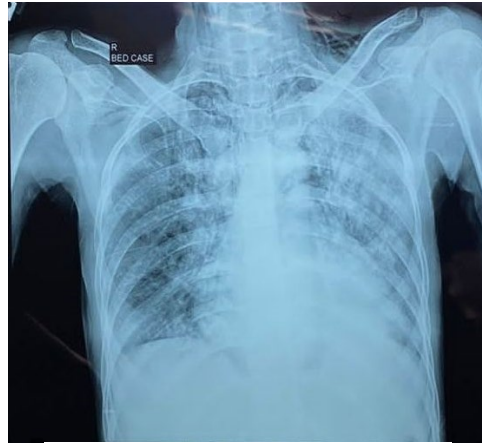


Figure-1: Chest X-ray on admission

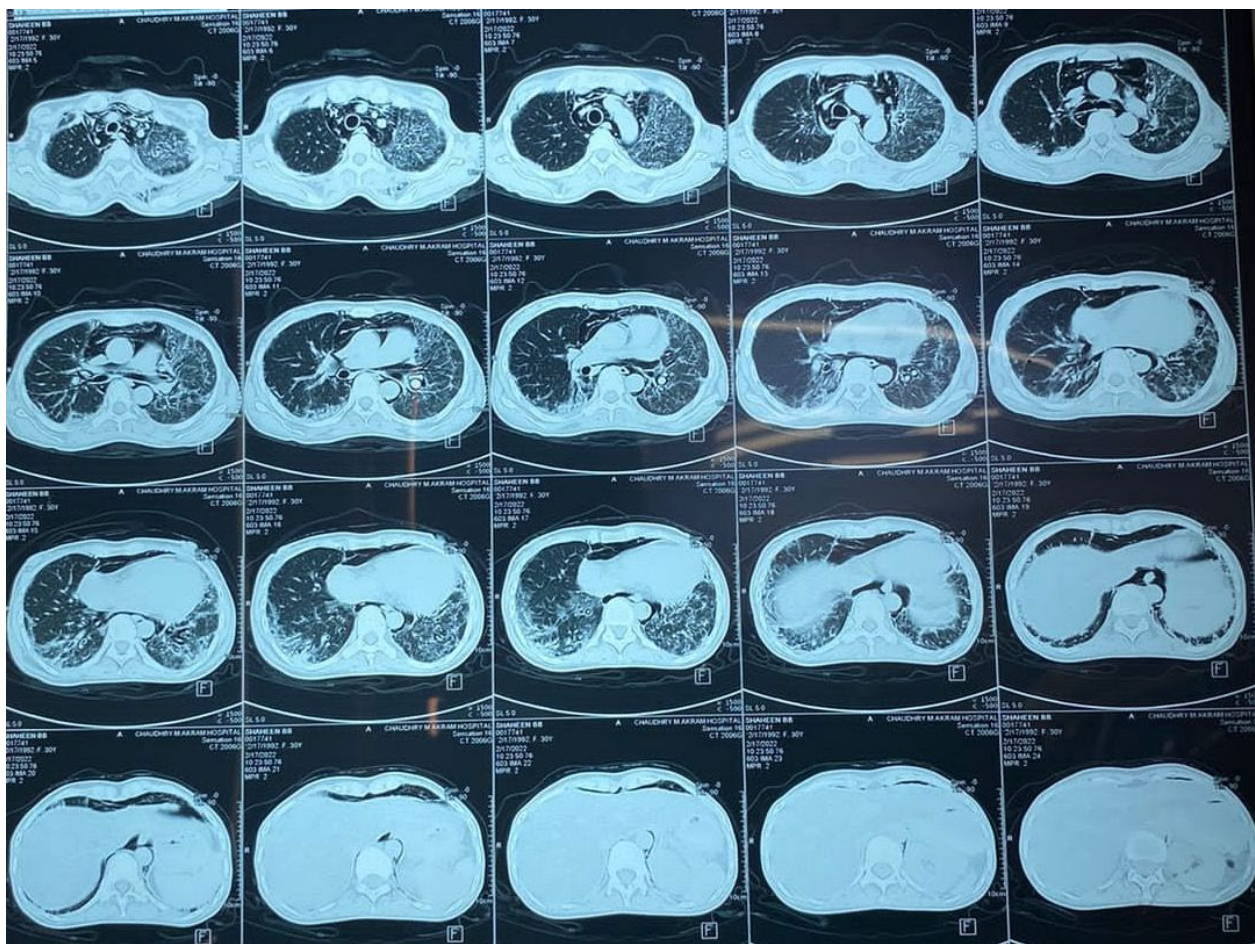


Figure-2: HRCT Chest on admission

Chest X-ray on presentation is shown in figure-1 and a subsequent HRCT chest was done demonstrating bilateral ground-glass opacification more on the left side, subpleural reticulations, patchy cylindrical bronchiectasis and pneumomediastinum as shown in figure-2. On investigation, she had microcytic anaemia with normal TLC and platelet counts with

markedly raised ESR and CRP but normal procalcitonin levels. Low serum albumin was noted however urine analysis was normal with normal RFTs and LFTs. An autoimmune profile was done to show ANA positive, 1:320, homogenous nuclear pattern. Anti-Ro antibody was highly positive and serum complement (C3, C4) levels were reduced. RA

Factor, Anti-CCP, Anti-DsDNA, Anti-phospholipid, Anti-Smith and Anti-RNP antibodies were negative with normal serum CPK and aldolase. An otherwise normal echocardiography revealed a mean PASP of 35 mmHg indicating mild pulmonary hypertension. She was diagnosed with Lupus Vasculitis and started on intravenous methylprednisolone pulse for 5 days followed by oral prednisolone 1mg/kg body weight was prescribed with slow tapering and mycophenolate mofetil with a target of 3 gm/day for Pulmonary Vasculitis. Chest X-ray on discharge is shown in figure-3. Additionally, she was prescribed hydroxychloroquine 5 mg/kg body weight for Cutaneous Vasculitis, sunblock SPF 60, calcium and vitamin D supplements along with anti-fungal for oral candidiasis.

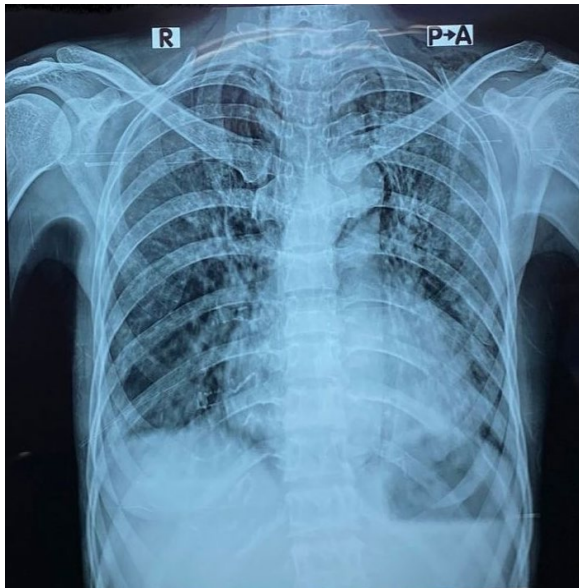


Figure-3: Chest X-ray at time of discharge

DISCUSSION

Cutaneous vasculitis is the most frequent type of vasculitis among patients with SLE in up to 90% of the cases of vasculitis in this disease.¹ Cutaneous Vasculitis is heterogeneous and can present as palpable purpura, papulonodular lesions, petechiae, urticaria, livedo reticularis, bullous lesions, skin infarct, necrotic erythemas, panniculitis, splinter haemorrhages and vasculitic arterial ulcers.⁴ Risk factors associated with the development of Cutaneous Vasculitis in SLE include anaemia, leucopenia, myositis, presence of cryoglobulins, high levels of anti-Ro, anti-phospholipid, anti-Smith and anti-RNP antibodies.^{5,6} First-line treatment for cutaneous vasculitis is hydroxychloroquine which is usually tolerated well but its potential ocular toxicity is recognized thus regular monitoring with Optical

Coherence Tomography is recommended.⁷ Other options include colchicine, thalidomide and dapsone.^{8,9} A short course of oral steroids may be used in painful, ulcerative diseases to fasten ulcer healing and resolution.¹⁰ In refractory cases, azathioprine may be used.¹¹ For severe resistant cases, intravenous Immunoglobulins (IVIG) and rituximab have been used.¹² Yang *et al.*¹³ treated a case of Cutaneous Vasculitis with oral prednisolone and cyclophosphamide with a good response to therapy. However, Stumpf *et al.*¹⁴ reported a case of refractory Cutaneous lupus Vasculitis who was treated with prednisolone, hydroxychloroquine and IVIG but still could not survive. Our patient had painful vasculitic ulcers and erythema of hands and feet suggestive of Cutaneous vasculitis. Of the risk factors mentioned, our patient had anaemia and a high titer Anti-Ro antibody. Her painful ulcerative cutaneous vasculitis responded well to treatment with hydroxychloroquine and steroids.

Pulmonary Vasculitis in SLE generally presents as diffuse alveolar haemorrhage and carries a mortality of approximately 35%.¹⁵ Clinical features include cough, progressive shortness of breath, chest pain, fever and in up to 60% of cases hemoptysis.¹⁵ Described on imaging as classical bilateral alveolar interstitial infiltrates, the diagnosis of pulmonary Vasculitis is based on chest radiography, bronchoscopy and bronchoalveolar lavage. In pulmonary vasculitis, high-dose intravenous methylprednisolone along with cyclophosphamide or mycophenolate remain first-line therapies.¹⁶ Intravenous Immunoglobulins (IVIG), plasmapheresis and rituximab are beneficial in refractory cases.^{15,17} Our patient did not consent to bronchoscopy and thus bronchoalveolar lavage could not be done to rule out alveolar haemorrhage. However, the rapid response to steroid therapy suggests superimposed alveolar haemorrhage on the background of interstitial lung disease in our patient. Gamal *et al.*¹⁸ reported Vasculitis in 33.4% of 565 SLE patients enrolled in Egypt; with 59.2% of patients with Vasculitis having Cutaneous involvement while 3.1% had pulmonary vasculitis. Risk factors for the development of Vasculitis in SLE were reported as juvenile-onset and the presence of livedo reticularis, Raynaud's phenomena and haematological manifestations along with high disease activity at the time of SLE diagnosis.¹⁸ The patients with vasculitis had a higher mortality rate as compared to SLE patients without Vasculitis (12% Vs 3.7%).¹⁸

In conclusion, Lupus Vasculitis has a variable clinical presentation with a poor prognosis thus necessitating the requirement for timely diagnosis and early treatment depending on the

severity of vasculitis and systems involved to limit the disease burden and improve mortality. Our patient with pulmonary and cutaneous vasculitis was managed with steroids, mycophenolate mofetil and hydroxychloroquine.

Consent: Informed consent was taken from the patient.

Conflict of Interest: None declared.

REFERENCES

1. Leone P, Prete M, Malerba E, Bray A, Susca N, Ingravallo G, *et al.* Lupus Vasculitis: An Overview. *Biomedicines* 2021;9(11):1626.
2. Ramos-Casals M, Nardi N, Lagrutta M, Brito-Zeron P, Bove A, Delgado G, *et al.* Vasculitis in systemic lupus erythematosus: Prevalence and clinical characteristics in 670 patients. *Medicine (Baltimore)* 2006;85(2):95–104.
3. Fessler BJ, Hoffman GS. Vasculitis. In: Lahita RG, editor. *Systemic Lupus Erythematosus*. 5th ed. Academic Press; Cambridge, MA, USA: 2011; p.833–45.
4. Drenkard C, Villa AR, Reyes E, Abello M, Alarcón-Segovia D. Vasculitis in systemic lupus erythematosus. *Lupus* 1997;6(3):235–42.
5. Kallas R, Goldman D, Petri MA. Cutaneous vasculitis in SLE. *Lupus Sci Med* 2020;7(1):e000411.
6. Sharma A, Dhoooria A, Aggarwal A, Rathi M, Chandran V. Connective Tissue Disorder-Associated Vasculitis. *Curr Rheumatol Rep* 2016;18(6):31.
7. Uthman I. Pharmacological therapy of vasculitis: an update. *Curr Opin Pharmacol* 2004;4(2):177–82.
8. Micheletti RG, Pagnoux C. Management of cutaneous vasculitis. *Presse Med* 2020;49(3):104033.
9. Wang D, Chen H, Wang S, Zou Y, Li J, Pan J, *et al.* Thalidomide treatment in cutaneous lesions of systemic lupus erythematosus: a multicenter study in China. *Clin Rheumatol* 2016;35(6):1521–7.
10. Walling HW, Sontheimer RD. Cutaneous lupus erythematosus: issues in diagnosis and treatment. *Am J Clin Dermatol* 2009;10(6):365–81.
11. Callen JP, af Ekenstam E. Cutaneous leukocytoclastic vasculitis: clinical experience in 44 patients. *South Med J* 1987;80(7):848–51.
12. Calle-Botero E, Abril A. Lupus Vasculitis. *Curr Rheumatol Rep* 2020;22(10):71.
13. Yang L, Zeng YP. Cutaneous Vasculitis in Systemic Lupus Erythematosus. *JAMA Dermatol* 2021;157(8):991.
14. Stumpf MAM, Quintino CR, Rodrigues MAVM, de Campos FPF, Maruta CW. Cutaneous vasculitis in lupus treated with IV immunoglobulin. *Clin Rheumatol* 2021;40(7):3023–4.
15. Wang CR, Liu MF, Weng CT, Lin WC, Li WT, Tsai HW. Systemic lupus erythematosus-associated diffuse alveolar haemorrhage: a single-centre experience in Han Chinese patients. *Scand J Rheumatol* 2018;47(5):392–9.
16. Al-Adhoubi NK, Bystrom J. Systemic lupus erythematosus and diffuse alveolar hemorrhage, etiology and novel treatment strategies. *Lupus* 2020;29(4):355–63.
17. Luqmani RA. State of the art in the treatment of systemic vasculitides. *Front Immunol* 2014;5:471.
18. Gamal SM, Mohamed SS, Tantawy M, Siam I, Soliman A, Niaz MH. Lupus-related vasculitis in a cohort of systemic lupus erythematosus patients. *Arch Rheumatol* 2021;36(4):595–692.

Submitted: April 2, 2022

Revised: May 19, 2022

Accepted: September 11, 2022

Address for Correspondence:

Nauman Ismat Butt, Department of Medicine and Allied, Azra Naheed Medical College, Superior University, 17-Km Main Raiwind Road Kot Araian, Lahore Pakistan

Cell: +92 345 465 1049

Email: nauman_ib@yahoo.com