

ORIGINAL ARTICLE

EFFECT OF INCISOR INCLINATION CHANGES ON
CEPHALOMETRIC POINTS A AND B

Sohaib Hassan, Attiya Shaikh, Mubassar Fida

Section of Dentistry, Department of Surgery, Aga Khan University Hospital, Karachi-Pakistan

Background: The position of cephalometric points A and B are liable to be affected by alveolar remodelling caused by orthodontic tooth movement during incisor retraction. This study was conducted to evaluate the change in positions of cephalometric points A and B in sagittal and vertical dimensions due to change in incisor inclinations. **Methods:** Total sample of 31 subjects were recruited into the study. The inclusion criteria were extraction of premolars in upper and lower arches, completion of growth and orthodontic treatment. The exclusion criteria were patients with craniofacial anomalies and history of orthodontic treatment. By superimposition of pre and post treatment tracings, various linear and angular parameters were measured. Various tests and multiple linear regression analysis were performed to determine changes in outcome variables. Statistically significant p -value was ≤ 0.05 . **Results:** One-sample t -test showed that change in position of only point A was statistically significant which was 1.61mm ($p < 0.01$) in sagittal direction and 1.49mm ($p < 0.01$) in vertical direction. Multiple linear regression analysis showed that if we retrocline upper incisor by 10° , the point A will move superiorly by 0.6mm. **Conclusions:** Total change in the position of point A is in a downward and forward direction. Total Change in upper incisors inclinations causes change in position of point A only in vertical direction.

Keywords: Incisor inclination, Point A, Point B, cephalometric

J Ayub Med Coll Abbottabad 2015;27(2):268-73

INTRODUCTION

Points A and B are commonly used to scrutinize the sagittal relationship of maxilla and mandible during formulation of precise diagnosis. These points also facilitate us to inspect the true efficacy of various treatment protocols on skeletal jaw bases in sagittal direction.¹ Many linear parameters have been suggested to evaluate the anteroposterior (AP) relationship of jaws: (1) the distance between perpendiculars drawn from the sella-nasion line to points A and B², (2) the distance between perpendiculars drawn from the occlusal plane to points A and B (Wits appraisal)³, (3) the AP dysplasia indicator⁴, (4) the distance between nasion perpendiculars drawn from the Frankfort plane to points A and B⁵, (5) the distance between perpendiculars drawn from the palatal plane to points A and B⁶, (6) the distance between perpendiculars drawn from the bisector of the maxillo-mandibular plane angle to points A and B.⁷

Nevertheless, these measurements still use points A and B as reference points for the AP position of maxilla and mandible, respectively. The positions of cephalometric points A and B are liable to be affected by growth as well as dentoalveolar remodelling caused by orthodontic treatment.^{1,8-10} Erverdi¹⁰ testified borderline significant correlation between axial inclination of maxillary incisors and the position of point A but did not state the p -value. The simple linear regression analysis, used in the study, proposed that there is 0.16mm of change in the

position of point A in posterior direction when the tooth is proclined by 1° . However, statistical method of analysis did not account for growth. Furthermore, to rule out measurement errors, no repeatability analysis was performed.

Al-Abdwani¹¹ stated that each 10° retroclination of maxillary incisors results in statistically significant advancement of point A of 0.4 mm in horizontal plane. In addition, each 10° retroclination of mandibular incisor results in borderline statistically significant advancement of point B of 0.3 mm in horizontal plane. The study used a multiple linear regression analysis to analyse the data accounting for change in the position of points A and B due to growth and bodily tooth movement for each subject ranging from 8.8 to 39 years. However, even after the consideration of growth, the validity of study on individuals of such age variation may be questionable and this may affect the accuracy of the results. Moreover, the above mentioned studies did not consider the incisor retraction into extraction spaces.

The aim of this study is to evaluate the change in position of points A and B purely due to the incisal inclination changes because of orthodontic treatment in adult patients.

MATERIAL AND METHODS

The material employed in this cross-sectional cephalometric study comprised of 31 pairs of pre and post treatment lateral cephalographs of non-syndromic patients (3 males and 28 females) who had finalized

their orthodontic treatment. All radiographs had been taken as a part of the standard clinical procedure for diagnosis and treatment planning. These radiographs were procured on the same cephalostat and they were of sufficient quality to allow recognition of relevant landmarks on their tracings.

The inclusion criteria for the subjects to be recruited in the study were extraction of premolars in upper and lower arches and adult patients of Pakistani origin. The exclusion criteria of the study were patients having history of orthodontic treatment. The x-ray films were selected from orthodontic department system fulfilling the above mentioned inclusion criteria and were traced over an illuminator manually by the principal investigator. All the landmarks were identified based on the definitions by Riolo *et al*¹² except gonion¹³ (Table-1). Pre-treatment lateral cephalometric radiographs were traced with solid lines while post treatment cephalograms were traced with dashed lines. Data was taken from all the files meeting the inclusion criteria from the period 2002–2009.

The following parameters were used in this study as illustrated in figure-1:

- Upper incisor angle to Sella-Nasion plane (UI-SN^o): Angle formed the intersection of the long axis of the maxillary incisor and Sella-Nasion (SN) line
- Lower incisor angle to mandibular plane (IMPA^o): Angle formed by the intersection of the long axis of mandibular incisor with the Gonion-Menton line
- Change in UI-SN^o: Change in the UI-SN angle between pretreatment and post treatment lateral cephalographs
- Change in IMPA^o: Change in IMPA angle between pretreatment and post treatment lateral cephalographs
- A_V: Total vertical displacement covered by cephalometric point A
- A_H: Total horizontal displacement covered by cephalometric point A
- B_V: Total vertical displacement covered by cephalometric point B
- B_H: Total horizontal displacement covered by cephalometric point B

By superimposition of pre and post treatment lateral cephalographs, total change in positions of points A and B were evaluated. The negative sign was used for upward as well as for backward displacement of point A or B during data collection.

For assessment of total change in position of point A, pre and post treatment tracings were superimposed on the sella-nasion (SN) line at the sella as illustrated in Figure II. On this superimposition, a horizontal line passing through sella, 7 degrees inferior from the SN line, was drawn to form a horizontal reference plane (HRP).¹⁴ A line perpendicular to HRP passing through sella established the vertical reference plane (VRP).¹⁴

To determine the total vertical displacement of point A (A_V), two horizontal lines, perpendicular to VRP, were drawn on both tracings, passing through pre and post treatment point A, and were labelled as H₁ and H₂, respectively. The vertical distance between these two horizontal lines defined the vertical component of change in position of point A. To determine the total horizontal displacement of point A (A_H), two vertical lines, perpendicular to HRP, were drawn on both tracings, passing through pre and post treatment point A, and were labelled as V₁ and V₂, respectively. The horizontal distance between these two vertical lines determined the AP component of change in position of point A (Figure-2).

For calculation of total change in position of point B, pre and post treatment tracings were superimposed on lingual contour of the symphysis in order to control the confounder of mandibular rotation as illustrated in figure III. Similarly, HRP and VRP were sketched on a superimposition tracing.

Determine the total vertical displacement of point B (B_V), two horizontal lines, and perpendicular to VRP, were drawn on both tracings, passing through pre and post treatment point B, and were labelled as H₃ and H₄, respectively. The vertical distance between these two horizontal lines defined the vertical component of change in position of point B. To determine the total horizontal displacement of point B (B_H), two vertical lines, perpendicular to HRP, were drawn on both tracings, passing through pre and post treatment point B, and were labeled as V₃ and V₄, respectively. The horizontal distance between these two vertical lines determined the AP component of change in position of point B (Figure-3).

Means and standard deviations were computed for all the variables using Statistical Package for the Social Sciences (SPSS) for windows (version 19.0 Chicago Inc. USA). Paired sample t-test was performed to determine the total change in angular parameters during the treatment. One-sample t-test was applied to evaluate the total change in position of points A and B.

Multiple linear regression analysis was performed to assess the relationship of change in position of points A and B with the remaining variables, keeping the change in position of points A and B as dependent variables and the remaining parameters as independent variables, alternatively. *p*-value less than or equal to 0.05 was considered as statistically significant.

To rule out measurement error, 10 lateral cephalometric radiographs were retraced after 1 month by the principal investigator and Pearson correlation was applied which showed strong and positive correlations (Table-2).

RESULTS

Out of total number of 31 subjects, 28 were females and 3 were males. Mean age of patients was 17.72 ± 5.08 years. Treatment changes for angular parameter are shown in table-3 and for linear parameters are shown in table-4.

The maxillary incisor inclination change ranged from pre-treatment $111.94 \pm 5.50^\circ$ to post treatment $103.23 \pm 9.15^\circ$ ($p=0.001$). The mandibular incisor inclination change ranged from pre-treatment $102.19 \pm 7.16^\circ$ to post treatment $98.13 \pm 7.16^\circ$ ($p=0.001$). The total change in the position of point A was in a downward and forward direction. Total vertical displacement of point A was 1.49 ± 1.94 mm ($p=0.001$) and total horizontal displacement was 1.61 ± 2.20 mm ($p=0.001$). The total change in position of point B was in upward and backward direction but it was not statistically significant. Total vertical displacement of point B was -0.54 ± 2.64 mm ($p=0.26$) and total horizontal displacement was -0.01 ± 1.06 mm ($p=0.94$).

The results of multiple linear regression analysis are shown in table-5. The results provide evidence that each 10° retroclination of maxillary incisor results in a borderline statistically significant displacement of point A of 0.6 mm in upward direction and conversely, each 10° proclination of maxillary incisor results in borderline statistically significant displacement of point A of 0.6 mm in downward direction ($p=0.06$). There was no evidence that incisal inclination changes result in significant changes in horizontal position of point A ($p=0.41$) and, vertical ($p=0.7$) and horizontal ($p=0.4$) position of point B.

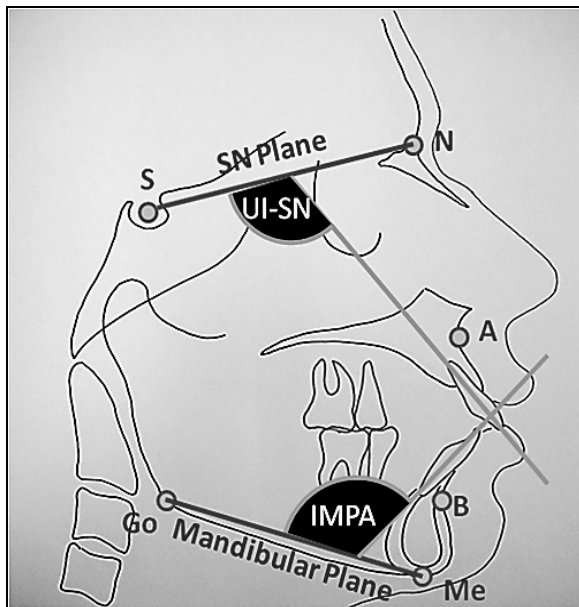


Figure-1: Illustration of various landmarks, planes and angles

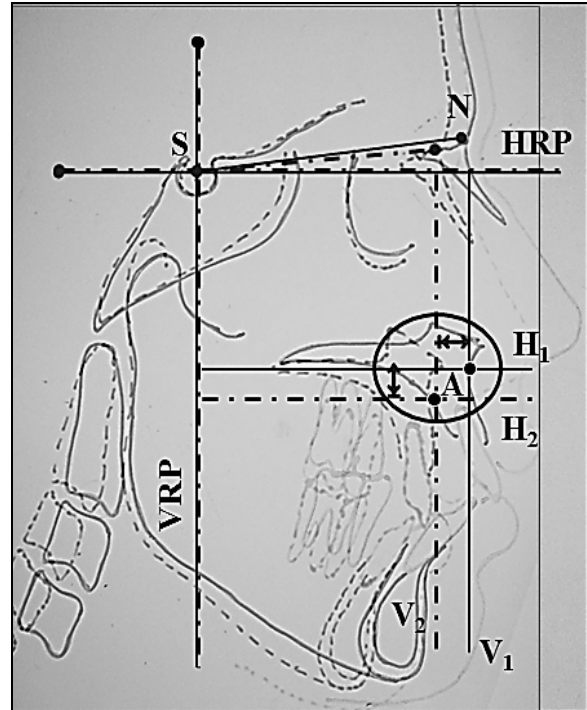


Figure-2: Illustration of superimposition of pre and post treatment tracings at point sella for determination of change in position of point A

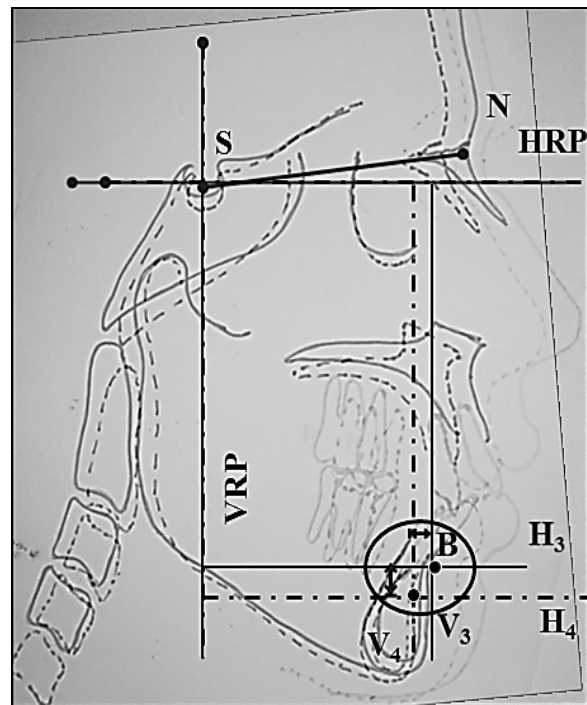


Figure-3: Illustration of superimposition of pre and post treatment tracings on lingual contour of symphysis for determination of change in position of point B

Table-1: Cephalometric landmarks, reference planes, and angular measurements

Landmark, Plane or Angle	Abbreviation	Definition
Sella	S	Centre of the pituitary fossa of the sphenoid bone
Nasion	N	Junction of the frontonasal suture at the most posterior point on the curve at the bridge of the nose
A point	A	Most posterior point on the curve of the maxilla between the anterior nasal spine and superdentale
B point	B	Most posterior point to a line from infradentale to pogonion on the anterior surface of the symphyseal outline of the mandible
Menton	Me	Most inferior point on the symphyseal outline of the mandible
Gonion	Go	Bisector of the angle between tangent through the posterior margin of the ascending ramus and tangent to the mandibular base at menton ¹³
Upper incisor apex	UIA	Incisal apex of the most prominent upper central incisor
Upper incisor edge	UIE	Incisal edge of the most prominent upper central incisor
Lower incisor edge	LIE	Incisal edge of the most prominent lower central incisor
Lower incisor apex	LIA	Incisal apex of the most prominent lower central incisor
Upper incisor axis	UI	Line drawn through UIA and UIE
Lower incisor axis	I	Line drawn through LIE and LIA
Sella-nasion	SN	Plane through sella and nasion
Mandibular plane	MP	Plane drawn through Me and Go
Horizontal reference plane	HRP	Horizontal reference plane was constructed at 7° inferior to SN ¹⁴
Vertical reference plane	VRP	Vertical reference plane was drawn as a perpendicular to HRP at sella ¹⁴

Table-2: Summary table showing correlations to assess intra-examiner reliability

Variables	p-value	r
IMPA	0.001*	93.1
UI-SN	0.001*	88.9
A _v	0.001*	99.9
A _H	0.001*	98.3
B _v	0.001*	98.1
B _H	0.001*	98.2
Pearson correlation p≤0.05 *p≤0.01	IMPA°=Incisor-Mandibular Plane Angle UI-SN°=Upper Incisor-SN Plane Angle A _v =Total vertical displacement of point A A _H =Total horizontal displacement of point A B _v =Total vertical displacement of point B B _H =Total horizontal displacement of point B	

Table-3: Treatment changes in angular parameters

Variables	Mean±SD (degrees)	p-value
IMPA°	Pre-treatment	102.19±7.16
	Post-treatment	98.13±7.58
UI-SN°	Pre-treatment	111.94±5.50
	Post-Treatment	103.23±9.15

n=31, MPA°=Incisor-Mandibular Plane Angle, Paired-sample t-test, UI-SN°=Upper Incisor-SN Plane Angle, p≤0.01

Table-4: Treatment changes in linear parameters

Variables	Mean Distance±SD (mm)	p-value
A _v	1.49±1.94	0.001*
A _H	1.61±2.20	0.001*
B _v	-0.54±2.64	0.26
B _H	-0.01±1.06	0.94
n=31	A _v =Total vertical displacement of point A	
One-sample t-test	A _H =Total horizontal displacement of point A	
*p≤0.01	B _v =Total vertical displacement of point B	
p≤0.05	B _H =Total horizontal displacement of point B	

Table-5: Results of multiple linear regression analysis for the effect of maxillary and mandibular incisor inclination changes on position of points A and B in horizontal and vertical directions

Effect of incisal inclination change on:	Coefficient (mm per degree of inclination change)	p-value	95% Confidence Interval	
			Lower limit	Upper limit
Point A in vertical direction	-0.06*	0.06	-0.24	0.01
Point A in horizontal direction	-0.06*	0.41	-0.21	0.09
Point B in vertical direction	0.02*	0.7	-0.19	0.15
Point B in horizontal direction	-0.03*	0.4	-0.1	0.5

n=31, p≤0.05, *Minus sign indicate opposite effect of incisal inclination change

DISCUSSION

Changes in the positions of points A and B may be due to skeletal changes, which result from movement of maxilla and mandible relative to anterior cranial base (growth), and local changes, which are instigated by local bone remodelling associated with changes in upper and lower incisor inclination during orthodontic treatment. The purpose of this study was to evaluate the position of points A and B associated with upper and lower incisor inclination changes, respectively. In this study, adult patients were procured in order to account for the skeletal changes.

In order to consider the local changes due to dentoalveolar remodelling, methods of superimposition at various structures have been used for many years. Unfortunately, the maxilla is subjected to extensive periosteal remodelling, and no really satisfactory stable sites are available for superimposition.¹⁵ Proffit¹⁶ suggested that the most useful approach is to superimpose on the SN line, registering the template over the patient's tracing at the nasion rather than the sella if there is a difference in cranial base length. On the other hand, Hosten¹⁵ found that this line undergoes little change from growth or remodelling after about 6 years of age, when the sphenothmoidal synchondrosis fuses; he also mentioned that unfortunately, the nasion does not in fact lie on the anterior cranial base but at the outer limit of the frontonasal suture, which does

remodel with growth. Thus, an incorrect impression of the way the face has grown will be obtained if serial radiographs are related to one another by means of this line with registration at the nasion. He suggested that superimposition on the SN line with registration at the sella usually yields a reliable picture of overall facial change.

In our study, we found that total change in the position of point A after orthodontic treatment, relative to cranial base, was in downward and forward direction. Total vertical displacement of point A was 1.49 ± 1.94 mm ($p=0.001$) and total horizontal displacement was 1.61 ± 2.20 mm ($p=0.001$). These findings are in concordance to Al-Nimri *et al*¹⁷ who found that movement of point A, relative to cranial base, was in a downward and forward direction.

Few studies^{2,18} have also been attempted to investigate the effect of root torque of upper incisors on position of point A. Cangialosi and Meistrell⁸ studied changes associated with palatal root torque of the upper incisor and point A in adolescent patients. They demonstrated statistically significant correlation between changes in upper incisor root position and point A as they moved posteriorly by 1.7 mm and 3.5 mm, respectively. Similarly, Goldin¹⁸ compared the effect of labial root torque on point A in 17 subjects to a matched control group in an attempt to account for growth. He found that labial root torque resulted in an increase in skeletal convexity. We have taken all the extraction cases in which anterior teeth retraction was mainly done by bodily movement that is why our study did not consider the effect of root torque on position of point A.

In this study, all the subjects meeting the inclusion criteria have been taken regardless of their malocclusion. There have been some studies¹⁹⁻²¹ which state that in class II division 2 malocclusion, SNA angle is affected at the end of the treatment due to change in position of point A. Arvysts¹⁹⁻²⁰ presented two cases of nonextraction treatment of severe Class II division 2 malocclusion; at the end of treatment, he noticed that the SNA angle was reduced. In addition, Cleall and BeGole²¹ also noted that the SNA angle was reduced in Class II division 2 malocclusion. However, Al-Nimri *et al*¹⁷ found that change in position of point A was so small that it did not affect the value of SNA angle.

To analyse the effect of incisor inclination changes on position of point A, various studies¹¹⁻¹⁷ have been conducted. Our study reports that total changes in position of point A, relative to upper incisor inclination changes of 10° , were marginally statistically significant of 0.6 mm in upward direction ($p=0.06$). These findings are in contrast to Al-Abdwani *et al*¹¹ who found insignificant results for

change in position of point A due to upper incisor inclination changes in vertical direction.

Al-Abdwani *et al*¹¹ reported significant results for change in position of point A due to incisor inclination changes in horizontal direction. They demonstrated that each 10° retroclination of the maxillary incisor results in statistically significant advancement of point A of 0.4 mm in the horizontal plane and vice versa ($p=0.028$). Similarly, Erverdi¹⁰ reported that there is a significant correlation between the axial inclination of the upper incisors and the position of point A. However, we found an insignificant difference in the position of point A in horizontal direction.

For the evaluation of change in position of point B with reasonable accuracy, pre and post treatment tracings were superimposed on lingual contour of symphysis. According to Sazmann²² superimposition on lingual contour of symphysis is more reliable and acceptable method to appraise the treatment effects relative to mandible. True mandibular rotation is greater during transition to the early mixed dentition than adolescents and even at any time thereafter.²³⁻²⁴ Although, the amount of mandibular rotation in adulthood is less than that of adolescence but it might confound the results. Thus, to control the confounder of mandibular rotation, superimposition of tracings was done on lingual contour of symphysis.

In our study, we found that the total change in position of point B after orthodontic treatment, relative to cranial base, was in upward and backward direction but it was not statistically significant. Total vertical displacement of point B was -0.54 ± 2.64 mm ($p=0.26$) and total horizontal displacement was -0.01 ± 1.06 mm ($p=0.94$). The negative sign indicates that change in position of point B was in upward and backward direction.

As far as change in position of point B due to incisor inclination changes is concerned, we found insignificant results for both in the horizontal and vertical direction. This may be in consequence of a small sample size. There is a higher possibility that one can find a significant relationship of change in position of point B due to lower incisor inclination changes with a larger sample size. Al-Abdwani *et al*¹¹ also reported that there is no evidence of significant vertical displacement of point B due to lower incisor inclination changes. However, they found borderline significant relationship for horizontal displacement of point B. They demonstrated that each 10° change in lower incisor inclination causes 0.3 mm horizontal displacement of point B in the opposite direction. It means retroclining the lower incisors by 10° , point B will move in backward direction by 0.3 mm and vice versa.

The results of the study suggest that change in maxillary and mandibular incisor inclinations during orthodontic treatment affects the position of only point A due to dentoalveolar remodelling. But the magnitude of change in the position of this skeletal landmark is not immense enough to be clinically consequential.

CONCLUSIONS

- The total change in position of point A is in downward and forward direction
- There is no evidence of change in position of point B in any direction
- Change in upper incisor inclination causes change in position of cephalometric point A only in vertical direction
- Change in lower incisor inclination is not significantly related to the change in position of cephalometric point B

REFERENCES

1. Mills JR. The effect of orthodontic treatment on skeletal pattern. *Br J Orthod* 1978;5(3):133–43.
2. Taylor CM. Changes in the relationship of nasion, point A and point B and the effect on ANB. *Am J Orthod* 1969;56(2):143–63.
3. Jacobson A. The Wits appraisal of the jaw disharmony. *Am J Orthod* 1975;67(2):125–38.
4. Kim YH, Vietas JJ. Anteroposterior dysplasia indicator: an adjunct to cephalometric differential diagnosis. *Am J Orthod* 1978;73(6):619–33.
5. McNamara JA. A method of cephalometric evaluation. *Am J Orthod* 1984;86(6):449–69.
6. Nanda RS, Merrill RM. Cephalometric assessment of sagittal relationship between maxilla and mandible. *Am J Orthod Dentofacial Orthop* 1994;105(4):328–44.
7. Hall-Scott J. The maxillary-mandibular planes angle (MM degree) bisector (a new reference plane for anteroposterior measurement of dental bases). *Am J Orthod Dentofacial Orthop*. 1994;105(6):583–91.
8. Cangialosi TJ, Meistrell ME Jr. A cephalometric evaluation of hard and soft tissue changes during the third stage Begg treatment. *Am J Orthod* 1982;81(2):124–9.
9. Knight H. The effects of three methods of orthodontic appliance therapy on some commonly used cephalometric angular variables. *Am J Orthod Dentofacial Orthop* 1988;93(3):237–44.
10. Erverdi N. A cephalometric study of changes in point A under the influence of upper incisor inclinations. *J Nihon Univ Sch Dent* 1991;33(3):160–65.
11. Al-Abdwani R, Moles DR, Noar JH. Change of incisor inclination effects on points A and B. *Angle Orthod* 2009;79(3):462–7.
12. Riolo ML, Moyers RE, McNamara JA Jr, Hunter WS. An Atlas of Craniofacial Growth: Cephalometric Standards from the University School Growth Study. Monograph 2, Craniofacial Growth Series. Ann Arbor, Mich: Center for Human Growth and Development, University of Michigan, Ann Arbor; 1974.
13. Knight H. The effects of three methods of orthodontic appliance therapy on some commonly used cephalometric angular variables. *Am J Orthod Dentofacial Orthop* 1988;93(3):237–44.
14. Macdonald KE, Kapust AJ, Turley PK. Cephalometric changes after the correction of Class III malocclusion with maxillary expansion/facemask therapy. *Am J Orthod Dentofacial Orthop* 1999;116(1):13–24.
15. Houston W, Tulley J, Stephans CD. A Textbook of Orthodontics. 2nd ed. Bristol, UK: Wright; 1992;95–116.
16. Proffit WR. Contemporary Orthodontics. 2nd ed. St Louis, Mo: Mosby Year Book Inc; 1993:33–4, 174–5.
17. Al-Nimri KS, Hazza'a AM, Al-Omari RM. Maxillary incisor proclination effect on the position of point A in class II division 2 malocclusion. *Angle Orthod* 2009;79(5):880–4.
18. Goldin B. Labial root torque: effect on the maxilla and incisor root apex. *Am J Orthod Dentofacial Orthop*. 1989;95(3):208–19.
19. Arvysts MG. Nonextraction treatment of severe Class II division 2 malocclusion: part 1. *Am J Orthod Dentofacial Orthop* 1990;97(6):510–21.
20. Arvysts MG. Nonextraction treatment of severe Class II division 2 malocclusion: part 2. *Am J Orthod Dentofacial Orthop*. 1991;99(1):74–84.
21. Cleall JF, BeGole EA. Diagnosis and treatment of Class II division 2 malocclusion. *Angle Orthod* 1982;52(1):38–60.
22. Salzmann JA. The research workshop on cephalometrics. *Am J Orthod* 1960;46:834–47.
23. Spady M, Buschang PH, Demirjian A. Mandibular rotation and angular remodeling during childhood and adolescence. *Am J Hum Biol* 1992;4:683–9.
24. Wang M, Buschang PH, Behrents R. Mandibular rotation and remodeling changes during early childhood. *Angle Orthod*. 2009;79(2):271–5.

Address for Correspondence:

Attiya Shaikh, Program Coordinator Orthodontics Residency Program, Aga Khan University Hospital, Stadium Road, Karachi 74800-Pakistan.

Cell: +92 307 222 4463

Email: attiya.shaikh@aku.edu