

CASE REPORT

VARICOCELE EMBOLIZATION FOLLOWING FAILURE OF VARICOCELECTOMY: A CASE SERIES AND REVIEW OF LITERATURE

Zain Badar, Michael Rachun*, Zerwa Farooq, Megan Calabrese, Anthony Mohamed, Mohammed Jawed

The State University of New York (SUNY), Upstate Medical Centre, *St Georges University School of Medicine-USA

Varicocelectomy remains the same mainstay of treatment for varicoceles. However, with growing focus on minimally invasive techniques, recent literature has investigated the use of venous embolization for the treatment of varicoceles in patients with recurrence after surgical treatment. Embolization has many advantages, including use of local anaesthesia, lower operating time, decreased risk of hydrocele and faster recovery times. In addition to this direct visualization of the vasculature during embolization allows for identification of any anatomic variants or collateral vessel accounting for the recurrence. This permits more definitive treatment in case of prior surgical failure. We present a case series where venous embolization is successfully done following failure of varicocelectomy. For patients who experience recurrence after a varicocelectomy, we recommend consideration for varicocele embolization.

Keywords: Varicocelectomy; Varicocele embolization; Recurrence

J Ayub Med Coll Abbottabad 2016;28(4):826-9

INTRODUCTION

It has long been established that varicocele plays a role in male infertility and several studies support the hypothesis that varicocele repair can improve sperm count and motility.¹⁻³

Varicocelectomy is the most popular method involved in varicocele repair, with recurrence rates ranging from 1.05–14.97% depending on the technique used.⁴ However, varicocele embolization, being a minimally invasive technique, is also emerging as a treatment option for a certain patient group. Recent developments in varicocele management focus on the utilization of embolization following varicocelectomy failure. A growing body of evidence suggests that surgical failure may be the result of pre-existing collateral gonadal veins and that retrograde varicocele embolization is better suited to identify and eliminate these collaterals.^{5,6}

CASE 1

A 33-year-old male status post bilateral varicocelectomy in 2006 with attempted left varicocele embolization in 2013 who had been experiencing scrotal discomfort during exercise in addition to inability to conceive for a period of six months. Physical exam revealed grade III varicocele on the left side and grade II on the right. A testicular ultrasound revealed bilateral varicoceles, with the left side being larger in size as compared to the right (Figure-1).

Left gonadal venogram demonstrated prominent and dilated tortuous veins with incompetent valves filling the left pampiniform

plexus (Figure-2A). Coil embolization was used to occlude the main left gonadal vein with coils extending superiorly to the level of the left proximal gonadal vein. Post embolization venogram with and without valsalva manoeuvre demonstrated no flow in the left gonadal vein (Figure-2B).

At one-week follow-up, the patient had decreased pain in the left scrotum. CT abdomen/pelvis at the three-week follow up visit demonstrated findings consistent with previous embolization of the left gonadal vein.

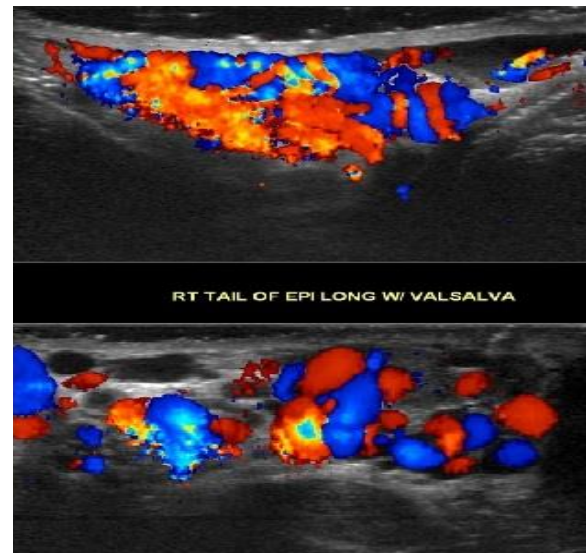


Figure-1: Doppler ultrasound shows dilated serpiginous veins within the testicles bilaterally, consistent with varicoceles.

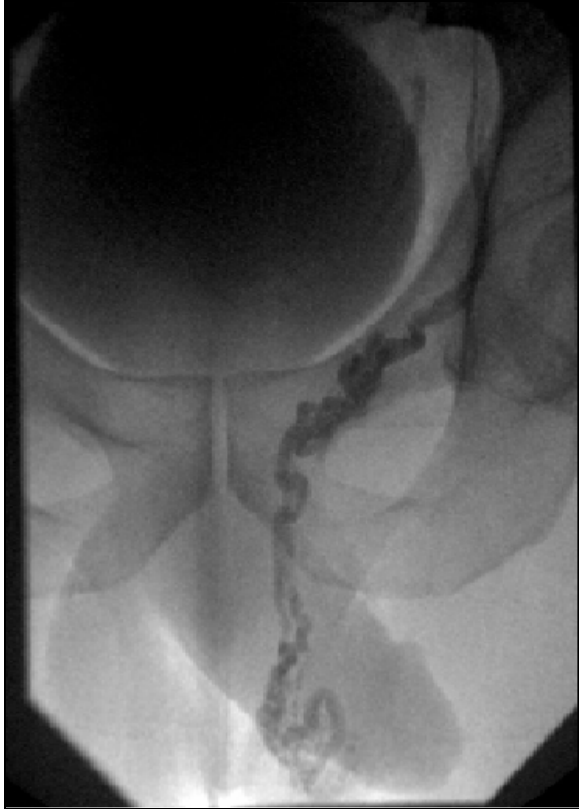

Figure-2A: Left gonadal venogram demonstrated prominent and dilated tortuous veins with incompetent valve filling the left pampiniform plexus.

CASE 2

Twelve year-old-male, status post left laparoscopic varicocelectomy presented with persistent intermittent left testicular pain.

Doppler ultrasound of the scrotum demonstrated a moderate to large left sided varicocele (Figure-3). Interventional radiology was consulted and the patient underwent a left varicocele embolization. The left gonadal venogram showed prominent vein with incompetent valve filling the left pampiniform plexus. Multiple coils were placed within the entirety of the left gonadal vein with the post embolization venogram demonstrating no flow in the left gonadal vein (Figure-4). At 6-month follow-up, the patient reported a reduction in testicular pain with the physical examination showing a reduction in the size of the varicocele.

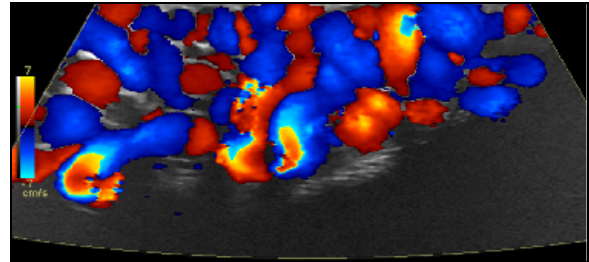


Figure-3: Doppler ultrasound shows dilated serpiginous veins within the left testicle, consistent with a moderate-large varicocele.

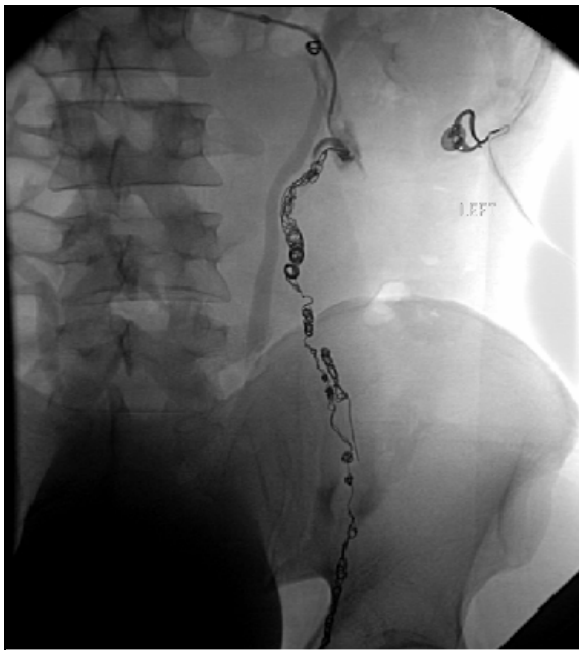

Figure-2B: Left gonadal venogram showing embolization of the left gonadal vein using multiple coils.

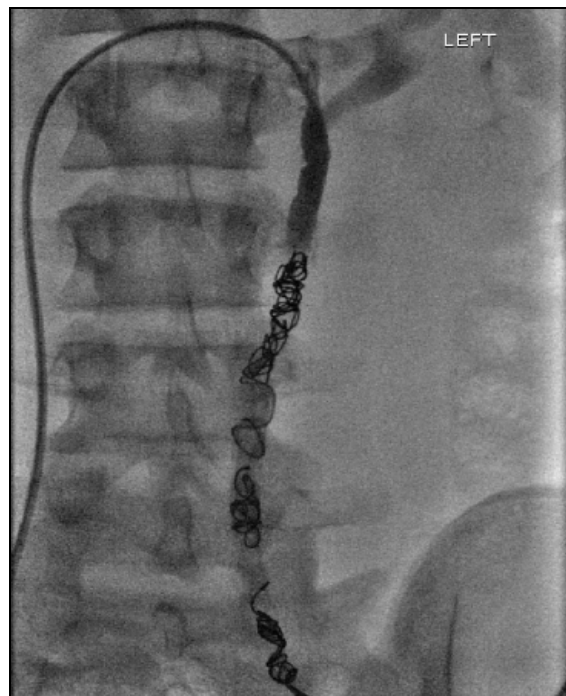

Figure-4: A left gonadal venogram showing multiple coils within the left gonadal vein.

CASE 3

A 49-year-old male with history of left varicocelectomy approximately 20 years ago, presented with chief complaint of intermittent scrotal discomfort worsened by heavy lifting and straining.

A testicular ultrasound demonstrated bilateral varicoceles (Figure-5). The patient subsequently decided to undergo bilateral varicocele embolization. The left gonadal vein was successfully embolized (Figure-6A). However, there was difficulty cannulating the right gonadal vein leading to non-embolization of the vein (Figure-6B).

At five months follow-up, the patient reported resolution of left testicular pain and wanted no further intervention with regards to the right testicle.

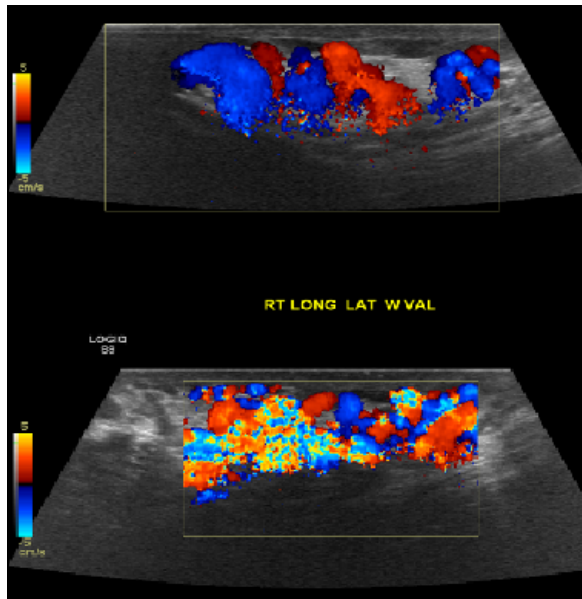


Figure-5: Doppler ultrasound shows dilated serpiginous veins within the testicles bilaterally, consistent with varicoceles.

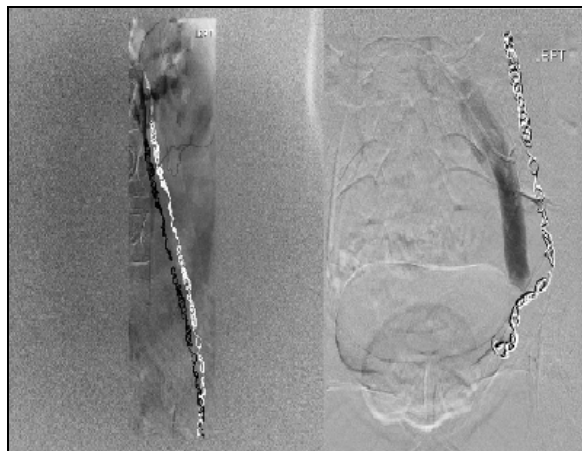


Figure-6A: A left gonadal venogram demonstrating multiple coils within the left gonadal vein.

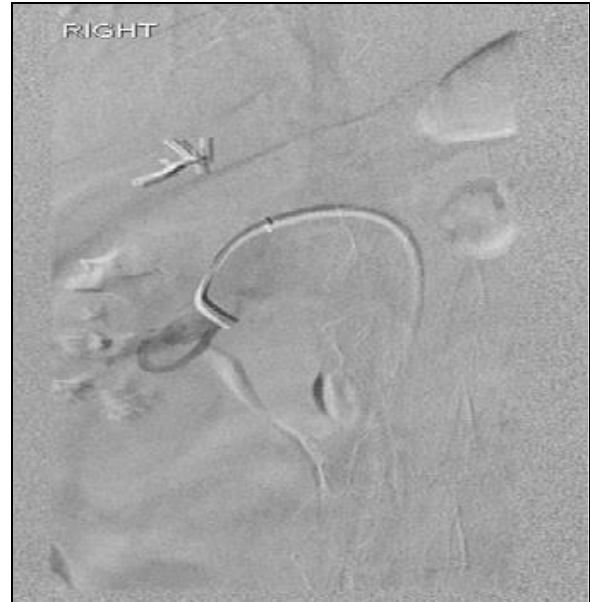

Figure-6B: Right renal venogram with inability to cannulate the right gonadal vein.

DISCUSSION

The treatment of varicocele may be accomplished by surgical repair or percutaneous embolization. While both techniques are effective and carry low rates of complication and morbidity, each has certain advantages and disadvantages when compared to the other. Percutaneous embolic therapy is minimally invasive, allows for quicker outpatient recovery with less overall patient discomfort, and is more cost-effective than surgery.⁷ However, technical difficulty of embolizing right-sided varicoceles is well documented in literature. While complications for left-sided procedures are low, several studies have shown failure rates as high as 49% in right-sided attempts.⁸ This owes largely to the anatomy of the right gonadal vein, as it branches from the IVC at an acute angle inferior to the right renal vein, necessitating percutaneous access from the internal jugular or basilic vein. Further complications of the embolization technique include contrast reaction, flank pain, and the potential for migration of the embolizing agent. Additionally, radiation exposure during fluoroscopy is of particular concern in younger patients for whom fertility is an issue.

On the basis of our review of the literature and our own case findings, we propose that embolization should be considered when a patient has already failed surgical repair but at this time should not be the primary treatment option in cases of varicocele if surgical varicocelectomy is a viable option and is yet to be attempted. Optimizing patient selection invariably confers greater success. In the setting of recurrent varicocele following surgery, success rates for percutaneous embolization have been extremely high, ranging from 93–100%.⁹

Three of our patients underwent embolization for the recurrence of varicocele following surgical repair. In each of these cases, patients reported resolution of testicular pain following embolic treatment. Post-embolization imaging and physical examination demonstrated a cessation of flow in the affected veins and an overall reduction in the size of the varicoceles. There is growing evidence in the literature that varicocele embolization following unsuccessful surgical repair is a highly effective means of reducing the recurrence of varicocele and associated pain.¹⁰ Because laparoscopic and other surgical methods often do not employ intraoperative imaging techniques to visualize the affected vessels, it is likely that anatomic variants in certain patients go undetected.¹¹ Varicocele embolization with venography allows for mapping of the affected vasculature and precise occlusion of the target vessels. Thus, for those patients who have varicocele recurrence following surgery, embolization can offer a definitive resolution of symptoms.

In our series, the repair of varicocele by percutaneous embolization was effective for patients who had previous surgical repair. Our success in treating varicocele for those patients who already had surgery suggests a crucial role for percutaneous embolization in identifying and occluding collateral draining vessels that allowed for recurrence following surgery. At this point, we suggest that varicocele embolization should be considered when prior varicocelectomy fails, but should not be used as a primary option for repair. Additionally, the persistence of right-sided varicocele in one of our patients demonstrates the technical difficulty of both surgical and embolic procedures in this area, owing to the anatomic nature of the right gonadal vein. While debate continues regarding embolization as a first-line intervention for varicocele, the long-proven efficacy of surgical varicocelectomy is still considered the main option for primary intervention. However, should the varicocele recur, embolization is an excellent treatment option.

CONCLUSION

Based on the results of our cases and research, we recommend performing venous embolization to treat recurrent varicocele in patients who have previously had

an unsuccessful surgical treatment. Embolic treatment has been shown to be efficacious, financially sound, and definitive for those patients in whom venous insufficiency has occurred following surgery. The advantage of visualizing the affected vasculature and thereby recognizing potential anatomic variants allows for the precise and final resolution of the varicocele. Because varicocelectomy has been a long-standing, effective means of initial treatment and because instances of failure in newer microsurgical techniques have remained low, we still recommend surgery as a primary intervention. However, for those patients who experienced varicocele recurrence, embolization should be strongly considered.

REFERENCES

1. French DB, Desai NR, Agarwal A. Varicocele repair: does it still have a role in infertility treatment? *Curr Opin Obstet Gynecol* 2008;20(3):269–74.
2. Elbendary MA, Elbadry AM. Right subclinical varicocele: how to manage in infertile patients with clinical left varicocele? *Fertil Steril* 2009;92(6):2050–3.
3. Puneekar SV, Prem AR, Ridhorkar VR, Deshmukh HL, Kelkar AR. Post-surgical recurrent varicocele: efficacy of internal spermatic venography and steel-coil embolization. *Br J Urol* 1996;77(1):124–8.
4. Cayan S, Shavakhabov S, Kadioglu A. Treatment of palpable varicocele in infertile men: a meta-analysis to define the best technique. *J Androl* 2009;30(1):33–40.
5. Jargiello T, Drelich-Zbroja A, Falkowski A, Sojka M, Pyra K, Szczerbo-Trojanowska M. Endovascular transcatheter embolization of recurrent postsurgical varicocele: anatomic reasons for surgical failure. *Acta Radiol* 2015;56(1):63–9.
6. Moon KH, Cho SJ, Kim KS, Park S, Park S. Recurrent Varicoceles: Causes and Treatment Using Angiography and Magnification Assisted Subinguinal Varicocelectomy. *Yonsei Med J* 2012;53(4):723–8.
7. Storm DW, Hogan MJ, Jayanthi VR. Initial experience with percutaneous selective embolization: A truly minimally invasive treatment of the adolescent varicocele with no risk of hydrocele development. *J Pediatr Urol* 2010;6(6):567–71.
8. Halpern J, Mittal S, Pereira K, Bhatia S, Ranjith R. Percutaneous embolization of varicocele: technique, indications, relative contraindications, and complications. *Asian J Androl* 2016;18(2):234–8.
9. Puche-Sanz I, Flores-Martin JF, Vasquez-Alonso F, Pardo-Moreno PL, Cozar-Olmo JM. Primary treatment of painful varicocele through percutaneous retrograde embolization with fibred coils. *Andrology* 2014;(2):716–20.
10. Kim J, Shin JH, Yoon HK, Ko GY, Gwon DI, Kim EY, Sung KB. Persistent or recurrent varicocele after failed varicocelectomy: Outcome in patients treated using percutaneous transcatheter embolization. *Clin Radiol* 2011;67(4):359–65.

Received: 10 July, 2016

Revised: 10 September, 2016

Accepted: 16 September, 2016

Address for Correspondence:

Zain Badar, The State University of New York, Upstate Medical Centre, 750 E Adams St, Syracuse, NY 13210-USA

Email: badarz@upstate.edu