

CASE SERIES

HYDROCEPHALUS AND CRANIOSYNOSTOSIS IN PAEDIATRICS:
COEXISTENCE OF TWO PHENOMENA

Khrisna Rangga Permana, Muhammad Arifin Parenrengi, Wihasto Suryaningtyas

Neurosurgery Department, Faculty of Medicine Universitas Airlangga, Dr. Soetomo Academic General Hospital, Surabaya-Indonesia

Background: Here, the authors describe their institutional experience managing patients who had hydrocephalus and craniosynostosis regarding their pre-operative and post-operative data. **Methods:** The study was conducted in the Neurosurgery Department, Dr. Soetomo Academic General Hospital, Surabaya, Indonesia. Four patients with craniosynostosis had hydrocephalus based on our database and all of those four cases were reviewed. The authors retrospectively reviewed the patient's demography, clinical findings, radiology results, operative procedures, and complications after surgery. **Results:** Four patients underwent the cerebrospinal fluid (CSF) procedure and survived the procedure. Three patients were operated at the first 1 year of age and one patient at 2 years old. There were no major complications (sepsis, reoperation, death) postoperatively. **Conclusion:** The mechanism of the hydrocephalus in craniosynostosis was not fully elucidated. Suspicion of hydrocephalus should be anticipated in every case of craniosynostosis and further examination such as a CT scan was necessary. In the setting of progressive ventriculomegaly, a CSF diversion should be performed.

Keywords: Hydrocephalus; Craniosynostosis; Coexistence; Neurosurgery

Citation: Permana KR, Parenrengi MA, Suryaningtyas W. Hydrocephalus and Craniosynostosis in Paediatrics: Coexistence of Two Phenomena. J Ayub Med Coll Abbottabad 2024;36(1):210–3.

DOI: 10.55519/JAMC-01-12253

INTRODUCTION

Patients with multisuture craniosynostosis and, less typically, single-suture craniosynostosis may develop hydrocephalus.^{1,2} The correlation between hydrocephalus and craniosynostosis has been well established, and the prevalence of hydrocephalus has been estimated to be between 4% and 10% of the population.³ The causal relationship in this group is not well understood. Hence, we present our single institution's case series.

CASE REPORTS

We identified twelve cases of craniosynostosis patients who had not undergone cerebrospinal fluid (CSF) diversion nor cranial vault reconstruction procedure yet in our databases of the Department of Neurosurgery, Dr. Soetomo Academic General Hospital, Surabaya in the years 2013–2022. We searched for keywords of craniosynostosis with hydrocephalus and this search resulted in four cases. After retrieving the patients, we analysed patient's demography,

clinical findings, radiology results, operative procedures, and complications after surgery.

Case 1

A 4-month-old male patient came to our emergency department with seizure. A seizure was reported for the last 2 months and on the anti-seizure drug from the paediatrician. He was diagnosed with hydrocephalus from antenatal sonography. He had an uneventful delivery at 39 weeks via C-section due to ventriculomegaly. He was diagnosed with intrauterine growth restriction during pregnancy. He was referred to the neurosurgery department for uncontrolled seizure despite being on an anti-seizure drug. Head circumference was 37.5 cm below the 3rd percentile, and the major fontanelle was closed. MRI showed multi-suture stenosis with ventriculomegaly suggesting hydrocephalus (Figure-1). There were no associated congenital anomalies and endocrine and metabolic workup was normal. The patient underwent suturectomy and ventricular peritoneal (VP) shunt. The patient had an uneventful postoperative course and was discharged with no headaches, emesis, or fever.

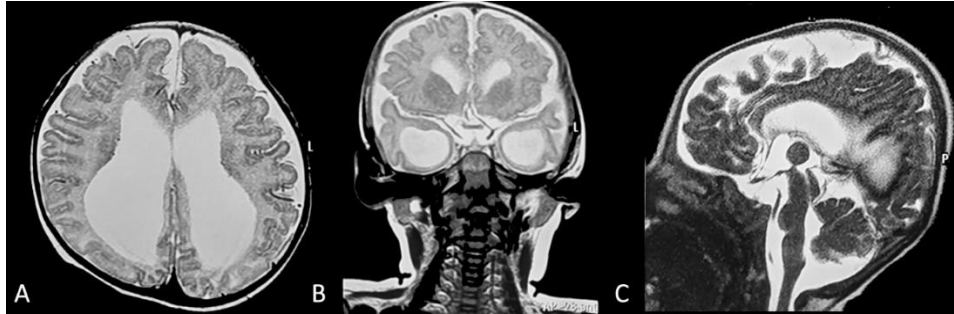

Figure-1: MRI showed craniostenosis on axial (A), coronal (B) and sagittal view (C) with ventriculomegaly suggesting hydrocephalus.

Case 2

A 1-month-old baby girl presented with obvious dysmorphic cranial features. The patient came with complaints of head deformity since birth, the head looked small and the eyes protruded. She had delivery at 32 weeks via C-section due to foetal distress. Patient was unresponsive and cyanotic after delivery. The

patient was successfully resuscitated thereafter. Head circumference was 27 cm and major fontanelle was open and not tense. CT-scan showed multi suture stenosis with ventriculomegaly suggesting hydrocephalus (Figure-2). Patient underwent VP shunt with no reported complication.

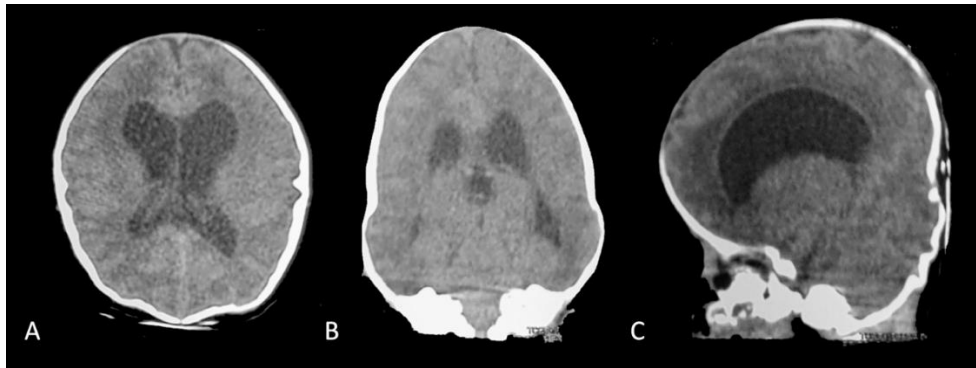


Figure-2: CT-scan showed craniostenosis on axial (A), coronal (B) and sagittal view (C) with ventriculomegaly suggesting hydrocephalus.

Case 3

A 6-month-old infant with seizure was referred to our department. Examination revealed a healthy boy infant who was normal apart from the craniofacial deformity. The mother had a normal pregnancy and delivery and she did not use any medication. Physical examination showed a microcephaly with head circumference 42

cm. The child was not fully conscious, opening eyes with voice response, moving actively and crying weakly. Patient had surgical history of burrhole drainage for subdural hygroma 5 months prior admission. CT-scan revealed craniostenosis with severe hydrocephalus (Figure-3). The patient had a VP shunt, with no major problems during post-operative care.

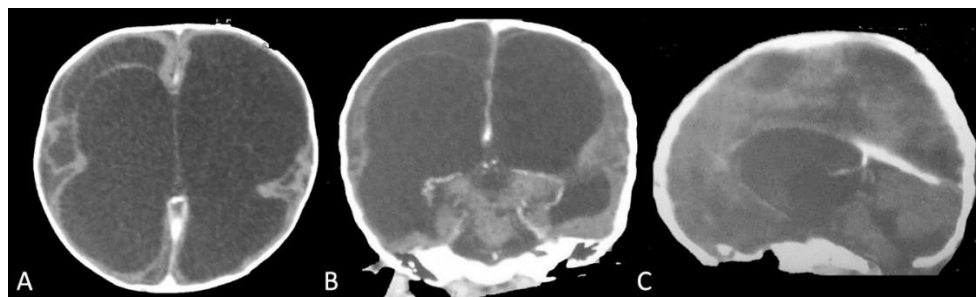

Figure-3: Preoperative CT-scan revealed craniostenosis on axial (A), coronal (B) and sagittal view (C) with severe hydrocephalus.

Case 4

A 2-year-old girl with decrease of consciousness was consulted to our department by paediatrician. Patients with a history of enlargement of the cerebrospinal fluid since birth. Physical examination showed head

circumference 45cm with morphological disproportion. Patient had surgical history of external ventricular drainage and endoscopic irrigation due to infection at 2-month-old. Emergency CT-scan showed hydrocephalus and multisuture craniosynostosis (Figure-4,5).

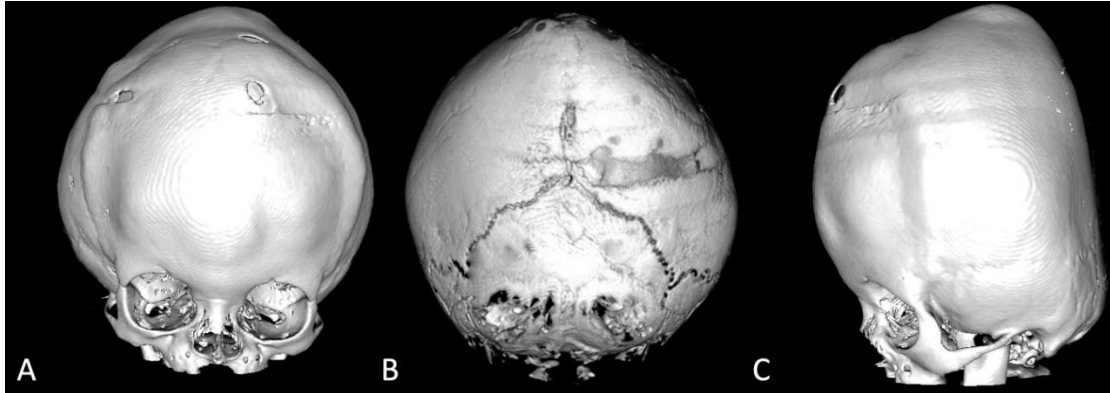


Figure-4: Preoperative Three Dimensional (3D) rendered CT-scan revealed multi suture craniosynostosis on axial (A), coronal (B) and sagittal view (C)

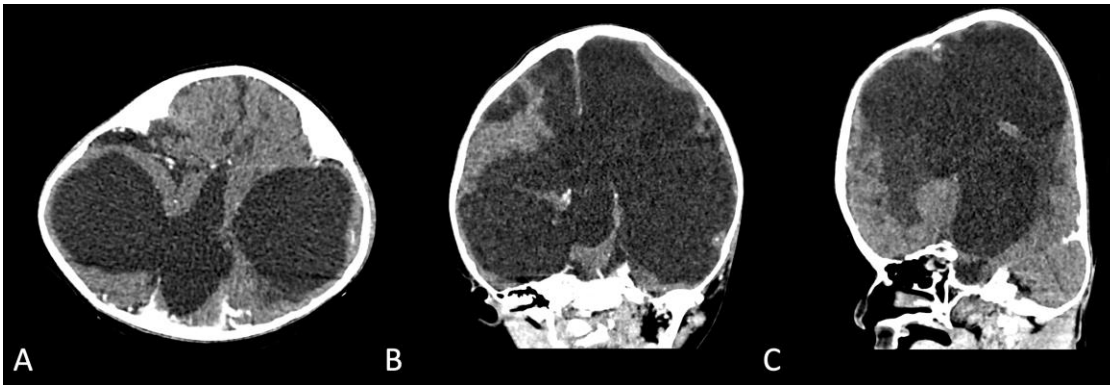


Figure-5: CT-scan revealed hydrocephalus on axial (A), coronal (B) and sagittal view (C)

DISCUSSION

Patients with complex, syndromic, and multisuture craniosynostosis are more likely to develop hydrocephalus.³ Hydrocephalus in children with craniosynostosis has an aetiology that is unknown. CSF outflow blockage is common in these patients due to craniocerebral disproportion and a tiny posterior fossa.⁴ This approach, however, has a flaw in that posterior fossa decompression frequently fails to restore normal CSF circulation and improve hydrocephalus. However, more recent research has looked into venous abnormalities in these patients as a possible source of hydrocephalus and intracranial hypertension.⁵ The assumption of venous sinus hypertension as a major contributor in progressive hydrocephalus is central to the second hypothesis of reduced CSF absorption due to insufficient venous outflow.⁶ A stenosis of the jugular foramen, which has

been described in syndromic craniosynostosis, can produce venous sinus hypertension. Another study found that in syndromic craniosynostosis, there is not just jugular foramen stenosis, but also an extensive venous collateral network. Because the majority of patients with progressive hydrocephalus have both venous outflow blockage and a weakened posterior fossa, a combined action of both causes is currently recommended. One possible theory is that venous hypertension promotes reduced CSF absorption and brain enlargement, resulting in a crowded posterior fossa; or that venous engorgement aggravates pre-existing cephalocranial disproportion.^{6,7}

Progressive hydrocephalus can occur in craniosynostosis as a result of either CSF outflow blockage or malabsorption, both of which are either directly or indirectly related to osseous pathology or to coincidental illnesses unrelated to craniosynostosis. Hydrocephalus can progress quickly or slowly as a

result of a higher or lower intracranial pressure, or it can be corrected, resulting in a normal intracranial pressure. If the skull is still capable of expanding, impaired CSF absorption from venous sinus hypertension causes general enlargement of the inner and outer CSF spaces, or it induces a pseudotumour-like state in a non-expanding skull. The few cases of increasing hydrocephalus in isolated monosutural craniosynostosis can nearly always be linked to coincidental illnesses other than craniosynostosis, such as ventricular haemorrhage, meningitis, aqueductal stenosis, and neural tube abnormalities.⁸

The decision to treat and the timing of hydrocephalus treatment must be carefully considered for both multisuture and single-suture patients.^{6,8} Each treatment plan should be designed for the specific needs of the patient, taking into account aspects such as the child's general status, the severity of the craniosynostosis and hydrocephalus, and the planned craniosynostosis surgery. Before beginning treatment for hydrocephalus, it's also important to observe any attributes that could potentially increase intracranial pressure, especially in these individuals. The hydrocephalus treatment was conducted prior to the craniofacial operation in a small percentage of individuals with severe hydrocephalus. If left untreated, elevated intracranial pressure can cause neurological deficits and morbidity, as well as severe bone weakening, making craniofacial reconstruction more challenging.

Because the success rates of Ventriculoperitoneal Shunt (VPS) and Endoscopic Third Ventriculostomy (ETV) appear to be similar, ETV may be an option in children with hydrocephalus and craniosynostosis.^{9,10} In addition, we have found that some families opt to try an ETV with choroid plexus cauterization (CPC) as an initial hydrocephalus procedure in the hopes of gaining shunt freedom. Minimizing VPS insertions also offers the benefit of not leaving hardware in the patients, which may be particularly relevant in patients who may have future cranial vault reconstruction. The VPS is frequently moved in order to finish craniofacial surgery, and exposing the VPS increases the risk of shunt infection. This risk would not exist if the ETV was conducted prior to the craniofacial surgery. The choice to do VPS

or ETV with CPC was decided on a case-by-case basis, taking into account the surgeon's competence, the patient's anatomy, and the surgeon's interaction with the patient's family or caregiver.^{9,11,12}

Hydrocephalus in craniosynostosis is a rare occurrence with various hypotheses for its occurrence. Treatment should be on a case-by-case basis by considering whether CSF diversion is performed immediately or not simultaneously with cranial vault correction.

REFERENCES

1. Bryant JR, Mantilla-Rivas E, Chao JW, Magge SN, Oluigbo CO, Myseros JS, *et al.* Pressure-related craniosynostosis: Treatment of hydrocephalus with ventriculoperitoneal shunt associated with premature cranial suture fusion. *Plast Reconstr Surg Glob Open* 2019;7(8S-1):45–6.
2. Buchanan EP, Xue Y, Xue AS, Olshinka A, Lam S. Multidisciplinary care of craniosynostosis. *J Multidiscip Healthc* 2017;10:263–70.
3. Cinalli G, Sainte-Rose C, Kollar EM, Zerah M, Brunelle F, Chumas P, *et al.* Hydrocephalus and craniosynostosis. *J Neurosurg* 1998;88(2):209–14.
4. Albright AL, Pollack If, Adelson PD. Principles and practice of pediatric neurosurgery. Thieme 2014;7:333.
5. Copeland AE, Hoffman CE, Tsitouras V, Jeevan DS, Ho ES, Drake JM, *et al.* Clinical significance of venous anomalies in syndromic craniosynostosis. *Plast Reconstr Surg Glob Open* 2018;6(1):e1613.
6. Collmann H, Sörensen N, Krauss J. Hydrocephalus in craniosynostosis: a review. *Childs Nerv Syst* 2005;21(10):902–12.
7. Da Costa AC, Walters I, Savarirayan R, Anderson VA, Wrennall JA, Meara JG. Intellectual outcomes in children and adolescents with syndromic and nonsyndromic craniosynostosis. *Plast Reconstr Surg* 2006;118(1):175–81.
8. Choi JW, Lim SY, Shin HJ. Craniosynostosis in growing children: Pathophysiological changes and neurosurgical problems. *J Korean Neurosurg Soc* 2016;59(3):197–203.
9. Bonfield CM, Shannon CN, Reeder RW, Browd S, Drake J, Hauptman JS, *et al.* Hydrocephalus treatment in patients with craniosynostosis: an analysis from the Hydrocephalus Clinical Research Network prospective registry. *Neurosurg Focus* 2021;50(4):E11.
10. Di Rocco F, Jucá CE, Arnaud E, Renier D, Sainte-Rose C. The role of endoscopic third ventriculostomy in the treatment of hydrocephalus associated with faciocraniosynostosis: Clinical article. *J Neurosurg Pediatr* 2010;6(1):17–22.
11. O'Hara J, Ruggiero F, Wilson L, James G, Glass G, Jeelani O, *et al.* Syndromic craniosynostosis: Complexities of clinical care. *Mol Syndromol* 2019;10(1–2):83–97.
12. Agochukwu NB, Solomon BD, Muenke M. Impact of genetics on the diagnosis and clinical management of syndromic craniosynostoses. *Childs Nerv Syst* 2012;28(9):1447–63.

Submitted: July 9, 2023

Revised: December 26, 2023

Accepted: December 26, 2023

Address for Correspondence:

Muhammad Arifin Parenrengi, Neurosurgery Department, Faculty of Medicine Universitas Airlangga, Dr. Soetomo Academic General Hospital, Surabaya-Indonesia

Email: muhammad.arifin@fk.unair.ac.id