

ORIGINAL ARTICLE

ASSESSING ORONASAL FISTULA RATES: MINIPLATE AS EXTERNAL FIXATOR VS ANTERIOR NASAL SPINE PLATING FOR PALATAL FRACTURES

Ain-us-Saba, Muhammad Umar Farooq, Fouzia Aslam, Hamza Hassan Mirza, Abdul Manan Shahid, Muhammad Asad Javed*

Oral and Maxillofacial Surgery, Islamabad Medical and Dental College, Islamabad -Pakistan

*Akbar Niazi Teaching Hospital, Islamabad-Pakistan

Background: Palate, a midface bone, shapes the face and supports buttresses. Palatine process of maxilla and horizontal plate of palatine bone constitute it. Palatal bone is thicker anteriorly and laterally than posteriorly and centrally. Palatal fractures occur with maxillary fractures. Palatal-maxillary fractures occur 8–46.4% of the time.^{2,5} Palatal fractures can cause palatal ecchymosis in closed fractures and lacerations of upper lip, palatal mucosa, incisor tooth loss, or occlusal disruption in displaced fractures. The objective was to determine the surgical outcome of palatal fractures with locking plates as external fixator vs. alveolar plating in terms of frequency of oronasal fistula formation. **Methods:** A Randomized control trial was carried out in Department of Oral and Maxillofacial surgery, Pakistan Institute of Medical Sciences, Islamabad. between 14th July, 2017 to 14th July, 2018. Lottery split patients into groups A and B. Data was collected on designed questionnaire and was entered and analyzed using SPSS v22. Chi-square was applied to check the association. **Results:** A total of 130 patients were enrolled in the trial based on the predefined inclusion criteria. The average age of participants in the research was 41.16 years with a standard deviation of 10.44. Of the total participants, 88 (67.7%) were male and 42 (32.3%) were female, as per the inclusion criteria. The occurrence rate of oronasal fistula development in both groups, namely palatal fractures treated with locking plates as an external fixator vs alveolar plating, was 1 (1.5%) and 7 (10.8%) respectively. This difference was found to be statistically significant with a p-value of 0.029. **Conclusion:** Osteosynthesis using 2.0 mm locking plates as external fixator had a lower rate of oronasal fistula than alveolar plating. Future investigations at numerous configurations are needed to determine which approach is best. such that a regular strategy will reduce infection, fistula development, and necrosis afterwards.

Keywords: Palate; Palatal Fractures; Sagittal Fracture; Locking Plates

Citation: Saba AU, Farooq MU, Aslam F, Mirza HH, Shahid AM, Javed MA. Assessing Oronasal Fistula Rates: Miniplate as External Fixator vs Anterior Nasal Spine Plating for Palatal Fractures. J Ayub Med Coll Abbottabad 2024;36(2):279–83.

DOI: 10.55519/JAMC-02-12367

INTRODUCTION

The palate is a significant osseous structure located in the mid face region, playing a crucial role in determining facial breadth and architecture, as well as providing support to various facial buttresses. The structure in question is created by the amalgamation of the palatine process of the maxilla and the horizontal plate of the palatine bone. The palatal bone exhibits varying thickness, with a thinner region located posteriorly and, in the midline, and a thicker region located anteriorly and laterally.^{1,4}

Palatal fractures typically manifest in conjunction with maxillary fractures, rather than occurring alone. The occurrence of palatal fractures in conjunction with maxillary fractures has a range of 8–46.4%.^{2,5} Individuals who have had palatal fractures may exhibit palatal ecchymosis in cases of closed fractures, whereas displaced fractures may result in laceration of

the upper lip, palatal mucosa, loss of incisor teeth, or disruption of occlusal relation.³

Palatal fractures exhibit various patterns and are classified differently. The classification of these fractures is based on three categories: sagittal, transverse, and comminuted. In their study, Hendrickson *et al.* provided a comprehensive classification of palatal fractures using computed tomography (CT) scans. The authors identified six distinct groups of fractures, including anterior and posterior alveolar fractures, sagittal fractures, Para alveolar fractures, complicated fractures, and transverse fractures. Park proposed an alternative categorization of palatal fractures based on the treatment strategy employed for their management. The categorization scheme categorises palatal fractures based on the therapeutic approach employed, namely closed reduction, anterior treatment, anterior and palatal treatment, and combination treatment.⁴

Various treatment modalities are available for managing palatal fractures, including orthodontic braces,

arch bars, K wires, and internal fixation using plates and screws positioned beneath the palatal mucosa and periosteum. Additionally, pyriform aperture or alveolar plating, together with LeFort level 1 buttress reconstruction, may be employed.^{5,6}

In their study, Rimell *et al.* conducted palatal fixation of the alveolar process in a cohort of 11 patients, without addressing therapy of the palatal vault. The patients were followed up for a duration of 8 months. The author observed a plate exposure rate of 9% and a rate of oronasal fistula necessitating bone graft of 9%.⁷

In a study conducted by Moss *et al.*, a comprehensive analysis was performed on a range of research that examined different procedures for repairing hard palate fractures, while also considering the associated outcome data. The researcher discovered that the predominant technique for stabilising the palatal vault is by closed reduction using circumdental wire and internal plate fixation of the alveolar process.⁸

In 2010, Ricardo *et al.* conducted research whereby they employed a medium or high-profile locking plate as an external fixator positioned over the mucosa in 45 patients, in conjunction with the management of additional facial fractures. At the 12-week mark, the decision was made to remove the plates and screws after a computed tomography (CT) scan revealed signs of successful healing. Additionally, the patient did not experience any oronasal fistula, infection, or bone necrosis.³

However, there is a limited amount of research accessible in the existing literature about the use of external plate fixation for palatal fractures. Therefore, based on the little evidence available, there is currently no consensus about the superiority of one method over another. Hence, the purpose of this study is to undertake a comparative analysis of two techniques in order to determine the strategy that yields favourable postoperative outcomes in relation to infection, fistula development, and necrosis.

MATERIAL AND METHODS

A randomised controlled trial was done on a sample of 130 patients who sought treatment at the Department of Oral and Maxillofacial Surgery, Pakistan Institute of Medical Sciences, Islamabad, between July 14, 2017, and July 14, 2018. The sample size was determined using the WHO calculator, and the patients were selected using a sequential non-probability selection approach. The participants were separated into two groups, each consisting of 65 individuals. The study comprised individuals of both genders, aged between 18 and 55 years, who had sagittal fractures of the palate. Patients with comminuted, transverse, and parasagittal fractures who were either immunocompromised or deemed unsuitable for general anaesthesia were excluded from the study. Following approval from the hospital's ethical

committee, patients with palatal fractures who were admitted to the Oral and Maxillofacial Surgery Department of Pakistan Institute of Medical Sciences in Islamabad were selected for inclusion in the study. These patients were identified through the Out Patient Department (OPD), Emergency department, and referrals from other units of the hospital, provided they met the specified inclusion criteria. All patients or their family provided informed consent. To facilitate the systematic gathering of information and observations, a pre-established proforma was completed. The provided document encompasses biographical information, clinical observations, and subsequent monitoring information.

The diagnosis of a palatal fracture was established after a comprehensive assessment that included a thorough examination of the patient's medical history, careful evaluation of clinical manifestations, analysis of CT scan results, and observations made during the surgical procedure. The surgical procedures were performed on all patients by a cohesive group of surgeons, under general anaesthesia. The patients were allocated into groups A and B using a randomization procedure based on a lottery system. Preoperative baseline studies and assessment of general anaesthesia suitability were conducted before to the surgical procedure. In the case of patients in group A, the fracture was treated by employing six or five holes 2.0 mm locking plates and two locking screws. These were positioned across the palatal mucosa for the purpose of reduction and fixation. In contrast, group B fractures were treated by employing traditional micro plates and micro screws, which were positioned over the anterior nasal spine area (alveolar plating) through an upper vestibular incision. Facial fractures observed in both groups were managed in accordance with established guidelines.

In accordance with the established unit protocol, all patients received intravenous administration of Augmentin 1.2g, intravenous administration of Flagyl (Metronidazole) 500mg, and a preoperative analgesic. These medications were administered throughout the perioperative period and were maintained for a duration of three days in the postoperative phase. The patients were discharged on the third day after surgery if they were considered suitable for discharge and were prescribed oral antibiotics. The prescribed treatment regimen consists of taking Tab. Augmentin (Amoxicillin/clavulanic acid) 625mg three times a day, along with Tab. Flagyl (Metronidazole) 400mg three times a day, for a duration of five days. Additionally, an analgesic should be used as directed. The patients were instructed to adhere to a soft diet and maintain rigorous dental hygiene. They were thereafter monitored for a duration of three months after the surgical procedure, with follow-up appointments scheduled at the 1st, 4th, 8th, and 12th

week intervals. The purpose of these appointments was to evaluate the healing process following the operation, specifically assessing the occurrence of oronasal fistula development. In Group A, the removal of locking plates occurred at a 12-week interval subsequent to the observation of full fracture healing as shown by CT scan data. In contrast, group B did not remove plates, adhering to standard guidelines for subperiosteal plates, unless complications were observed.

Following the surgical procedure, patients underwent postoperative assessment and examination to identify any potential complications. The outcomes were then classified as either favourable or unfavourable, and the corresponding data was meticulously documented in a pre-established proforma. Statistical analysis was conducted using SPSS version 22. The data was subjected to descriptive analysis, followed by the use of a post stratification chi-square test to examine any potential associations between these factors and the ultimate outcome. A significance level of $p < 0.05$ was used to determine statistical significance.

RESULTS

The data was inputted and analysed using SPSS version 22.0. A total of 130 patients were enrolled in the trial based on the predefined inclusion criteria. The descriptive statistics for the age (in years) of the patients were also computed, including the mean and standard deviation. The average age of participants in the research was 41.16 years with a standard deviation of 10.44, as indicated in Table-1. The mean and standard deviation were computed to provide the descriptive statistics of the duration (in months) of trauma. The mean duration of trauma for the two groups was 2.88+1.09 and 3.05+1.23, as presented in Table-2.

The gender distribution of patients was also assessed by determining the frequency and proportion of male and female patients. The study comprised a total of 130 individuals who met the inclusion criteria, with 88 (67.7%) being male and 42 (32.3%) being female. The aim of this study is to assess the surgical outcomes of palatal fractures treated with locking plates as external fixators compared to alveolar plating, specifically focusing on the incidence of oronasal fistula development. The occurrence of oronasal fistula development in both groups was 01 (1.5%) and 07 (10.8%) respectively, demonstrating a statistically significant difference (p -value 0.029). The study aimed to assess the impact of age stratification as an effect modifier on the surgical outcomes of palatal fractures treated with locking plates as external fixators vs alveolar plating, specifically in terms of the

incidence of oronasal fistula development. In the age category of 41–55 years, there were 01 (2.3%) and 05 (11.9%) percentages of patients seen in both groups. The study aimed to examine the association between the effect modifier of gender stratification and the surgical outcome of palatal fractures treated with locking plates as external fixators vs alveolar plating, specifically in terms of the frequency of oronasal fistula development. Table-3 displays the distribution of female patients in both groups, with percentages of 4.8% (01) and 14.3% (03) respectively.

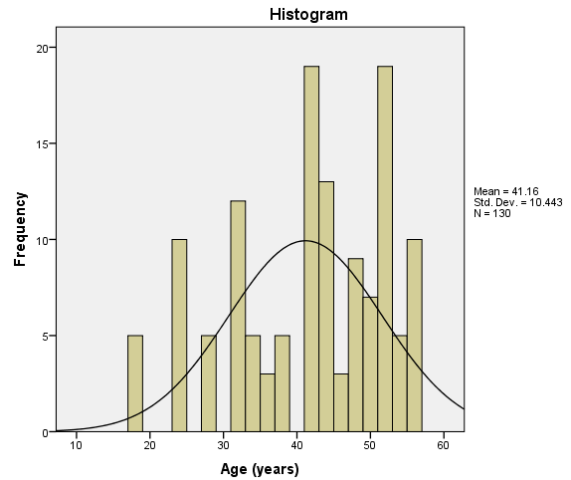


Figure-1: Histogram showing descriptive statistics of Age (years)

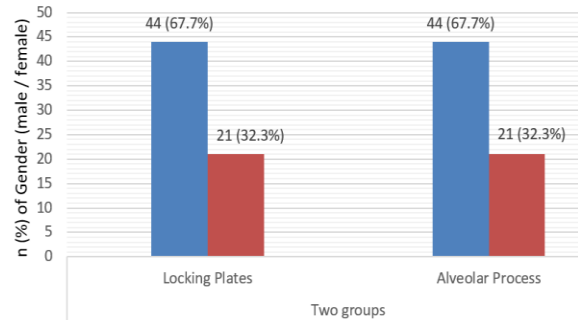


Figure-2: Bar chart showing gender distribution

Table-1: Descriptive statistics of Age of patients

	Mean	Std. Deviation
Age (years)	41.16	10.44
Group A	41.09	10.077
Group B	41.23	10.18

Table-2: Duration of Trauma among both the groups

	Two groups	n	Mean	SD
Duration of trauma	Locking plates	65	2.88	1.09
	Alveolar process	65	3.05	1.23

Table-3: Effect modifier like Age and Gender group stratification with Oronasal Fistula among both the groups

	Oronasal Fistula	Two groups		Total	p-value
		Locking plates	Alveolar process		
18 - 40 years	Present	0	2	2	0.157
		0.0%	8.7%	4.4%	
	Absent	22	21	43	
		100.0%	91.3%	95.6%	
41 - 55 years	Present	1	5	6	0.085
		2.3%	11.9%	7.1%	
	Absent	42	37	79	
		97.7%	88.1%	92.9%	
Male	Present	0	4	4	0.041
		0.0%	9.1%	4.5%	
	Absent	44	40	84	
		100.0%	90.9%	95.5%	
Female	Present	1	3	4	0.293
		4.8%	14.3%	9.5%	
	Absent	20	18	38	
		95.2%	85.7%	90.5%	

DISCUSSION

Palatal fractures, particularly closed fractures that do not include damage to the mucosa, can often go unnoticed. Palatal fractures frequently exhibit an association with midface or panfacial fractures. Therefore, it is imperative to conduct a comprehensive physical examination and employ a technically proficient CT scan with thin sections in order to actively pursue their identification. There is a lack of consensus on the optimal indications for osteosynthesis in the palatal vault, which conventionally involves the use of subperiosteal plates and screws. The use of this particular approach has the potential hazard of bone segment necrosis, prompting several writers to establish a defined "safe region" for palatal incisions.³

The potential occurrence of dentoalveolar necrosis may also serve as a deterrent for utilising the transverse vestibular technique in instances with maxillary buttress fractures. The use of a vertical vestibular incision along the medial and lateral maxillary buttresses has been suggested in some circumstances.³ Additionally, there exists the potential for the exposure of osteosynthesis material over an extended period of time. Due to the aforementioned rationales, several writers continue to advocate for the use of palatal splints, arch bars, or maxillomandibular fixation as viable approaches for the management of palatal fractures.³ In recent decades, the approach to treating face fractures has focused on achieving anatomical alignment by durable osteosynthesis, hence eliminating the requirement for maxillomandibular fixation immediately after surgery. This practise facilitates early mobilisation and enhances functionality and aesthetic outcomes.

The utilisation of maxillomandibular fixation for the management of palatal fractures is incongruous with the contemporary rules governing the treatment of face fractures.³ The introduction of low-contact locking methods for osteosynthesis has effectively addressed

many technological challenges. The implementation of low contact techniques can effectively mitigate the risk of vascular injury to the cortical bone supporting the systems. On the other hand, the utilisation of locking plates ensures the maintenance of angular stability, hence preventing the failure of osteosynthesis caused by screw loosening owing to axial stresses exerted on non-locking fixation systems. In addition, it has been seen that the implementation of locking mechanisms leads to improved surgical outcomes, even in cases when the bone quality is suboptimal.³

Palatal fractures are infrequently encountered; however, they typically coexist with maxillary fractures. The prevalence of palatal fractures in conjunction with maxillary fractures typically falls within the range of 8% to 20%. However, there has been a notable increase in reported cases, with a recent incidence rate of 46.4%.²

Historically, the process of achieving anatomical alignment in palatal fractures has been regarded as challenging. Despite the existence of a wide range of techniques, including invasive methods like open reduction and internal fixation (ORIF)² and Kirschner wire fixation, as well as non-invasive approaches such as maxillary arch stabilisation using an arch bar, trans-palatal wiring, intraosseous wiring, acrylic splints, and intermolar wiring, each of these methods presents inherent challenges and limitations. The procedure known as open reduction and internal fixation (ORIF) necessitates the careful elevation of a broad mucoperiosteal flap. However, this task is challenging in the palate due to the firmly adhering nature of the mucoperiosteum. This difficulty increases the risk of soft tissue injury, potentially compromising the blood supply to some extent. Additionally, it may lead to the disclosure of hardware components and a delay in the occurrence of nasal haemorrhage.²

Additionally, the absence of maxillomandibular fixation poses an intrinsic danger of occlusal disturbance. Hence, it becomes prudent to explore alternate

approaches to the time-consuming process of open reduction and internal fixation (ORIF), which is often accompanied by several complexities. Both intraosseous and trans-palatal wiring procedures have certain drawbacks, but to different extents.

The utilisation of the arch bar and splint techniques is intended to achieve stabilisation of the maxilla. However, these methods mostly serve a passive function in terms of bringing the fractured components into alignment and are not helpful in reducing the separation between the two pieces. This is due to the fact that compression is necessary to facilitate proper bone union. The use of intermolar wiring in a trans-palatal direction, being a relatively young technology, is not exempt from encountering some challenges. Due to its extended duration of retention, the substance in question has the potential to induce irritation of the tongue, impede oral hygiene practises, and disrupt speech patterns.² The research done by Wang *et al.*⁵ reported a mean age of 56 years with a standard deviation of 18.4. In our study, the average age of participants was 41.16 years with a standard deviation of 10.44. In the present study, a total of 88 (67.7%) male and 42 (32.3%) female patients were enrolled for analysis. Similarly, research done in 2016 revealed that the frequency and proportion of male and female patients were 14 (77.7%) and 4 (22.2%), respectively.

The aim of this study is to assess the surgical outcomes of palatal fractures using locking plates as an external fixator compared to alveolar plating, specifically in relation to the occurrence rate of oronasal fistula development. The incidence of oronasal fistula development was found to be 1.5% in one group and 10.8% in the other group. In research conducted by Rimell *et al.*⁷, it was shown that there was a 9% incidence of plate exposure and a 9% occurrence of oronasal fistula that necessitated bone graft intervention.

CONCLUSION

The study concluded that frequency of oronasal fistula in Osteosynthesis with 2.0 mm locking plates as external fixator have difference as compared to the patients who underwent with alveolar plating. Future studies at multiple setups must be conducted in order to know which procedure is superior to another or not. So that a uniform approach will be use a standard protocol which will give good postoperative results in terms of infection, fistula formation and necrosis.

AUTHORS' CONTRIBUTION

AUS: Literature search, data collection, write-up. UF: Conceptualization of the study design, write-up. FA: Data analysis. HH: Data collection. AMS: Data interpretation. AJ: Proofreading.

REFERENCES

1. Pollock RA. The search for the ideal fixation of the palatal fractures: innovative experience with a mini locking plate. *Craniomaxillofac Trauma Reconstr* 2008;1(1):15–24.
2. Kumaravelu C, Thirukonda GJ, Kannabiran P. A novel adjuvant to treat palatal fractures. *J Oral Maxillofac Surg* 2011;69(6):152–4.
3. Cienfuegos R, Sierra E, Ortiz B, Fernandez G. Treatment of palatal fractures by Osteosynthesis with 2.0-mm locking plates as external fixator. *Craniomaxillofac Trauma Reconstr* 2010;3(4):223–30.
4. Mehboob B, Khan M, Qiam F. Pattern and management of palatal bone fracture. *Pak Oral Dent J* 2014;34(1):21–4.
5. Wang Z, He Y, Liu Y, Huang D, Gu L, Wang D, *et al.* Treatment of sagittal maxillary fracture by an innovative method of reversing pre-activated maxillary expanders. *Int J Clin Exp Med* 2016;9(3):6279–86.
6. Ma D, Guo Y, Yao H, Chen J. Transpalatal screw traction: a simple technique for the management of sagittal fracture of maxilla and palate. *Int J Oral Maxillofac Surg* 2014;43(12):1465–7.
7. Moss WJ, Kedarisetty S, Jafari A, Schaerer DE, Husseman JW. A review of hard palate fracture repair technique. *J Oral Maxillofac Surg* 2015;74(2):328–36.
8. Rai A. 3 Dimensional plate in management of sagittal palatal fractures: A novel technique. *J Maxillofac oral surg* 2016;16(4):497–9.

Submitted: August 17, 2023

Revised: May 16, 2024

Accepted: May 16, 2024

Address for Correspondence:

Dr. Ain us Saba, Oral and Maxillofacial Surgery, Islamabad Medical and Dental College, Islamabad -Pakistan

Cell: +92 331 513 2102

Email: annie.amc1@gmail.com