

ORIGINAL ARTICLE

CORRELATION OF SONOGRAPHIC OPTIC NERVE SHEATH DIAMETER WITH OPENING PRESSURE ON LUMBAR PUNCTURE IN PATIENTS OF IDIOPATHIC INTRACRANIAL HYPERTENSION

Sajjad Ahmad¹, Noor ul Hussain², Mian Iftikhar ul Haq³, Haider Ali Khattak⁴, Asghar Ali⁵

¹Gajju Khan Medical College, Swabi, ²Frontier Institute of Ophthalmology, Peshawar, ³MTI-Hayatnabad Medical Complex, Peshawar-Pakistan,

⁴Department of Neurosurgery, Ayub Medical College, Abbottabad-Pakistan, ⁵Mardan Medical Complex, Mardan-Pakistan

Background: Evaluation of opening pressure (OP) of CSF on lumbar puncture (LP) is an invasive procedure for the confirmation of diagnosis of idiopathic intracranial hypertension (IIH). Sonographic optic nerve sheath diameter (ONSD) measurement is a non-invasive method which can help in the estimation of intracranial pressure (ICP). The study was carried out to find out the correlation between ONSD and OP on LP in patients of IIH. **Methods:** The Cross-sectional study was hosted by medical teaching institute, Gajju Medical College, Swabi and Frontier institute of Ophthalmology, Peshawar, from 1st June, 2021 to 31st May, 2023. Total participants were 50, 25 in Group A having diagnosis of IIH and 25 in Group B as control group from general population. The patients in Group A had ONSD assessment followed by measurement of OP and then the process was repeated at two weeks follow up. Participants in Group B had only one assessment of ONSD. Correlation between ONSD and OP was determined. Best cut-off-value for raised ICP was calculated. **Results:** The mean ONSD was 5.91 ± 0.63 in Group A and 5.07 ± 0.50 in Group B ($p=0.00$). The mean OP in Group A was 31.64 ± 3.81 cm H₂O initially. The mean ONSD and OP at follow up were 5.18 ± 0.42 and 19.64 ± 3.52 cm H₂O respectively. The best cut-off-value was 5.60 mm of ONSD for estimation of raised ICP (sensitivity 88% and specificity 88%). **Conclusion:** Sonographic ONSD has a positive correlation with OP on LP in IIH patients and can be used as a non-invasive tool for the assessment of ICP in IIH patients.

Keywords: Optic nerve sheath diameter (ONSD); Idiopathic intracranial hypertension (IIH); Opening pressure (OP); lumbar puncture (LP)

Citation: Ahmad S, Hussain NU, Haq MIU, Khattak HA, Ali A. Correlation of sonographic optic nerve sheath diameter with opening pressure on lumbar puncture in patients of idiopathic intracranial hypertension. J Ayub Med Coll Abbottabad 2024;36(3):497–500.

DOI: 10.55519/JAMC-03-12890

INTRODUCTION

Idiopathic intracranial hypertension is a disease which mostly affects obese female patients who are of reproductive age and is characterized by headache and visual problems. Symptoms of diplopia and tinnitus may invariably be present.^{1–3} Incidence rates for obese women of reproductive age in the USA are 15–19 instances per 100,000, and 0.3 to 7.8 per 100,000 people per year in general population and is likely to increase due to overall increase in obesity around the world.^{4,5}

The diagnosis is made with modified dandy criteria and requires multidisciplinary approach. Various diagnostic modalities like CT scan, MRI and OCT (optical coherence tomography) are utilized for diagnosis.⁶ A consistent aspect of the updated Dandy criteria is to perform lumbar puncture in patients suspected of IIH to measure the opening pressure and perform CSF examination to rule out other differential diagnosis and opening pressure greater than 25cm is considered as diagnostic.^{7,8}

As lumbar puncture can have associated complications like traumatic tap, cerebral herniation and post-dural puncture headache; hence, exploring non-invasive tests like MRI, CT, and OCT for the confirmation of IIH has long been a goal. etc.^{2,4,9,10}

One of the non-invasive diagnostic techniques used to measure ICP is sonographic ONSD.^{11,12} The link between ONSD and OP on LP for the diagnosis of IIH has been demonstrated in a number of studies^{13,14}; however, various populations have varying cut-off points for ONSD as an indication of elevated ICP.¹⁵ This study was aimed to find out that whether ultrasonographic assessment of the ONSD can potentially serve as a non-invasive measure for evaluation of ICP in patients of IIH. Secondly, we were able to determine the ONSD cut-off value for the identification of elevated ICP in Pakistani population.

MATERIAL AND METHODS

This cross-sectional study was carried out at the Medical Teaching Institute, Gajju Khan Medical College Swabi, Division of Neurosurgery, and Frontier Institute of

Ophthalmology, Peshawar in two years, i.e., from 1st June, 2021 to 31st May, 2023. The hospital's ethics and research council granted ethical permission, and each study participant provided informed consent. The total number of patients was 50 which included 25 patients having benign intracranial hypertension, labelled as Group "A" and 25 matched control participants were selected from the general population, which were labelled as Group "B". All the patients were females, in order to avoid gender bias and recruited via OPD through consecutive non-probability sampling technique. Patients aged 25–35 were included and those having raised intracranial pressure secondary to other causes like tumors or trauma etc., Exclusions from the research were cases of optic neuritis, ischemic optic neuropathy, unilateral or pseudo-papilledema, and a history of surgical or medicinal intervention for IIH. The patients in Group "A", having diagnosis of IIH (diagnosed via updated Dandy criteria), were initially assessed for ONSD in both the eyes with help of an ultrasound at presentation before undergoing any intervention. The ONSD were measured 3cm behind the retina, through ultrasound probe placed at superolateral border of the orbit. For both eyes, the average ONSD was computed and recorded. Subsequently, the patients underwent evaluation of the opening pressure of CSF through lumbar puncture and 20–30 cc CSF was drained. The patients were discharged on acetazolamide tablets and asked for follow up after 2 weeks. At two weeks follow up, the protocol of measurement of ONSD followed by opening pressure on lumbar puncture was repeated and recorded. The participants in the volunteered control matched Group "B" had only one assessment of ONSD in both the eyes without any lumbar puncture. The data was collected through a pre-formed questionnaire. Data analysis including multivariate analysis, correlation analysis, ROC curve, and cut-off-point estimation was done with SPSS version 26.

RESULTS

The total no. of patient was 50, 25 in Group "A" was a diagnosis of benign intracranial hypertension and 25 participants in Group "B" from general population was a control group. All the patients were females. Comparison of age and BMI was as shown in table 1.

The ONSD readings at initial presentation were as shown in table 2. The mean opening pressure (OP) on lumbar puncture in Group "A" was 31.64 ± 3.81 cm H₂O (range 25-39) on initial assessment. The ONSD reading at follow up after two weeks were as shown in Table 3. The mean OP on LP at 2 weeks follow up was 19.64 ± 3.52 cm H₂O (range 14-28) which differed significantly from the 1st assessment (p -value = 0.00). The correlation analysis of ONSD and CSF opening pressure on initial assessment and at follow-up revealed a moderate level of

correlation which was statistically significant as shown in Table 04 and Figure 1 and 2

The optimal cut-off-point for diagnosing IIH, according to the ROC curve analysis, was 5.60, with 88% sensitivity, and 88% specificity. The area under the curve was 0.86 (95% confidence interval, 0.75–0.98). At 4.09, the sensitivity was 100%, and at 6.02, the specificity was 100%. Presented below in Figure 3 is the ROC curve.

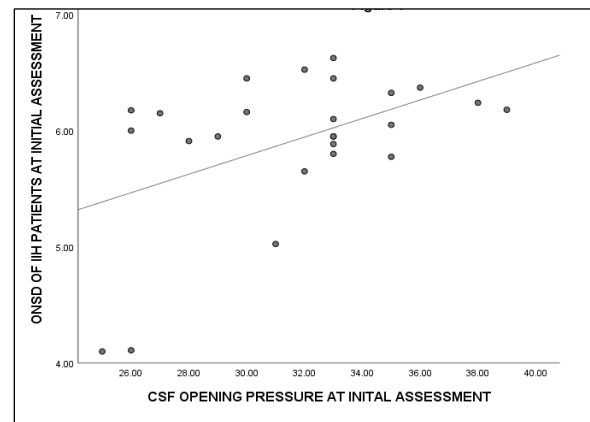


Figure-1: Correlation of ONSD and CSF opening pressure at initial assessment

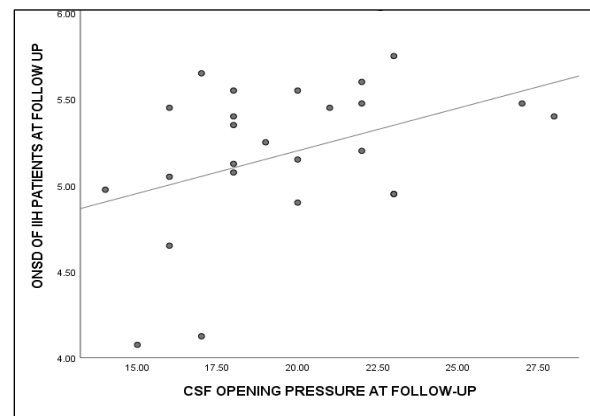


Figure-2: Correlation of ONSD and CSF opening pressure at follow-up

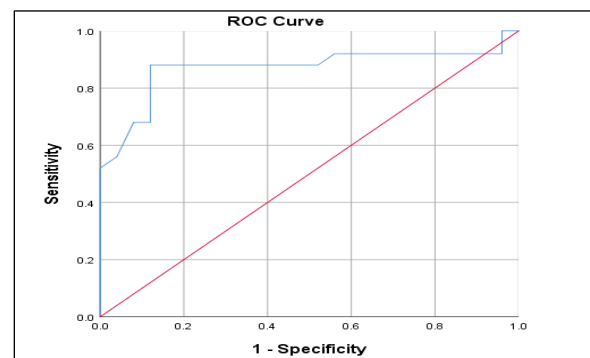


Figure-3: ROC curve analysis

Table-1: Age and BMI of the Patients

Group	Age	P-value	BMI	P-value
A	29.84±3.06	0.33	26.00±2.70	0.38
B	28.96±3.33		25.28±3.10	

Table-2: ONSD measurement at initial assessment

	Group A	Group B	P-value
ONSD in Right Eye	5.90±0.66	5.06±0.50	0.00
ONSD in Left Eye	5.92±0.62	5.09±0.52	0.00
ONSD in Both Eyes	5.91±0.63	5.07±0.50	0.00

Table-3: ONSD measurement at follow-up

	Group A	Group B	P-value
ONSD in Right Eye	5.19±0.43	5.06±0.50	0.35
ONSD in Left Eye	5.18±0.42	5.09±0.52	0.53
ONSD in Both Eyes	5.18±0.42	5.07±0.50	0.43

Table-4: CSF opening pressure measurements at initial assessment and follow-up

CSF opening pressure	Average ONSD	r	p-value
OP at initial assessment	ONSD at initial assessment	0.478	0.01
OP at follow-up	ONSD at follow-up	0.410	0.04

DISCUSSION

Idiopathic intracranial hypertension (IIH) requires measurement of opening pressure on lumbar puncture (LP) for the confirmation of diagnosis; however, it can be associated with dangerous complications like post-dural tap headache, meningitis, spinal root irritation and coning etc.^{16,17} In order to avoid these complications, there has always been an urge for a non-invasive investigation which can act as an alternative to the LP for the detection of raised intracranial pressure.¹⁸

Sonographic ONSD assessment is a repeatable and reliable non-invasive investigation which has been reported to have a positive correlation with raised intracranial pressure.¹² The role of ONSD measurement in cases of IIH has also been evaluated and found effective.^{17,19} Studies reported different cut-off-values of ONSD for the identification of raised ICP, varying among different populations.²⁰⁻²³

In our analysis, we discovered that the ONSD values of IIH patients and the general population differed significantly (5.91±0.63 versus 5.07±0.50) and there was moderate, statistically significant, positive correlation with opening pressure of CSF on LP both at initial presentation as well as at follow-up visit ($r = 0.478$, p -value = 0.01, $r = 0.410$, p -value = 0.04) respectively. For our Pakistani population, the optimal cut-off value was calculated to be 5.60 (specificity = 88%, sensitivity = 88%).

As IIH commonly affects female patients of childbearing age, we only included female patients in our study to accurately estimate the best cut-off-point and reduce the gender bias. The range of age was also kept very narrow in both groups, in order to reduce the chances of introducing any bias due to age factor (29.84±3.06 versus 28.96±3.33, p value = 0.33, respectively). The BMI did not vary significantly between two groups (26.00±2.70 versus

25.28±3.10, p value = 0.38), in contrast to the findings of kishk *et al*¹⁷ stating that IIH patients have higher BMI (32.93±7.22 versus 27.49±7.61, p -value = 0.005). The mean opening CSF pressure was 31.64±3.81 cm H₂O initially which reduced to 19.64±3.52 cm H₂O on follow up visit after undergoing CSF drainage and usage of oral medications.

Bozdoğan *et al*¹⁴ reported comparable OP of CSF at LP (33.9±8.0 cm H₂O); however, Mean ONSD in IIH patients at initial assessment was 7.1±1.0 mm and 6.9±0.7 mm in the right and left eye respectively, whereas, the readings were 5.4±0.7 and 5.5±0.6 mm in the right and left eye respectively in the control group. They found that ONSD has a positive correlation with OP of CSF. In contrast to our findings, Schott *et al*¹⁶ looked for the immediate changes in ONSD after undergoing LP and found no real difference. These findings suggest that changes in ONSD after LP are not immediate and might take couple of weeks to manifest.

Dağdelen *et al*¹² also discovered that the mean ONSD had a positive connection with CSF pressure (r : 0.740 and $p < 0.001$) and was thicker in the IIH group when compared to the control group (6.4 vs 4.90 mm, $p = 0.001$). Rehman *et al*¹⁹, Munawar *et al*²² and Kimberly *et al*²³ also reported positive correlation of ONSD and intracranial pressure, though Roemer *et al*²⁴ reported no correlation. Although the mean ONSD can vary among different age groups,²⁰ the positive correlation with the intracranial pressure is very well established and hence, it can be utilized as a non-invasive method for assessing ICP, particularly in individuals with IIH.

The next question is that what should ideally be considered the best cut-off-point, as it varies among different populations. Wang *et al*¹⁵ declared 4.1mm of ONSD as a best cut-off-point in Chinese population. Kishk *et al*¹⁷ reported 6.05 mm as a best cut-off-point with a

73.2% sensitivity and 91.4% specificity. Munawar *et al*²² found 5.8 mm as cut-off-point with 94% sensitivity and 96.08% specificity for Pakistani population which is very close to our value of 5.60. Similarly, Asghar *et al*²⁵ reported that the median ONSD was 4.84 mm and 4.86 mm in right and left eye respectively in Pakistani population which was comparable with our results of 5.06±0.50 and 5.09±0.52 in right and left eye respectively.

CONCLUSION

Our findings indicate that sonographic evaluation of the ONSD has a positive correlation with elevated ICP and can be used as a non-invasive method for assessing ICP in patients with IIH; however, regional variations in ethnicity validate the need for additional research.

AUTHORS' CONTRIBUTION

SA: Literature search, data collection, conceptualization of study design, write-up, proof reading. NUH: Data collection, interpretation and analysis. MIUH: Literature search, proof reading. HAK: Data collection, analysis. AA: Literature search.

REFERENCES

- Stevens SM, Rizk HG, Golnik K, Andaluz N, Samy RN, Meyer TA, *et al*. Idiopathic intracranial hypertension: contemporary review and implications for the otolaryngologist. *Laryngoscope* 2018;128(1):248–56.
- Toscano S, Lo Fermo S, Reggio E, Chisari CG, Patti F, Zappia M. An update on idiopathic intracranial hypertension in adults: a look at pathophysiology, diagnostic approach and management. *J Neurol* 2021;268(9):3249–68.
- Madriz Peralta G, Cestari DM. An update of idiopathic intracranial hypertension. *Curr Opin Ophthalmol* 2018;29(6):495–502.
- Kwee RM, Kwee TC. Systematic review and meta-analysis of MRI signs for diagnosis of idiopathic intracranial hypertension. *Eur J Radiol* 2019;116:106–15.
- Wang MT, Bhatti MT, Danesh-Meyer HV. Idiopathic intracranial hypertension: pathophysiology, diagnosis and management. *J Clin Neurosci* 2022;95:172–9.
- Moreno-Ajona D, McHugh JA, Hoffmann J. An update on imaging in idiopathic intracranial hypertension. *Front Neurol* 2020;11:453.
- Moss HE, Margolin EA, Lee AG, Van Stavern GP. Should lumbar puncture be required to diagnose every patient with idiopathic intracranial hypertension? *J Neuroophthalmol* 2021;41(3):379–84.
- Yiangou A, Mitchell J, Markey KA, Scotton W, Nightingale P, Botfield H, *et al*. Therapeutic lumbar puncture for headache in idiopathic intracranial hypertension: minimal gain, is it worth the pain? *Cephalalgia* 2019;39(2):245–53.
- Alsuwailm MH, Alkhatem AH, Alshabib AA, Aldraisi MH, Al Jughiman AK, Al-Turaifi MH, *et al*. Lumbar puncture: Indications, complications, technique and CSF analysis in pediatric patients. *Egypt J Hosp Med* 2018;70(4):638–43.
- Mollan SP, Hornby C, Mitchell J, Sinclair AJ. Evaluation and management of adult idiopathic intracranial hypertension. *Pract Neurol* 2018;18(6):485–8.
- Naldi A, Provero P, Vercelli A, Bergui M, Mazzeo AT, Cantello R, *et al*. Optic nerve sheath diameter asymmetry in healthy subjects and patients with intracranial hypertension. *Neurol Sci* 2020;41(2):329–33.
- Dağdelen K, Ekici M. Measuring optic nerve sheath diameter using ultrasonography in patients with idiopathic intracranial hypertension. *Arq Neuropsiquiatr* 2022;80(6):580–5.
- Hassen GW, Al-Juboori M, Koppel B, Akfirat G, Kalantari H. Real time optic nerve sheath diameter measurement during lumbar puncture. *Am J Emerg Med* 2018;36(4):e1–736.
- Bozdoğan Z, Şenel E, Özmuk Ö, Karataş H, Kurşun O. Comparison of Optic Nerve Sheath Diameters Measured by Optic Ultrasonography Before and After Lumbar Puncture in Idiopathic Intracranial Hypertension Patients. *Noro Psikiyatr Ars* 2023;60(2):117–23.
- Wang L, Feng L, Yao Y, Wang Y, Chen Y, Feng J, *et al*. Optimal optic nerve sheath diameter threshold for the identification of elevated opening pressure on lumbar puncture in a Chinese population. *PLoS One* 2015;10(2):e0117939.
- Schott CK, Hirzallah MI, Heyman R, Lesky DN, Brant EB, Callaway CW. Ultrasound measurement of optic nerve sheath diameter pre-and post-lumbar puncture. *Ultrasound J* 2020;12(1):1–8.
- Kishk NA, Ebraheim AM, Ashour AS, Badr NM, Eshra MA. Optic nerve sonographic examination to predict raised intracranial pressure in idiopathic intracranial hypertension: the cut-off points. *Neuroradiol J* 2018;31(5):490–5.
- Li J, Wan C. Non-invasive detection of intracranial pressure related to the optic nerve. *Quant Imaging Med Surg* 2021;11(6):2823–36.
- Rehman H, Khan MS, Nafees M, Rehman AU, Habib A. Optic nerve sheath diameter on sonography in idiopathic intracranial hypertension versus normal. *J Coll Physicians Surg Pak* 2016;26(9):758–60.
- Haq A, Abbas Q, Jurair H, Salam B, Sayani R. Ultrasonographic optic nerve sheath diameter measurement for raised intracranial pressure in a tertiary care centre of a developing country. *J Ayub Med Coll Abbottabad* 2018;30(4):495–500.
- Mehrpour M, Oliaee Torshizi F, Esmaeeli S, Taghipour S, Abdollahi S. Optic nerve sonography in the diagnostic evaluation of pseudopapilledema and raised intracranial pressure: a cross-sectional study. *Neurol Res Int* 2015;2015:146059.
- Munawar K, Khan MT, Hussain SW, Qadeer A, Shad ZS, Bano S, *et al*. Optic nerve sheath diameter correlation with elevated intracranial pressure determined via ultrasound. *Cureus* 2019;11(2):e4145.
- Kimberly HH, Shah S, Marill K, Noble V. Correlation of optic nerve sheath diameter with direct measurement of intracranial pressure. *Acad Emerg Med* 2008;15(2):201–4.
- Roemer SN, Friedrich EB, Kettner M, Rauzi M, Schub P, Kulikovski J, *et al*. Transorbital sonography and MRI reliability to assess optic nerve sheath diameter in idiopathic intracranial hypertension. *J Neuroimaging* 2023;33(3):375–80.
- Asghar A, Hashmi M, Hussain A. Optic nerve sheath diameter evaluated by transorbital sonography in healthy volunteers from Pakistan. *Anaesth Pain Intensive Care* 2019;27:282–6.

Submitted: January 26, 2024

Revised: March 6, 2024

Accepted: April 1, 2024

Address for Correspondence:

Dr. Asghar Ali, Department of Neurosurgery, Bacha Khan Medical College/Mardan Medical Complex, Mardan-Pakistan

Cell: +92 334 844 7475

Email: dr.asgharlillyn@gmail.com