

ORIGINAL ARTICLE

OUTCOME OF ENDOSCOPIC THIRD VENTRICULOSTOMY FOR OBSTRUCTIVE HYDROCEPHALUS IN PAEDIATRIC POPULATION

Asghar Ali¹, Ehtisham Ahmed Khan^{2✉}, Ahsan Aurangzeb², Abid Hussain³, Fatima Javed², Haider Ali Khattak², Amir Hamza Qazi¹¹Bacha Khan Medical College, Mardan Medical Complex, Mardan-Pakistan²Department of Neurosurgery, Ayub Medical College, Abbottabad-Pakistan³Bolan Medical College, Quetta-Pakistan

Background: Cervical disc herniation is one of the very few morbid and prevalent spinal conditions affecting quality of life (QOL), often leading to debilitating symptoms. Early recognition of signs and symptoms is crucial for timely intervention, as conservative methods may prove insufficient in cases with neurological deficits. Surgical interventions, including the anterior and posterior and hybrid approaches, have evolved to address the challenges posed by cervical disc herniation precisely cervical spondylosis. This study explores the effectiveness of laminoforaminotomy, a targeted surgical approach for unilateral soft disc herniation. The technique aims to achieve optimal clinical outcomes by minimizing disruption to adjacent tissues and preserving motion segments. **Methods:** A retrospective study was conducted on 23 patients diagnosed with cervical radiculopathy who underwent posterior keyhole laminoforaminotomy between February and July 2023 at a Tertiary Care Hospital in Peshawar, Pakistan. Inclusion criteria encompassed individuals aged 30–70 years with persistent radicular pain, diagnosed with cervical disc herniation on MRI C spine or cervical spondylotic radiculopathy clinically. **Results:** The age distribution of the participants ranged from 32 to 67 years, with the largest group in the 41–50 age range. Males constituted 69.56% of the patients. The distribution of cervical disc herniations varied across levels, with the C4–C5 level exhibiting the highest occurrence. Postoperative complications were observed in 3 out of 23 patients, resulting in an 82.62% success rate. **Conclusion:** In summary, laminoforaminotomy demonstrates promising short-term results in addressing unilateral soft disc herniation, with an 82.62% success rate portraying the need for further exploration in prospective studies for long-term efficacy. Outcome of endoscopic third ventriculostomy for obstructive hydrocephalus in pediatric population.

Keywords: Cervical disc herniation; Spinal condition; QOL; Neurological deficits

Citation: Ali A, Khan EA, Aurangzeb A, Hussain A, Javed F, Ali H, *et al.* Outcome of endoscopic third ventriculostomy for obstructive hydrocephalus in paediatric population. J Ayub Med Coll Abbottabad 2025;37(2):

DOI: 10.55519/JAMC-01-14549

INTRODUCTION

According to Monro-Kellie Doctrine the total volume of the brain, CSF and blood within the skull is constant. An increase in one compartment must accompany a decrease in volume in another compartment, otherwise the pressure within the vault will increase as it happens in hydrocephalus with catastrophic sequels if paid no attention to timely.¹ As established, CSF is chiefly produced by the choroid plexuses in lateral, third and 4th ventricles. It travels through the ventricular system from lateral ventricles to the 3rd ventricle via the foramen of Monro, from 3rd to 4th ventricle via the cerebral aqueduct, it then leaves the 4th ventricle through basal foramina of Luschka and Magendie to enter the basal cisterns and part of it continues to flow around the spinal cord in the spinal canal. The main sites of CSF absorption are arachnoid granulations that project into the dural venous sinuses especially superior sagittal sinuses, from where it is absorbed into the venous sinuses and enters the systemic circulation.^{2,3} Bulk flow model of CSF hydrodynamic

states that CSF flows slowly away, from its sites of production to its sites of absorption.⁴ Any physical or functional obstruction within the ventricular system, subarachnoid space or venous sinuses can cause obstructive pattern of hydrocephalus as established by Dandy.⁵ According to hydrocephalus epidemiology meta-analysis, the mean hydrocephalus estimate is approximately 0.8/1000. The prevalence is 0.9/1000 in paediatric population. Incidence of hydrocephalus diagnosed at birth is 81/100000. The most common cause for congenital hydrocephalus is myelomeningocele and later on, in infancy other cerebral malformation like Dandy-Walker syndrome or aqueductal stenosis. Lower incidence was identified in high-income countries.⁶ Regarding the pathophysiological mechanisms two patterns of hydrocephalus were identified obstructive and communicating forms.⁷ The obstructive hydrocephalus as the name implies, is defined as obstruction in the CSF flow pathway. In the acute form of obstructive hydrocephalus, especially in young patients, only minor

ventriculomegaly may be present, in spite of a significant rise in intracranial pressure. With long standing CSF pressure on the brain parenchyma, the ventricular system dilates, compressing and thinning the overlying cortex with morbid sequels, hence necessitating the need for an early and effective surgical intervention. VP shunting as primary choice of surgical treatment have been proposed and accepted long by the literature recent buzz however have been about the need to identify and explore less invasive and more cost-effective physiological solutions.⁸ Endoscopic third ventriculostomy as first line treatment for hydrocephalus is deemed a suitable alternative to extra cranial shunting, dictating a shunt free life for children offering a more physiological solution to the pathology. It consists of fenestrating the floor of the third ventricle and thus establishing free flow of the cerebrospinal fluid from the ventricles to the site of resorption in subarachnoid space. ETV has also been proven useful in other forms of hydrocephalus by the literature. ETV effectively controls obstructive hydrocephalus in more than 75% of all the patients and 57.1% in patients with obstructive hydrocephalus, the overall success rate of the procedure however varies.⁹

This study aims to explore the outcome of endoscopic third ventriculostomy for obstructive hydrocephalus in paediatric population in the age range of 4 months to 2 years

MATERIAL AND METHODS

This retrospective study was conducted on perioperative data of patients diagnosed with obstructive hydrocephalus who underwent endoscopic third ventriculostomy between November 2023 to April 2025 at Mardan Medical Complex Pakistan. The study focused on the perioperative outcome of ETV in pediatric population aged 4 months to 2 years in terms of its outcome success rate and risk of complications.

A total of 25 patients were included in the study, with a primary diagnosis of obstructive hydrocephalus on Clinical examination, CT and MRI Brain with contrast and FLAIR IMAGES aged 4M to 2Y. The patients had undergone ETV and their postoperative data were retrospectively reviewed. The study included individuals aged between 4 months to 2-years diagnosed as obstructive hydrocephalus on CT and MR Brain who had undergone ETV primarily as first line of treatment. Inclusion was limited with cause of obstruction being, aqueductal Stenosis, brain stem and posterior fossa space occupying lesions ACM and its variants seller masses and Dandy Walker malformation. With adequate pre-pontine space on CT and MRI. Exclusion criteria included previously VP shunted, Infected CSF Routine examination with positive cultures, communicating form of hydrocephalus, inadequate pre-pontine Space on MRI brain, and those with multiple co-morbid unfit to undergo anaesthesia and surgery. Patients were put in

supine position with Kocher's point as the chosen working corridor, 30-degree telescope was inserted into the lateral ventricle advanced down to third ventricle after having had identified choroid plexuses, anterior septal, thalamostriate veins and fornix. In the floor of the third ventricle mammillary body, infundibular recess and pre-mammillary membranes were identified (with continuous N saline irrigation. Floor of the third ventricle was then perforated, followed up by stoma expansion using fogarty catheter size 3 or 4.

Post operatively patients were kept in Neuro ICU were given anti-inflammatory, antibiotics and anti-epileptics for 2 weeks. The hospital stay duration was kept upto a week depending on the etiological cause of obstructive hydrocephalus with follow up in 2 weeks with repeat CT and MRI Brain to look for ventriculomegaly, temporal horns and third ventricular size and periventricular seepage on T2 and Flair MR images. Statistical analysis was performed using the statistical package for the social sciences (SPSS) software version 27. Descriptive statistics were employed for data assessment.

RESULTS

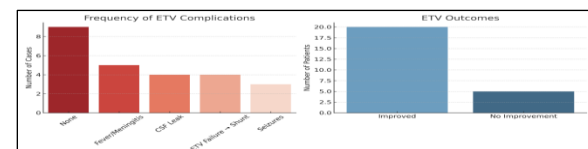
In our research 25 patients were studied retrospectively. Throughout the research study, age of the participants ranged from 4M to 2y. The 4M to 1y age range constituted around 52% % of the total population while rest of the 48% were comprised of those over 1 and under 2Y. The distribution provided an insight into the age group. In this study males enrolled were 17 which accounts for 68% of the total patients while female patients enrolled were 8 who contributed to rest of the 32% of the study population. Male distribution was slightly higher to the female population. The success rate of ETV throughout the study was found to be 36% on follow up. 20% of the patient developed post-operative Fever/meningitis, 16% had CSF leaks, rest of the 16% had ETV failure that ended up on VP Shunting while 12% experienced seizures post operatively.

Table-1: Age distribution of patients

| S.No | Age Groups | Numbers | Percentages |
|------|------------|---------|-------------|
| 1 | 4M-1Y | 13 | 52% |
| 2 | 1-2Y | 12 | 48% |

Table-2:

| S.No | Gender | Number | Percentage |
|------|---------|--------|------------|
| 1 | Males | 17 | 68% |
| 2 | Females | 8 | 32% |



DISCUSSIONS

Endoscopic third ventriculostomy is considered to be a treatment of choice for obstructive hydrocephalus, indicated in hydrocephalus due to aqueductal stenosis, third ventricle tumors especially in posterior part, vein of galen malformation, posterior fossa tumors, normal pressure hydrocephalus and craniosynostosis.^{10,11} The demographic distribution of patients in this study offers an insight into the understanding of the overall outcome of endoscopic third ventriculostomy in terms of its success, failure, and perioperative complications. The fact that patients under 1y constituted 52% of the enrolled population and male gender contributing to 68% of it has epidemiological significance in a sense that age and gender might just very well be the underdog factors that needs be taken into serious accounts when considering patients for successful ETV. 20% of the patients enrolled developed post-operative Fever/Meningitis which was the most commonly reported complication unlike most studies that reported Intra and post-operative haemorrhage instead as the most common complication followed up by CSF leaks underscoring the importance of intra and post-operative vigilance and care. In our study 16% of patients had CSF leaks while rest of the 16 % on follow up ended up at VP Shunting due to failed ETV. 12% of the patients had post-operative seizures which were managed conservatively with antiepileptics. Overall success rate of primary ETV in this study was reported to be 36% which is way below success rate reported by most studies, i.e., 74.7%. patients fail to show any improvement despite patent stoma after ETV, this may be due to complex hydrocephalus that is because of existing of both obstructive and communicating.¹² Despite the valuable insights of epidemiological factors and perioperative complications that this study provides an insight into, it is essential to acknowledge the limitation of this study. The study population and age enrolled were very limited, the study besides was conducted retrospectively that may have impacted the outcome. Hence future research with larger cohorts and extended follow up duration is warranted to validate and build upon the current results. This study not only contributes to the existing body of knowledge on ETV but also stimulates further enquiry into demographics, anatomical, radiological and procedural nuances.

CONCLUSION

In summary our study reveals the efficacy of ETV in paediatric population with obstructive hydrocephalus wavering a 36% overall success rate. Despite its success for the most part, post-operative complications, notably meningitis, fever and CSF Leaks predominates underscoring the importance of perioperative care. The

minimally invasive approach with appropriately selected patient population offers a more physiological solution to extracranial shunting for what's been documented as the most common cranial paediatric pathology of the CSF hydrodynamics. Our findings advocate for continued research to refine selection criteria, vigilance during perioperative care, and enhance patient's outcome.

REFERENCES

1. Benson JC, Madhavan AA, Cutsforth-Gregory JK, Johnson DR, Carr CM. The Monro-Kellie Doctrine: A Review and Call for Revision. *AJNR Am J Neuroradiol.* 2023 Jan;44(1):2-6. doi: 10.3174/ajnr.A7721. Epub 2022 Dec 1. PMID: 36456084; PMCID: PMC9835920.
2. Damkier HH, Brown PD, Praetorius J. Cerebrospinal fluid secretion by the choroid plexus. *Physiol Rev.* 2013 Oct;93(4):1847-92. [PubMed] [Reference list]
3. Preuss M, Hoffmann KT, Reiss-Zimmermann M, Hirsch W, Merkschlager A, Meixensberger J, Dengl M. Updated physiology and pathophysiology of CSF circulation—the pulsatile vector theory. *Childs Nerv Syst.* 2013 Oct;29(10):1811-25. [PubMed] [Reference list]
4. Yamada, S., & Kelly, E. (2016). Cerebrospinal Fluid Dynamics and the Pathophysiology of Hydrocephalus: New Concepts. *Seminars in Ultrasound, CT and MRI*, 37(2), 84-91. <https://doi.org/10.1053/j.sult.2016.01.001>
5. Chen S, Luo J, Reis C, Manaenko A, Zhang J. Hydrocephalus after Subarachnoid Hemorrhage: Pathophysiology, Diagnosis, and Treatment. *Biomed Res Int.* 2017;2017:8584753. [
6. Dewan MC, Rattani A, Mekary R, Glantz LJ, Yunusa I, Baticulon RE, Fieggen G, Wellons JC, Park KB, Warf BC. Global hydrocephalus epidemiology and incidence: systematic review and meta-analysis. *J Neurosurg.* 2018 Apr 27;130(4):1065-1079. doi: 10.3171/2017.10.JNS17439. PMID: 29701543.
7. Koleva M, De Jesus O. Hydrocephalus. [Updated 2023 Aug 23]. In: StatPearls [Internet]. Treasure Island (FL): StatPearls Publishing; 2025 Jan-. Available from: <https://www.ncbi.nlm.nih.gov/books/NBK560875/>
8. Faquini IV, Fonseca RB, Correia AO, Cezar Junior AB, De Carvalho Junior EV, de Almeida NS, Azevedo-Filho HRC. Endoscopic third ventriculostomy in the treatment of hydrocephalus: A 20-year retrospective analysis of 209 consecutive cases. *Surg Neurol Int.* 2021 Aug 3;12:383. doi: 10.25259/SNI_458_2021. PMID: 34513150; PMCID: PMC8422502.
9. Sharafat S, Khan Z, Azam F, Ali M. Frequency of success and complications of primary endoscopic third ventriculostomy in infants with obstructive hydrocephalus. *Pak J Med Sci.* 2022 Jan-Feb;38(1):267-270. doi: 10.12669/pjms.38.1.4097. PMID: 35035437; PMCID: PMC8713220.
10. Gangemi M, Mascari C, Maiuri F, Godano U, Donati P, Longatti PL. Long-term outcome of Endoscopic third ventriculostomy in obstructive hydrocephalus. *Minimal Invasive Neurosurgery.* 2007 oct;50(05):265-9.
11. Sherrod BA, Iyer RR, Kestle JR. Endoscopic third ventriculostomy for pediatric tumor-associated hydrocephalus. *Neurosurgical Focus.* 2020 Jan;48(1)
12. Bouras T, Sgouros S. Complications of Endoscopic third ventriculostomy: a review. *Journal of Neurosurgery: Pediatrics.* 2011 Jun;7(6):643-9.

Submitted: August 27, 2024

Revised: December 3, 2024

Accepted: December 16, 2024

Address for Correspondence:

Dr. Ehtisham Ahmed Khan, Department of Neurosurgery, Ayub Medical College, Abbottabad-Pakistan

Email: ehtisham8100@gmail.com