

ORIGINAL ARTICLE

LEAD EROSION IN PERMANENT PACEMAKER: A CUMBERSOME COMPLICATION

Bakhtawar Shah, Zahid Aslam Awan, Tahmeedullah*, Zahoor Ahmed Khan

Department of Cardiology, *Plastic Surgery, Hayatabad Medical Complex, Peshawar, Pakistan

Background: Lead erosion is one of the troublesome complications which are very difficult to treat and most of the time leads to device explantation and replacement prematurely. **Methods:** From 2005 to 2011, total 415 pacemakers were implanted in our cardiology department at Hayatabad Medical Complex Peshawar. The patients were followed regularly at six month interval or more frequently in case there were complications. At every visit we inspected the wound site, electrocardiography was done and device was analyzed with compatible programmer for the device. If there was soreness at the site of implantation, patient was seen more frequently and if there was erosion of skin, wound was re-opened margin refreshed and wound closed. Initially we closed the wound in two layers after reopening but we got repeated erosion with this method and so we buried the leads sub-muscularly as change strategy which again proved unsuccessful. **Results:** During the six years study about 415 permanent pacemakers were implanted. During this time period, we received: three lead erosion, which were re-positioned. There were recurrence in two cases and they were again subjected to procedure with a change strategy; by burying the leads in muscles, which proved unsuccessful. **Conclusion:** Leads erosion can be prevented by carefully burying leads in three layers first in muscle followed by subcutaneous tissue and then closing the wound by suturing the skin during initial implantation.

Keywords: Permanent Pacemaker, lead erosion, implantable cardioverter-defibrillator, electrocardiography, atrio-ventricular node.

J Ayub Med Coll Abbottabad 2014;26(2):174-7

INTRODUCTION

Heart is the most restless organ of the body. It starts beating in the fifth week of the intrauterine life and continues to beat till the end of life. Heart, acts as a pump in the body and to pump blood, it needs to contract and relax in rhythm, for which it needs special conducting system.¹ The histological appearance of the specific tissue was most convincingly analysed by Blair and Davies in the bovine heart.² The conducting system starts at the sino-atrial (SA) node (the natural pacemaker), which is the powerhouse from where current generates and passes via special conducting fibres in the atria to the atrio-ventricular (AV) node. The conducting fibres in the right atrium are anterior, middle and posterior fibres. To the left atrium the current passes via the Bachmann's bundle. Still the existence of these atrial fibres is controversial. Another theory is that current passes directly through atrial muscles. At the junction of the atria and ventricle there is AV node which is designed to slow down the conduction so to buy time for the atria to contract. The current then passes through the His bundle, dividing into left and right bundle and terminate at Purkinje fibres.

Damage in the conducting system may be idiopathic or due to diseases may lead to partial or complete block to the flow of current and disturb rhythm of the heart leading to haemodynamic instability that needs assist devices for correction of

rhythm. These devices are pacemakers, which are implanted temporarily or permanently.

Paul Zoll 1952, a cardiologist at Harvard and Beth Israel Hospital developed the first external pacemaker.³ In 1958 permanent pacemaker (PPM) was implanted for the first time in human body⁴ and the first implantable cardioverter-defibrillator (ICD) was implanted in 1980.⁵

The first generations of devices were very large in size. In the ensuing years, as technologic developments have made these devices more compact and simplified their implantation and expanded the indications for their use.⁶ Mostly permanent pacemakers are implanted subcutaneously and the pacemakers' leads are passed through trans venous route preferably in the auxiliary vein. These leads are secured with non-absorbable suture with the muscles, and buried in three layers. The first two layers are with absorbable sutures and the skin may be stitched with absorbable or non-absorbable sutures using the sub-cuticular methods or external sutures by vertical or horizontal methods. Both ways of skin stitches are acceptable. But with extended use of pacemakers the rate of complication also increased.

Complication may be early or late. These complications are bleeding, artery puncture, injury to nerves and puncture to the myocardium, cardiac tamponade or damage to the valvular structures at the time of implantation or it may be infection, lead fracture, insulation break, dislodgment of the leads,

over sensing, under sensing, pacemakers induced tachycardia or lead erosion as late complications.

Leads erosion is exposures of leads from the skin. It may be due to various jackleg implantation techniques. These include necrosis of the skin over the leads, infection of the wound, exaggerated inflammation or dehiscence of the wound. Stitching the wound in three layers that is burying the leads in muscles, covering with subcutaneous tissue and properly aligning the skin will prevent lead erosion.

Leads erosion may occur after implantation as an early or late complication. The erosion-infection rate in some studies is 6.9 %.⁷ Lead erosion is a troublesome complication of permanent pacemakers. Most of the time; it is very difficult to treat. At time it leads to extraction of the device and re-implantation on another side. In this study we share our experience of dealing with this complication and how to possibly avoid this complication.

MATERIAL AND METHODS

This case series was conducted from 2004 to 2011. All patients who were implanted pacemakers were followed regularly at six monthly intervals, and more frequently in the case of complications. Any patient who presented with lead erosion was admitted to cardiology unit and all parameters of permanent pacemaker were checked on appropriate programmer. X-ray chest was performed for possible crushing of lead or insulation break. Swab for culture and sensitivity was sent to the Pathology department from the lead erosion site. Patient was started on intravenous antibiotics. All baseline investigations were done including full blood count, random blood sugar, HCV, HBS Ag and renal function test.

Next day patient was taken to operating room and wound was opened under aseptic techniques. As first line strategy lead was embedded properly in two layers, first layer was with absorbable suture 1/0 Vicryl. Skin edges were refreshed and wound was closed using non-absorbable 4/0 proline with horizontal techniques. Because of granulation tissue deep dissection was not done and at this stage and muscular embedding was not done. All these cases were discussed with plastic surgeon as well. As per their advice mere burying in two layers was deemed good enough to yield good results.

Skin sutures were removed after ten days. Patient received antibiotics till the sutures were removed. Wound site was declared satisfactory if there was no soreness and patient was sent home. Despite all these measure there was recurrence in 2 cases. One patient was lost to follow up. Again

patient was admitted to the unit and the baseline investigations were repeated. Patient was taken to operating room. This time careful blunt dissection was done and muscle bed was exposed. Muscle fibres were separated with blunt dissection and after fixing the lead slew with muscle by non-absorbable 4/0 proline sutures, lead was buried in muscle by absorbable 1/0 Vicryl sutures followed by subcutaneous tissue closing with the same absorbable 1/0 Vicryl sutures. Skin was stitched with non-absorbable 4/0 proline sutures, using vertical technique and sutures were left there for ten days. Skin stitches were removed after ten days and the patients were followed regularly.

RESULTS

Table-1 shows data regarding 415 patients that were followed with permanent pacemakers. From them 212 were with single chamber pace makers, and 203 with dual chamber pacemakers. Three patients presented with lead erosion. The mean time of lead erosion after implantation was 365±120 days. Careful analysis of all the patients with lead erosion revealed that basically there were faults in the lead embedding at the time of implantation. There was no report of infection in all those patients with erosion. In two cases it was the thin pocket flap because of the young age of the patient and less subcutaneous tissue leading to erosion of the lead. Again when re-implantation was done in redo cases of lead erosion the deep dissection was not done which caused erosion again. In another patient, we found that after putting the device in the pocket under the subcutaneous tissue, the mouth of the pocket was not closed properly, so the lead came to the incision line and eroded the skin. Figures 1–3 show different stages with lead position during reopening of a patient with lead erosion after one and a half year of the primary procedure. This wire came out of the pocket and was putting continuous tension on incision line which ultimately caused lead erosion. After change strategy when leads were buried in three layers two patients presented with erosion and infection of the wound site.

Table-1: Patients' demographic and clinical data

Total number of patients	415
Male	209
Female	206
Average Age	55 years
Dual chamber pace makers	203
Single chamber pace makers	212
Average time since implantation	16 months
Battery replacement	7
No of patients with lead erosion	3
Lead erosion after Battery replacement	0
No of patients with lead erosion & infection	0
Recurrence of erosion	2
Recurrence after change strategy	2
Lost to follow up	1

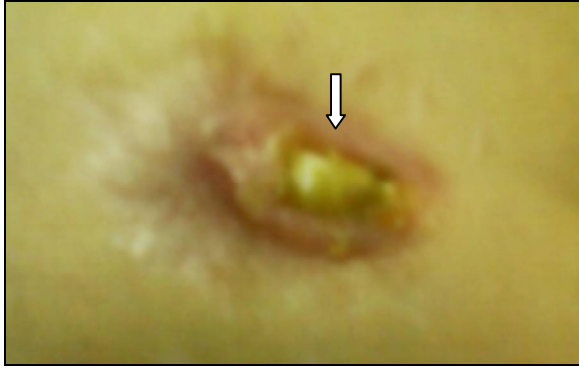

Figure-1: Lead erosion; lead sleeve is visible at the pacemaker implantation site (arrow)

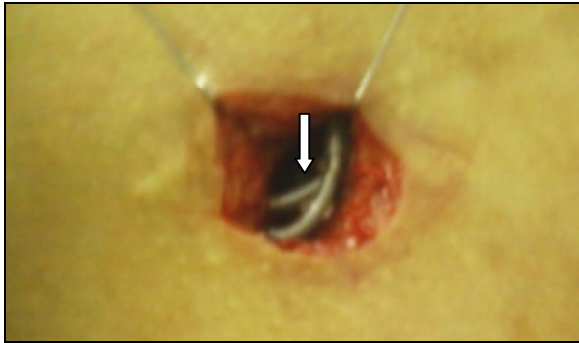


Figure-2: Leads exposed through skin incision. Leads are lying in the incision line; it was the possible cause of lead erosion

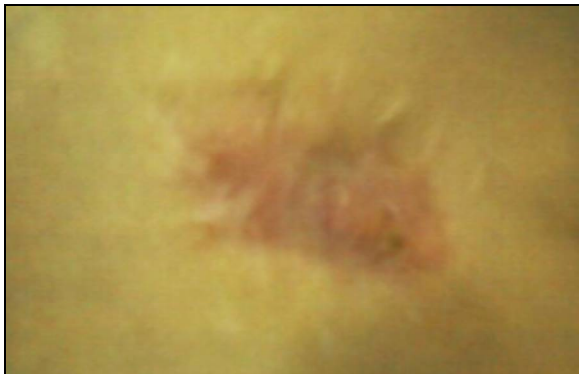

Figure-3: Wound at 3rd month after 2nd operation (ready to erode again)

DISCUSSION

Lead erosion is one of the difficult complications of permanent pacemakers. It reaches up to 6.9% in some studies.⁷ In our study the incidence is 0.72%. One of the causes of lead erosion is pocket infection. Pocket infection rate is about 7%⁸ in some studies, which leads to lead erosion. However lead erosion rate due to infection is significantly reduced with antibiotics during and after implantation of pacemakers⁹. There was no infection in primary implantation and with lead erosion in our study.

Lead erosion is more common after replacement of battery¹⁰ instead of primary implantation. Its rate is 4.5% as compared to primary implantation which is about 0.4% as studied in 2621 patients with pacemaker implantation or elective unit replacement (EUR) for end of battery life.¹¹ Because infection erosion rate is high in re-do procedures the high rate of erosion in the above mention study was infection/erosion. But in our re-do procedure, i.e., after battery replacement for device drain, no lead erosion was reported.

Beside infection the operator experience in implantation is of prime importance in preventing complication¹² and erosion. In our experience the operator experience in making skin incision, making pocket, putting device in the pocket and properly closing the mouth of the pocket is of great importance in preventing erosion. Horizontal incision is more prone to erosion as compared the one made at right angle to the delto-pectoral groove. Taking a thick flap in making the pocket will prevent erosion. Putting the leads properly below the device in the pocket will prevent their movement in the incision line and also it will be secure from damage in re-do procedures. After putting the device in pocket; now our routine strategy is to close the mouth of the pocket so to prevent the dragging of leads in the incision line while closing the muscular layer. If the patient is very young or elderly then the operator experience in making sub-muscular pocket is very important because a thin flap will render the device prone to erosion

The rate of complication is independent of the nature of the device; that is, single chamber verses dual chamber.^{13,14} However the large assembly of the dual chamber and double leads does matter. If the large size of the leads are not handled properly it will easily come into the incision line and can erode the skin.

Though lead erosion in our study is lower than the lead erosion as reported by Griffith *et al* for all cases of erosion (early and late) over a 10 year period,¹⁵ but still this low rate in our study is at variance with the experience of Hill, who reported no cases of erosion at all among 589 patients over 14 years¹⁶. Erosion in our study was due to mechanical factors and as such our patients remain infection free that's why we subjected our patients to re-implantation with the same device and leads. The success or failure of re-implantation depends upon the absence or presence of infection.¹⁶

Moreover the success rate of re-implantation again depends on the skill of the operator and the suture he selects. If the assembly is properly embedded in the muscles and covered in three layers; and the wires are kept away from the incision line the healing rate is great.^{17,18} Suture selection is also important. The one that is less irritant will yield good results like proline¹⁹ instead of silk. Both these sutures are non-absorbable

but silk cause more intense inflammation and so increase the rate of erosion. In all three cases we used silk during the primary implantation, as the non-absorbable suture, but during re-do procedure we used proline 3/0 or 4/0 as the non-absorbable material: the irritation of which is negligible to the body. But this time it was the infection which caused erosion. So in our study we conclude that the whole emphasis should be on primary implantation to prevent erosion.

CONCLUSION

Lead erosion is a troublesome problem in permanent pacemakers if it occurs. It is difficult to treat and miserable for patients. Prevention of the lead erosion at the very beginning by taking measure to do procedure in absolutely aseptic way, observing proper incision lines, making pockets with thick flaps, putting the wires behind the device, closing the pocket properly, and using proper sutures for stabilization of device will remain of utmost importance. Once occurs mere re-embedding is not enough because despite in the absence of documented infection in re-do procedures, it carries high rate of failure. Therefore, we suggest that once there is erosion of the lead or of the battery, the device needs ex-plantations and after proper sterilization implantation at different site or the same site after healing.

REFERENCES

1. Copenhaver WM, Truex RC. Histology of the atrial portion of the cardiac conduction system in man and other mammals. *Anat Rec* 1952;114:601–25.
2. Blair DM, Davies F. Observations on the conducting system of the heart. *J Anat* 1935;69:303–25.
3. Zoll PM. Resuscitation of the heart in ventricular standstill by external electrical stimulation. *N Engl J Med* 1952;247:768–71.
4. Elmqvist R. Review of early pacemaker development. *Pacing Clin Electrophysiol* 1978;1:535–6.
5. Mirowski M, Reid PR, Mower MM, Watkins L, Gott VL, Schauble JF, *et al.* Termination of malignant ventricular arrhythmias with an implanted automatic defibrillator in human beings. *N Engl J Med* 1980;303:322–4.
6. McPherson CA, Manthous C. Permanent Pacemakers and Implantable Defibrillators Considerations for Intensivists. *Am J Respir Crit Care Med* 2004;170:933–40.
7. Jesus I, Leiria G. The pocket infection-erosion of permanent pacemakers: the results of a conservative approach without substitution of the components. *Rev Port Cardiol* 1995;14:691–5.
8. Phibbs B, Marriott HJ. Complications of permanent transvenous pacing. *N Eng J Med* 1985;312:1428–32.
9. Bluhm G, Nordlander R, Ransjo U. Antibiotic prophylaxis in pacemaker surgery: a prospective double blind trial with systemic administration of antibiotic versus placebo at implantation of cardiac pacemakers. *Pacing Clin Electrophysiol* 1986;9:720–6.
10. Harcombe AA, Newell SA, Ludman PF, Wistow TE, Sharples LD, Schofield PM, *et al.* Late complications following permanent pacemaker implantation or elective unit replacement. *Heart* 1998;80:240–44.
11. Wohl B, Peters RW, Carliner N, Plotnick G, Fisher M. Late unheralded pacemaker pocket infection due to Staphylococcus epidermidis: a new clinical entity. *Pacing Clin Electrophysiol* 1982;5:190–5.
12. Chauhan A, Grace AA, Newell SA, Stone DL, Shapiro LM, Schofield PM, *et al.* Early complications after dual chamber versus single chamber pacemaker implantation. *Pacing Clin Electrophysiol* 1994;17:2012–5.
13. Aggarwal RK, Connelly DT, Ray SG, Ball J, Charles RG. Early complications of permanent pacemaker implantation: no difference between dual and single chamber systems. *Br Heart J* 1995;73:571–5.
14. Mueller X, Sadeghi H, Kappenberger L. Complications after single versus dual chamber pacemaker implantation. *Pacing Clin Electrophysiol* 1990;13:711–4.
15. Griffith MJ, Mounsey JP, Bexton RS, Holden MP. Mechanical, but not infective, pacemaker erosion may be successfully managed by re-implantation of pacemakers. *Br Heart J* 1994;71:202–5.
16. Hill PE. Complications of permanent transvenous cardiac pacing: a 14-year review of all transvenous pacemakers inserted at one community hospital. *Pacing Clin Electrophysiol* 1987;10:564–70.
17. Tiryakioglu O, Goncu T, Yumun G, Bozkurt O, Demir A, Tiryakioglu SK, *et al.* Unilayer Closure of Saphenous Vein Incision Lines is Better than Bilayer Closure. *Open Cardiovasc Med J* 2010;4:293–6.
18. Wilhelmi BJ, Blackwell SJ, Phillips LG. Langer's lines: to use or not to use. *Plast Reconstr Surg* 1999;104:208–14.
19. Kelly SE, Ehlers J, Llovera I, Troutman RC. Comparison of tissue reaction to nylon and prolene sutures in rabbit iris and cornea. *Ophthalmic surg* 1975;6(4):105–7.

Address for Correspondence:

Dr. Bakhtawar Shah, Department of Cardiology, Hayatabad Medical Complex, Peshawar, Pakistan

Email: drbakhtawarshah@hotmail.com