

ORIGINAL ARTICLE

ROLE OF CRANIAL COMPUTED TOMOGRAPHY IN PREDICTING CLINICAL OUTCOME IN PATIENTS WITH MINOR HEAD INJURY

Tayyaba Afzal, Faiza Akram*, Misbah Durrani

Department of Radiology, Combined Military Hospital, Muzaffarabad, *Ayub Medical College, Abbottabad, Pakistan

Background: Optimal management of patients with mild head injury in the emergency department is still under debate. The objective of this study was to determine the diagnostic efficacy of computed tomography in patients with minor head injury. **Methods:** A cross-sectional comparative study was conducted in the Radiology department of PIMS, Islamabad in collaboration with neurosurgery department from 14 February to 13 August 2008. One hundred and sixty patients coming to accident and emergency department with minor head injury with GCS of 13–15 were included. The patients then underwent non contrast enhanced CT of brain within 6 hours and results of computed tomography were compared with clinical outcome determined at 24 hours. **Results:** Twenty-two patients were CT positive for intracranial injury. Out of these 18 patients had an adverse clinical outcome and were considered true positive, while 4 patients were false positive and had normal clinical course with observation only. Ninety-four patients were CT negative for intracranial injury. Out of these 93 were true negative while 1 was false negative, as confirmed subsequently by adverse clinical outcome. The sensitivity, specificity, positive and negative predictive values and diagnostic efficacy of CT for intracranial injury in patients of minor head injury was 94%, 96%, 81%, 99% and 95.7% respectively. **Conclusion:** CT should be used as a primary screening investigation in all patients with minor head injury as patients with normal neurological examination and normal CT scan can be safely discharged without need for inpatient or patient observation, thereby making the hospital resources available for more serious patients.

Keywords: Intracranial injury, Computed tomography, Diagnostic efficacy, Minor head injury

J Ayub Med Coll Abbottabad 2013;25(1-2):187–90

INTRODUCTION

Head trauma is acknowledged as the leading cause of death and disability affecting the group of population in its most productive years of life.¹ The progression in Pakistan as in the rest of developing world towards urbanization and greater motorization is greatly increasing the burden of head injuries.² In developing countries accident rates in general and traumatic brain injury in particular are increasing as traffic increases besides other factors like industrialisation, falls and ballistic trauma.³ As many as two thirds of all motor vehicle accident victims sustain some head injury.⁴ The calculated annual rate of head injury patients in Pakistan is 81 per 100,000 with a mortality rate of 15 percent.¹

Minor head injury represents the most common type of head injury assessed in emergency departments, reaching nearly the 85% of cases.⁵ Minor head injury is commonly defined as blunt trauma to the head after which patient loses consciousness for <15 min or has a short post traumatic amnesia of <1 hr or both as well as a normal or minimally altered mental status on presentation (Glasgow Coma Scale (GCS) of 13–15).⁶

Optimal management of patients with mild head injury in the emergency department is still under debate.⁷ Intracranial complications of minor head injury are infrequent (6–21%) but potentially life threatening and may require neurosurgical intervention in a minority of cases. (0.4–1.0%).^{8,9} Neurocranial injury that does not require neurosurgical intervention may still cause

significant clinical problems; these patients will usually be kept under close clinical observation. Computed tomography (CT) of the head is the imaging modality of choice for diagnosing neurocranial traumatic lesions, such as skull fractures, epidural and subdural hematomas and hemorrhagic contusion.⁶ Observation in hospital is often standard practice and the addition of computed tomography has recently become more common. Even in patients with normal findings on computed tomography, admission remains a common practice probably because of the risk of missing severe complications and medico-legal implication.⁷ The assessment of benefits and hazards in the treatment of patients with mild head injury is of paramount importance for public health.¹⁰ Because of the high volume of patients with mild head injury, their management consumes considerable economic resources. Different management strategies for these patients have both medical and economic implications.¹¹ The question has been raised concerning whether all patients with mild head injury instead can be triaged for admission with an early CT scan.¹² Unnecessary admissions of patients with normal CT findings might therefore be avoided and better care provided for patients with abnormal CT findings and at higher risk of deterioration with need for surgery or more intensive care.¹³

The most common classification system for TBI severity is based on the Glasgow Coma Scale (GCS) score determined at the time of injury. The GCS is a 3–15 point scale used to assess a patient's level of

consciousness and level of neurologic functioning.^{14,15} It consists of 3 sections, each of which is scored: best motor response, best verbal response, and eye opening. A total score of 3–8 for the 3 sections indicates severe TBI, a score of 9–12 indicates moderate TBI, and a score of 13–15 indicates mild TBI.¹⁵

The overall score generally refers to the best response/examination obtained within the first 6–8 hours after injury and following resuscitation and is considered to be a predictor of the patient's overall outcome.¹⁶⁻¹⁹

The GCS has 2 main advantages in that it provides a reproducible, objective evaluation of neurological status and it is a relatively simple way to monitor a patient's neurological condition over time. The GCS has shortcomings because its reliability depends on the absence of confounding factors (e.g., sedation, paralytics, hypothermia, hypotension, hypoxia).

The GCS score is used to categorize the severity of head injury into mild (15–13), moderate (12–9), or severe (8 or less). In general, mild head injury does not usually involve significant primary brain injury, is not associated with neurological deficits, and may or may not include loss of consciousness. Approximately 75% of head injuries are categorized as mild to moderate in nature.²⁰

Imaging modalities for head injury include: Skull X ray, Computed tomography, MRI, Cerebral angiography, CTA, MRA. CT advantages for evaluation of the head-injured patient include its sensitivity for demonstrating mass effect, ventricular size and configuration, bone injuries, and acute hemorrhage.²¹ CT scanning of the head is the criterion standard for patients with acute closed head injuries.²² CT scans are very sensitive to acute haemorrhage or skull fractures. CT scans aid in evaluating²³:

- Intracranial haemorrhage
- Skull fractures
- Mass effect and midline shift
- Obliteration of the basal cisterns
- Evidence of herniation (subfalcine, tonsillar, or uncal)

CT scans are helpful in assessing the degree of intracranial injury, in predicting outcome, and, if findings are normal, in avoiding unnecessary hospitalization.^{24,25} The objective of the study was to determine the diagnostic accuracy of cranial Computed Tomography in patients with minor head injury.

MATERIAL AND METHODS

This was a Cross sectional validation study with non probability convenience sampling which involved head injury patients coming to Accident and Emergency Department of Pakistan Institute of Medical sciences and was conducted at Radiology Department in collaboration with Neurosurgery Department. Duration of study was six months. The study included 116 patients of minor head injury coming to Accident and

Emergency Department. In all the patients history was taken and GCS was calculated by a standardised neurological examination. Timing of examination was recorded for each patient. Patients then underwent non contrast enhanced cranial tomography using a helical CT scanner Asteion, Toshiba® medical system within 6 hours of admission.

A computed tomography scan was considered positive only if an intracranial injury (epidural haematoma, subdural haematoma, subarachnoid haemorrhage, pneumocephalus or parenchymal contusion) is demonstrated while the absence of these lesions constituted a negative result. After computed tomography patients were retained in the hospital and clinical outcome was determined at 24 hours after admission and at discharge and included observation or clinical deterioration.

Clinical deterioration was defined as a decrease in 2 or more points on GCS, development of focal neurological abnormality, need to move the patient to intensive care unit because of head injury and need for neurosurgical intervention or death.

In each case, CT findings were correlated with the clinical outcome. A true positive was defined as a case of intracranial injury diagnosed on CT scan with subsequent clinical deterioration. A true negative was a normal CT scan followed by no clinical deterioration and patient was discharged after only being kept under observation.

A false positive was a case diagnosed as intracranial injury on CT scan but there was no clinical deterioration and patient was discharged after observation. A false negative was a normal CT scan but the patient subsequently developed clinical deterioration.

The data were analysed on SPSS-11. A 2×2 table was used to calculate sensitivity, specificity, positive predictive value, negative predictive value and diagnostic efficacy for cranial CT.

RESULTS

The number of patients included in this study was 116. Mean age of the patients was 26.33 years. CT was able to correctly diagnose 111 cases in 116 patients with an accuracy of 95.7%. Twenty-two cases were declared as having a positive computed tomography while 94 were having no abnormality on cranial CT. Out of the 22 positive cases on CT, 18 patients were correctly diagnosed as they had subsequent deterioration in GCS or required surgical intervention while 4 cases were false positive as they were discharged after observation only. Out of 94 negative cases on CT, 93 were true negative while only 1 case was false negative as the patient subsequently required surgical intervention.

Table-1: Sensitivity, Specificity, Predictive Values and accuracy of cranial computed tomography

Sensitivity %	Specificity %	PPV %	NPV %	Accuracy %
94	96	81	99	95.7

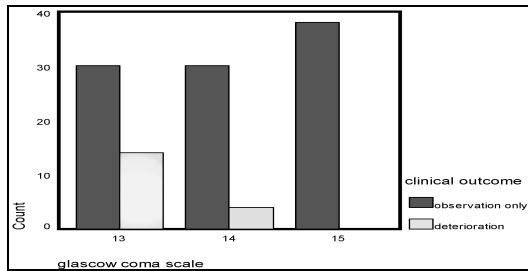


Figure-1: Correlation of GCS with clinical outcome (n=116)

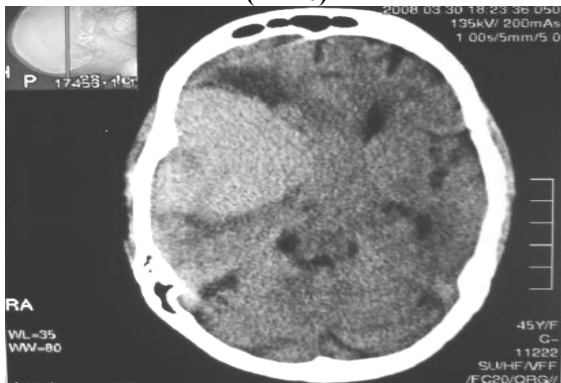


Figure-2: CT scan showing a large contusion in right fronto-parietal region associated with significant mass effect

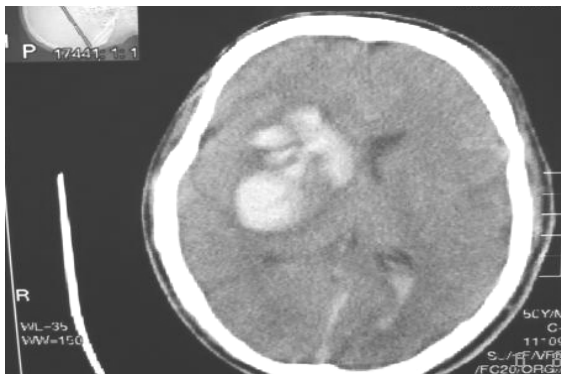


Figure-3: CT scan showing a right fronto-parietal contusion with haematoma extension into lateral ventricle

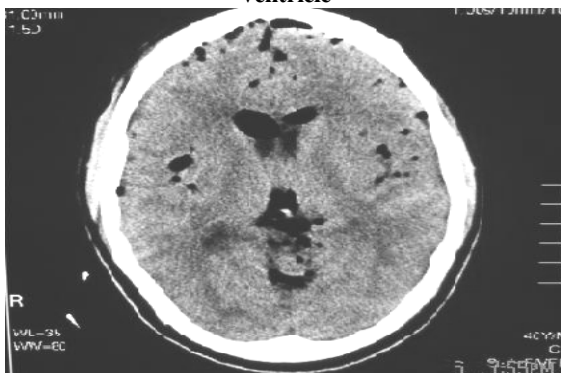

Figure-4: CT scan showing extensive pneumocephalus

DISCUSSION

Mild head injury is a common reason for hospital admission after trauma. Traditionally, the management of these patients has been based on in-hospital observation. An increasing number of patients currently receive computed tomography (CT) in addition to in-hospital observation. It has been suggested that patients can be triaged for admission with an early CT scan, thereby avoiding unnecessary admissions when findings are normal. At the same time, better care could be provided for the patients with abnormal CT findings and a higher risk for complications. Early CT for these patients could result in better supervision and more rapid access to treatment, possibly yielding a better prognosis.

This strategy is based on the ability of early CT scan to identify abnormal changes associated with the risk for later deterioration. CT advantages for evaluation of head injury patients include its sensitivity for demonstrating mass effect, ventricular size and configuration, bone injuries and acute haemorrhage regardless of location. Our results were comparable with those of other studies. Tong DH *et al*²⁶ showed that the sensitivity of CT for detecting intracranial abnormality after TBI varies from 68–94%. Livingston DH *et al*²⁷ found the negative predictive value of CT to be 99.70% while Shackford SR *et al*²⁸ found the sensitivity of CT to be 100% with negative predictive value of 100% and specificity of 51%. The patients with positive CT scans constituted 19% of total in our study which is the same found by Turedi S *et al*⁵.

Only one patient was false negative. The likelihood of haemorrhagic lesions which were too small on initial examination to be detected but show considerable progression subsequently to be significant is small. Dacey RG Jr *et al*²⁹ reported the incidence of this phenomenon to be between 1–3%.

Incidence of abnormal CT scans was found to be inversely proportional to GCS. In our study 60% of the patients with GCS 13 had an intracranial abnormality. Thiruppathy SP *et al*³⁰ found this to be 51%. No patient with an admission GCS of 15, a normal neurological examination and a normal CT deteriorated during hospital stay consistent with conclusions of Thiruppathy SP *et al*³⁰. Fifty-four percent of the patients with symptom of vomiting had a positive CT scan. In the study conducted by Turedi S *et al*⁵ this was 44.5%. Among the traumatic findings Cerebral contusions and subdural hematomas were the most common injuries, a finding that is consistent with the results of Miller EC *et al*⁶ and Borczuk P *et al*³¹. Patients with multiple lesions on CT had a greater chance of deteriorating than those with a single lesion.

CONCLUSION

Minor head injuries constitute a significant economic, public health and medico-legal dilemma. Sensitivity and specificity of CT scan make it the modality of choice in the setting of acute head injury. Patients with both a

normal cranial CT scan and normal neurologic examination following minimal head injury have no risk of neurologic deterioration, and on not having other body system injuries can be safely discharged from the emergency department without any inpatient or outpatient observation.

REFERENCES

- Siddiqui A A, Zafar H, Bashir HS. An audit of head trauma care and mortality. *J Coll Physicians Surg Pak* 2004;14:173-7.
- Jooma R, Ahmad S, Zarden AM. Comparison of two surveys of head injured patients presenting during a calendar year to an urban medical centre 32 years apart. *J Pak Med Assoc* 2005;55:530-2.
- Janett B, MacMillan R. Epidemiology of Head Injury. *Br Med J (Clin Res Ed)* 1981;282:101-4.
- Chesnut RM. Head Trauma. In: Greenfield LJ, Mulholland MW, Oldham KT, Zelenock GB, (Eds). *Surgery Scientific Principles and Practice*. Philadelphia: Lippincott Williams & Wilkins; 1993. p. 267-72.
- Saboori M, Ahmadi J, Farajzadegan Z. Indications for brain CT scan in Patients with minor head injury. *Clin Neurol Neurosurg* 2007;109:399-405.
- Turedi S, Hasanbasoglu A, Gunduz A, Yandi M. Clinical decision instruments for CT scan in minor head trauma. *J Emerg Med* 2008;34:253-9.
- af Geijerstam JL, Oredson S, Britton M; OCTOPUS Study Investigators. Medical outcome after immediate computed tomography or admission for observation in head injury: randomized control trial. *BMJ* 2006;333:465.
- Stiell IG, Wells GA, Vandemheen K, Clement C, Lesiuk H, Laupacis A, et al. The Canadian CT Head Rule for patients with minor head injury. *Lancet*. 2001;357:1391-6.
- Miller EC, Holmes JF, Derlet RW. Utilizing clinical factors to reduce head CT scan ordering for minor head trauma patients. *J Emerg Med* 1997;15:453-7.
- Fabbri A, Servadei F, Marchesini G, Morselli Labate AM, Dente M, Iervese T et al. A. Prospective validation of a proposal for diagnosis and management of patients attending the emergency department for mild head injury. *J Neurol Neurosurg Psychiatry* 2004;75:410-6.
- Jagoda AS, Bazarian JJ, Bruns JJ Jr, Cantrill SV, Gean AD, Howard PK, et al. Clinical policy: Neuroimaging and decision making in adult traumatic brain injury in the acute setting. *J Emerg Nurs* 2009;35(2):e5-40.
- Stein SC, Ross SE. The value of computed tomographic scans in patients with low-risk head. *Neurosurgery* 1990;26:638-40
- af Geijerstam J-L, Britton M. Mild head injury—mortality and complication rate: meta-analysis of findings in a systemic literature review. *Acta Neurochir (Wien)* 2003;145:843-50.
- McDonald CM, Jaffe KM, Fay GC, et al. Comparison of indices of traumatic brain injury severity as predictors of neurobehavioral outcome in children. *Arch Phys Med Rehabil* 1994;75(3):328-37.
- Teasdale G Jennett B. Assessment of coma and impaired consciousness. A practical scale. *Lancet*. 1974;2(7872):81-4.
- Jagger J, Fife D, Vernberg K, Jane JA. Effect of alcohol intoxication on the diagnosis and apparent severity of brain injury. *Neurosurgery*. 1984;15(3):303-6.
- Pal J, Brown R, Fleischer D. The value of the Glasgow Coma Scale and Injury Severity Score: predicting outcome in multiple trauma patients with head injury. *J Trauma*. 1989;29(6):746-8
- Waxman K, Sundine MJ, Young RF. Is early prediction of outcome in severe head injury possible? *Arch Surg* 1991;126(10):1237-41.
- Vollmer DG. Prognosis and outcome of severe injury. In: Cooper PR, (Ed). *Head Injury*. 3rd ed. Baltimore: Lippincott Williams & Wilkins;1993.p. 533-81.
- Langfitt TW, Gennarelli TA. Can the outcome from head injury be improved? *J Neurosurg* 1982;56(1):19-25.
- Davis PC. Head trauma. *AJNR Am J Neuroradiol* 2007;28:1619-21.
- Valadka AB, Ward JD, Smoker WRK. Brain Imaging in Neurologic Emergencies. In: Prough DS, Traystman RJ, (Eds). *Critical Care: State of the Art*. Vol 14. Anaheim, Ca: Society of Critical Care Medicine;1993:1-60.
- Langfitt TW, Gennarelli TA. Can the out come from head injury be improved? *J Neurosurg* 1982;56(1):19-25.
- Livingston DH, Loder PA, Koziol J, Hunt CD. The use of CT scanning to triage patients requiring admission following minimal head injury. *J Trauma* 1991;31(4):483-7; discussion 487-9.
- Shackford SR, Wald SL, Ross SE, Cogbill TH, Hoyt DB, Morris JA, et al. The clinical utility of computed tomographic scanning and neurologic examination in the management of patients with minor head injuries. *J Trauma*. 1992;33:385-94.
- Tong KA, Oyoyo U, Holshouser BA, Ashwal S. Neuroimaging for traumatic brain injury. In Edina LS, Blackmore CC, (Editors). *Evidence based imaging. Optimizing imaging in patient care*. New York; Springerlink; 2006.233-59.
- Livingston DH, Lavery RF, Passannante MR, Shurnik JH, Baker S, Fabian TC, et al. Emergency department discharge of patients with a negative cranial computed tomography scan after minimal head injury. *Ann Surg* 2000;232(1):126-32.
- Shackford SR, Wald SL, Ross SE, Cogbill TH, Hoyt DB, Morris JA, et al. The clinical utility of computed tomographic scanning and neurologic examination in the management of patients with minor head injuries. *J Trauma* 1992;33:385-94.
- Dacey RG Jr, Alves WM, Rimel RW, Winn RH, Jane JH. Neurosurgical complications after apparently minor head injury. Assessment of risk in a series of 610 patients. *J Neurosurg* 1986;65:203-10.
- Thiruppathy Sp, Muthukumar N. Mild head injury: revisited. *Acta Neurochir (Wien)* 2004;146:1075-82.
- Borcuzuk P. Predictors of intracranial injury in patients with mild head trauma. *Ann Emerg Med* 1995;25:731-6.

Address for Correspondence:

Dr. Tayyaba Afzal, Classified Radiologist, CMH, Muzaffarabad, AJK, Pakistan. **Cell:** +92-300-5292302

Email: tayyabazaafir@yahoo.com