

CASE REPORT

METASTATIC CARDIAC MELANOMA WITH T-WAVE INVERSIONS

Usman Ali, Ahmed Halian*, Najeebullah Khan**, Saira Bano Khwaja***

Royal United Hospital, Bath-UK, *Morrison Hospital, Swansea-UK, **Northampton General Hospital-UK, Walsall Manor Hospital-UK

A woman in her 70's with a background of ocular malignant melanoma treated more than a decade ago was admitted to hospital with symptoms of dysphagia and exertional shortness of breath. Routine ECG showed a grossly abnormal ECG with T wave inversion in inferolateral leads and some anterior leads. Consequently, echocardiography and CT demonstrated the presence of a large pericardial tumour which on biopsy was found to be metastatic melanoma. Patient was treated with palliative radiotherapy with only temporary initial benefit.

Keywords: Malignant melanoma; Cardiac metastasis; Cardiac tumours; Pericardial tumours

Citation: Ali U, Halian A, Khan N, Khwaja SB. Metastatic cardiac melanoma with t-wave inversions. J Ayub Med Coll Abbottabad 2018;30(2):278-9.

INTRODUCTION

T wave changes are one of the most common findings in ECGs and structural causes should always be considered for it. Cardiac metastasis is uncommon but this case demonstrates a histologically proven metastatic deposit in the epicardium and a reason for ECG changes with no ischaemic cardiac symptoms. This case also reminds us about malignant melanoma as a common cause for cardiac metastasis and that metastasis should still be suspected even after 2 decades of seemingly curative treatment for malignant melanoma.

CASE REPORT

A 70-year-old woman was referred for echocardiography following the finding of widespread T wave inversion on a 12 lead ECG (Figure-1) as part of investigation for dysphagia, weight loss and night sweats. Apart from malignant melanoma of the right eye 10 years ago which was treated with eye enucleation, the patient reported no ischaemic cardiac symptoms nor had any history of ischaemic heart disease.

Cardiorespiratory examination was unremarkable. No evidence of recurrent of skin melanoma but there were few moles not typical of melanoma were noted.

ECG showed marked T wave inversion. Echocardiography showed a large echo-lucent mass that was compressing the right ventricle. Mid to apical regions were akinetic with severely hypertrophied septum and moderately impaired left ventricular function. A small loculated pericardial effusion was also seen (Figures 1a).

A cardiac MRI was requested for further imaging. However, during assessment for this, she warranted a history of metalwork in the right orbit with a prosthetic eye (site of previous malignant melanoma). This raised the suspicion of metastatic melanoma.

Computed tomography (CT) of the chest and abdomen confirmed a large tumour in the pericardial region (Figure 1b) enlarged mediastinal lymph nodes, with hepatic and renal masses. Small peripheral lung opacities were also noted.

CT- guided Biopsy confirmed a poorly differentiated malignant tumour positive for S100 Melan A, appearances suggestive of metastatic melanoma. The patient was treated with palliative radiotherapy with initial but temporary symptomatic benefit. She was referred for palliative radiotherapy with initial but temporary symptomatic benefit.

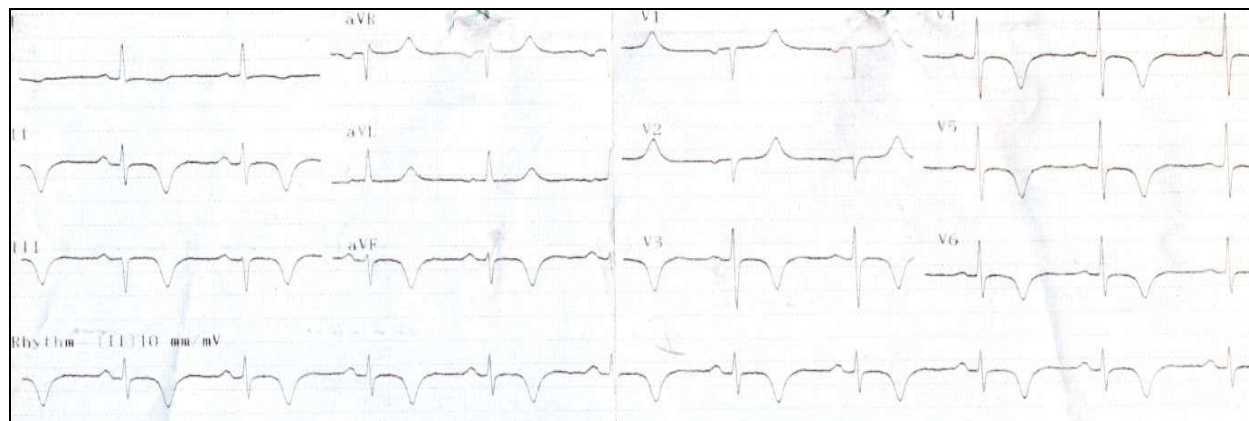


Figure-1: ECG

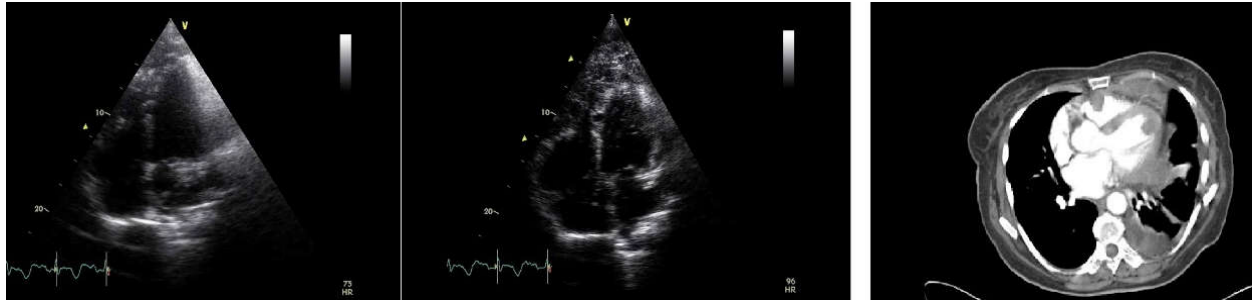


Figure-1(a): Echocardiogram images (b) CT Chest (mediastinal window)

DISCUSSION

Cardiac tumours are mostly metastatic. The most common tumours that metastasize to the heart are breast cancer, malignant melanoma and lung cancer.^{1,2} Melanoma is unusual in that the incidence of metastases to the heart is very high. The number of cases diagnosed ante-mortem is fewer (2–4%) as melanoma is able to metastasize widely before patients develop cardiac symptoms.¹ Post-mortem studies have estimated the incidence to be as high as 50–71%.³ Any chamber of the heart may be affected by malignant melanoma. Rarely an isolated lesion may be found. More commonly, metastases are widespread involving myocardium, pericardium and endocardium. Cardiac metastases from melanoma are usually found in the right heart.³ It is rare that only the endocardium is affected.³ Improvement in management of malignant melanoma has led to increased survival rates and a subsequent increase in the number of cases of cardiac metastases late in the disease process.³ The 5-year survival rate being quoted as low as 10%.³

Presentations of cardiac metastases include heart failure secondary to involvement of valves or the myocardium, arrhythmias, systemic embolization of tumour or general features of malignancy e.g. weight loss, night sweats, anorexia.⁵ Diagnosis of cardiac metastases as in this case is often triggered by an abnormal ECG. Echocardiograms are most useful for detecting lesions of the endocardium. Transoesophageal echocardiography is useful for detecting attachment sites and morphological features. CT imaging is highly sensitive for paracardiac lesions or cardiovascular magnetic resonance imaging (CMR) which can distinguish benign vs. malignant cardiac metastases based on differing signal patterns.⁶

We have presented a case of cardiac metastases in a patient with a past medical history of metastatic melanoma, diagnosed following an abnormal ECG. Due to the high occurrence of melanoma spread to the heart and associated abysmal prognosis there should be a high index of suspicion in these patients. The presence of cardiac metastases in melanoma patients should be considered even in the absence of symptoms. Previous case reports on melanotic cardiac metastases have suggested the introduction of screening with the use of CMR.⁶

As most cases of cardiac metastases secondary to malignant melanoma are diagnosed post-mortem we suggest that all patients with a diagnosis of malignant melanoma should have interval ECG and echocardiography. Structural heart disease should be considered as a cause of wide spread T wave inversion

Metastasis from malignant melanoma should be suspected even if curative treatment was more than a decade earlier

CMR can differentiate between benign and malignant tumours based on signal intensity

REFERENCES

1. Chen RH, Gaos CM, Frazier OH. Complete resection of a right atrial intracavitary metastatic melanoma. *Ann Thorac Surg* 1996;61(4):1255–7.
2. Savoia P, Fierro MT, Zaccagna A, Bemengo MG. Metastatic melanoma of the heart. *J Surg Oncol* 2000;75(3):203–7.
3. Gibbs P, Cebon JS, Calafiore P, Robinson WA. Cardiac metastases from malignant melanoma. *Cancer* 1999;85(1):78–84.
4. Scottish Intercollegiate Guidelines Network. Cutaneous melanoma: a national clinical guideline. Edinburgh: Scottish Intercollegiate Guidelines Network; 2003.
5. Reynen K, Köckeritz U, Strasser RH. Metastases to the heart. *Ann Oncol* 2004;15(3):375–81.
6. Rathi VK, Williams RB, Yamrozik J, Grill H, Biederman RW. Cardiovascular magnetic resonance of the charcoal heart. *J Cardiovasc Magn Reson* 2008;10:37.

Received: 5 February, 2017

Revised: --

Accepted: 24 September, 2017

Address for Correspondence:

Najeebullah Khan, CTI General Medicine, Northampton General Hospital, NHS Trust, Northampton-UK

Postcode: NN1 5BD

Contact: +44 7438095187

Email: najeebkhan920@gmail.com