

CASE REPORT

CYTOMEGALOVIRAL ENTERITIS: A RARE CAUSE OF SMALL GUT PERFORATION

Maqbool Ahmed, Sohail Saqib, Mannan Masud, Aurangzeb, Abeerah Pervez, Zainab Kamal, Raheel Khan

Department of Surgery, Military Hospital, Rawalpindi

A 47-year-old man was admitted with four months history of pain upper central abdomen associated with passage of 3–4 loose watery stools per day. Abdominal examination revealed soft abdomen with mild tenderness in the para-umbilical region. There was associated hepatomegaly. His Hb% was low, liver and renal functions were deranged. Upper GI endoscopy revealed antral ulcer, and colonoscopy revealed a caecal ulcer, which were biopsied. Liver biopsy was also done. Histopathology report showed evidence of inflammatory colitis and chronic hepatitis, so a diagnosis of inflammatory bowel disease with autoimmune hepatitis was made. He was negative for HIV and hepatitis serology. He was given long list of medicine including steroids but the symptoms did not improve. Two months after admission he developed severe abdominal pain associated with distension. The X-Ray chest revealed pneumoperitoneum and laparotomy was carried out which revealed a small perforation in terminal ileum associated with multiple circular indurated areas ranging from few mm to 1.5 Cm in size with central thinning spread over distal half of small gut and enlarged mesenteric lymph nodes. The biopsy of perforated area revealed cytomegaloviral enteritis. Postoperatively patient developed ARDS and died on 13th postoperative day.

Keywords: Cytomegalovirus, CMV, Perforation, ileal

INTRODUCTION

Cytomegalovirus (CMV) infection of the gastrointestinal tract usually occurs in patients with acquired immune deficiency syndrome (AIDS).¹ The colon and upper GI tract are the most common sites of involvement followed by small gut. The patients with inflammatory bowel disease, treated with steroids are more prone to be infected with this virus.² Small bowel involvement may be seen as an isolated infection or in association with colonic or upper GI involvement. These patients may be asymptomatic or present with abdominal pain, fever, diarrhoea, massive bleed or perforation. We present here a case of ileal perforation resulting from CMV infection in an HIV negative, immune compromised individual.

CASE REPORT

A 47-year-old man was admitted with 4 months history of pain upper central abdomen, loose stools and generalised weakness. Pain was gradual in onset, moderate in intensity, non-radiating and non-shifting with no aggravating and relieving factors. This was associated with passage of 3–4 loose watery stools per day. Patient had lost 7–8 Kg weight during the course of illness. The examination revealed stable vital signs. He was pale and had vitiligo on abdominal skin. Abdomen was soft with tenderness in the central abdomen and liver was palpable three finger breadth below right costal margin.

Patient was extensively investigated and had low Hb%, deranged liver functions and raised serum urea and creatinine. His upper GI endoscopy and colonoscopy was done which showed gastric ulcer and

caecal ulcer, and biopsies were taken. Liver biopsy was also done. Histopathology report showed evidence of inflammatory colitis and chronic hepatitis, so a diagnosis of inflammatory bowel disease with autoimmune hepatitis was made. He was negative for HIV and hepatitis serology. Patient was given long array of medications including steroids during the course of admission but his pain persisted. He also developed herpes simplex keratitis. Condition of the patient continued to deteriorate and one day (2 months after admission) he complained of severe abdominal pain and abdominal distension. X-Ray chest erect showed pneumo-peritoneum for which exploratory laparotomy was done. The laparotomy revealed mildly dilated small and large gut, congested small and large gut mesentery. Multiple areas of thickening at least 17 in number varying from few mm to 1.5 Cm, mostly circular with central thinning were seen (Figure-1).

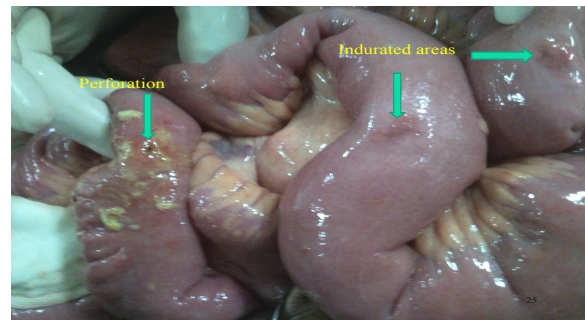


Figure-1: Perforation and associated lesions

Creeping of mesenteric fat was seen at a few places. Perforation of terminal ileum <1 mm in size, 10

Cm from ileo-caecal junction was found with minimal peritoneal soiling. There were enlarged mesenteric lymph nodes. Biopsies of the perforated area of gut and lymph node were taken. Histopathology revealed Cytomegalovirus enteritis. His blood samples for Cytomegalovirus antibodies also confirmed presence of Cytomegalovirus infection. Postoperatively patient went into ARDS and was placed on ventilatory support but could not survive and died on 13th postoperative day.

DISCUSSION

Perforation of small gut apart from trauma is usually caused by typhoid fever or tuberculosis. The other possibilities include carcinoma, lymphoma, Crohn's disease, non specific inflammation, radiation enteritis or can result from mesenteric ischaemia.

Asymptomatic CMV infection is common in the general population as evidenced by seropositivity in 40–100% of a randomly tested adult population.³ CMV can remain dormant in the tissues and cause opportunistic infection when there is a decline in the immune status of the host.⁴ This includes HIV patients, those receiving chemotherapy for cancer and patients on immune-suppressing medicines following an organ transplant. It can cause retinitis, pneumonitis, cerebral infection and gastro intestinal disease. CMV can infect any part of the GI tract. The sites commonly involved in descending order of frequency are the colon, oesophagus, stomach and small bowel. Involvement of the small bowel may affect its entire length⁵ or may be localised to the terminal ileum.⁶ The infection is spread by saliva, urine, respiratory droplets, sexual contact, and blood transfusions.

Prior to the availability of highly active antiretroviral therapy (HAART), CMV gastro intestinal disease was common in patients with AIDS; however, the incidence of CMV GI disease has decreased substantially since HAART became available. Symptom presentation depends on the anatomic location of the infection. CMV infection of the small bowel accounts for approximately 4% of all CMV infections of the gastrointestinal tract, the usual presentation is abdominal pain, diarrhoea, bloody stools and weight loss.⁷ More severe infections can result in gastrointestinal bleeding or perforation. Histologically CMV enteritis is characterised by mucosal inflammation, tissue necrosis, and vascular endothelial involvement. CMV inclusion bodies (large cells containing eosinophilic intranuclear and frequently basophilic intracytoplasmic inclusions) are present in mucosal biopsies stained with haematoxylin and eosin.

Treatment of CMV gastrointestinal disease involves induction therapy for 3–6 weeks; whether

maintenance treatment is also needed is controversial. The drugs used include ganciclovir and foscarnet.^{8,9} Twice-weekly monitoring of the complete blood count during induction therapy with ganciclovir is indicated. Patients who develop an absolute neutrophil count <500 cells/dl can be managed with colony stimulating growth factors. Twice-weekly monitoring of serum creatinine and electrolytes is indicated in patients who are taking foscarnet. In people with normal immune systems, symptoms usually subside without treatment. In those with suppressed immune systems, symptoms are more severe and outcome depends upon the severity of the immunodeficiency and the severity of the infection. Single perforation can be treated by excision and simple closure.¹⁰ Resection and anastomosis should be carried out for multiple perforations/ulcers located in a small segment of gut¹¹, followed by antiviral drugs on confirmation.

REFERENCES

- Jacobson MA, Mills J. Serious cytomegalovirus disease in the acquired immune deficiency syndrome. *Ann Int med* 1988;108:585–94.
- Eyre-Brook IA, Dundas S. Incidence and clinical significance of colonic cytomegalovirus infection in idiopathic inflammatory bowel disease requiring colectomy. *Gut* 1986;27:1419–25.
- Krech U. Complement-fixing antibodies against cytomegalovirus in different parts of the world. *Bull World Health Organ* 1973;49:103–6.
- Weber R, Ledergerber B, Zbinden R, Altwegg M, Pfyffer GE, Spycher MA, *et al.* Enteric infections and diarrhea in human immunodeficiency virus-infected persons: Prospective community-based cohort study. *Swiss HIV Cohort Study. Arch Intern Med* 1999;159:1473–80.
- Dolgin SE, Larsen JG, Shah KD, David E. CMV enteritis causing hemorrhage and obstruction in an infant with AIDS. *J Pediatr Surg* 1990;25:696–8.
- Lai IR, Chen KM, Shun CT, Chen MY. Cytomegalovirus enteritis causing massive bleeding in a patient with AIDS. *Hepatogastroenterology* 1996;43:987–91.
- Chamberlain, RS, Atkins, S, Saini, N, White, JC. Ileal perforation caused by cytomegalovirus infection in a critically ill adult. *J Clin Gastroenterol* 2000;30:432.
- Dieterich DT, Poles MA, Lew EA, Martin-Munley S, Johnson J, Nix D, *et al.* Treatment of gastrointestinal cytomegalovirus infection with twice-daily foscarnet: a pilot study of safety, efficacy, and pharmacokinetics in patients with AIDS. *Antimicrob Agents Chemother* 1997;41(6):1226–30.
- Nelson, MR, Connolly, GM, Hawkins, DA, Gazzard, BG. Foscarnet in the treatment of cytomegalovirus infection of the esophagus and colon in patients with the acquired immune deficiency syndrome. *Am J Gastroenterol* 1991;86:876.
- Wani RA, Parray FQ, Bhat NA, Wani MA, Bhat TH, Farzana F. Nontraumatic terminal ileal perforation. *World J Emerg Surg* 2006;1:7.
- Stoner MC, Forsythe R, Mills AS, Ivatury RR, Broderick TJ. Intestinal perforation secondary to *Salmonella typhi*: case report and review of the literature. *Am Surg* 2000;66:219–22.

Address for Correspondence:

Dr. Maqbool Ahmed, House 62, Street 8, Valley Road, Rawalpindi, Pakistan. **Tel:** +92-51-5491438, **Cell:** +92-321-5556223

Email: maqbool957@hotmail.com