

CASE REPORT

AN UNUSUAL CAUSE OF UPPER GASTROINTESTINAL BLEEDING

Kishwar Ali, Muhammad Zarin*, Humera Latif

Department of General Surgery, Ayub Medical College, Abbottabad, *Khyber Teaching Hospital, Peshawar-Pakistan

Gastrointestinal haemorrhage (GI) is a serious condition that presents both diagnostic as well as therapeutic challenges. Resuscitation of the patient is the first and most important step in its management followed by measures to localize and treat the exact source and site of bleeding. These modalities are upper and lower GI endoscopies, radionuclide imaging and angiography. Surgery is the last resort to handle the situation, if the patient does not respond to resuscitative measures and the various interventional procedures fail to locate and stop the bleeding. We present a case of upper GI bleeding which presented with massive per rectal bleeding and the patient was not responding to resuscitation with multiple blood transfusions. Ultimately an exploratory laparotomy was done which revealed an extra-intestinal source of bleeding into the lumen of duodenum, presenting as upper GI bleeding.

Keywords: Gastrointestinal haemorrhage, duodenal perforation, laparotomy

J Ayub Med Coll Abbottabad 2015;27(3):714-6

INTRODUCTION

Gastrointestinal (GI) haemorrhage is a life threatening condition and a systematic approach is essential to its successful management. Resuscitation of the patient is the first and most important step followed by various diagnostic studies to localize the source of haemorrhage. Various non-operative and operative options are then available to control the bleeding.¹

Upper GI haemorrhage arises from sources above the ligament of Treitz while Lower GI haemorrhage refers to the bleeding that arises distal to it. The bleeding may vary from spotting to massive intestinal haemorrhage causing hemodynamic compromise needing rapid resuscitation with multiple blood transfusions.

The bleeding can arise from any location in the gastrointestinal tract, may be intermittent and vary in degree, that's why it presents a challenge. It may present as melena, which suggests a source in the proximal colon, small intestine, or stomach; or as haematochezia, which suggests left colonic haemorrhage, rectal or anal sources.² Common causes of gastrointestinal haemorrhage include peptic ulcer, gastric erosion, posterior duodenal perforation, Meckel's diverticulum, colonic diverticula, angiodysplasia, ischemic colitis, inflammatory bowel disease, various gastrointestinal tumours and anorectal diseases.³

Massive upper GI haemorrhage may present with rectal bleeding in 10-15% of cases and it is due to the cathartic effect of the blood causing rapid intestinal transit.⁴ We report an interesting case of upper GI bleeding presenting as massive rectal bleeding causing hemodynamic instability. The blood was coming into the duodenum from an extra-intestinal source.

CASE REPORT

A 20 years old female patient presented to the surgical emergency with continuous per rectal bleeding (melena) of 3 hours onset. She also had two episodes of hematemesis one day back. On early assessment she was found to be in a state of shock with rapid, thready pulse, hypotension, pallor, cold clammy skin and drowsiness. She was immediately resuscitated with multiple blood transfusions, intravenous fluids, and other relevant medications. Intake output and vitals monitoring was initiated. On further inquiry it was found that she had been recently operated one month back for jejunal obstruction secondary to strictures for which stricturoplasty and resection anastomosis of jejunum was done. Histopathology of the resected specimen showed Crohn's disease. She was not using any regular medications for her Crohn's disease. On detailed examination her abdomen was found soft and non-tender. The rectum was full of blood mixed stools with continuous bleed with no apparent bleeding source in the anorectum. A nasogastric tube was passed which drained altered blood and this gave a clue that the possible source may be in the stomach or duodenum.

Further plan was to proceed with urgent upper and lower gastrointestinal endoscopies once the patient vital signs become stable and the bleeding stops. After continuous resuscitative efforts of six hours with blood transfusions, the patient remained in the same condition with continuous bleed and hypotension. The gastroenterologist opinion was that endoscopy would not help to locate the source of bleeding in the current scenario of on-going haemorrhage. As we had no facilities of angiography and radionuclide imaging, therefore a decision of laparotomy was taken. Although it was in our mind

that we might not be able to identify the bleeding source on laparotomy even, but we did not have any other option left. This thing was made clear to the patient relatives.

On laparotomy we found a clean abdomen with gut full of blood, as revealed by the purplish blue appearance of its content externally. The gut was emptied of blood by milking its contents distally. Multiple non crushing intestinal clamps were applied to the gut at a distance from each other to locate the site of bleeding. Pooling of blood was observed in the upper jejunum near the duodenojejunal junction. On further exploration of the area of stomach and duodenum, the gall bladder was found adherent to the duodenum. On careful lifting of the gall bladder, a 2×2 cm perforation was found on the anterior wall of the first part of duodenum. The adherent part of the gall bladder was its infundibulum in which a large spurting vessel was found, pouring its blood directly into the duodenal perforation. The ulcer was slowly eroding into the gall bladder wall and in this process it has eroded a branch of cystic artery in the gall bladder wall. Interestingly this whole perforation area was completely sealed by the gall bladder with no peritoneal contamination and peritonitis.

We performed cholecystectomy, omentopexy of the duodenal perforation and biopsy from the perforation margins. The patient recovered well. Biopsy of the perforation margins showed nonspecific inflammation although we were expecting it to be due to Crohn's disease.

DISCUSSION

Acute GI bleeding is a common medical emergency with an annual incidence of 40-150 episodes per 100 000 persons for upper GI haemorrhage and 20-27 episodes per 100,000 persons for lower GI haemorrhage. Patients with massive upper or lower gastrointestinal haemorrhage presents a diagnostic challenge and needs a careful evaluation along with on-going resuscitation. The bleeding can stop spontaneously in 75% cases; however, the recurrence of bleeding in 25% cases can lead to a mortality rate of 3-5%.⁵

The initial approach to a patient with per rectal bleeding, after resuscitation, is to rule out anorectal causes by digital rectal examination and proctoscopy. Multiple modalities are available that can be diagnostic as well as therapeutic for GI haemorrhage. These include upper and lower GI endoscopies, technetium-99m labelled red cell scanning, angiography and CT angiography. Each has its own advantages and limitations.⁶ Upper and lower GI endoscopies are currently considered the first-line diagnostic procedures for both upper and lower GI bleeding. They can clearly localize the site

and source of bleeding and many therapeutic interventions can be carried out. However, they are of less use in case of on-going bleeding and in unstable patients. Similarly radionuclide scanning and angiography have their own limitations.^{7,8}

Based on the initial assessment patients can be divided into three clinical categories: 1) minor self-limited, 2) major self-limited or 3) major on-going. Major on-going haemorrhage requires prompt intervention with angiography or surgery. Minor and major self-limited haemorrhage needs further evaluation with various diagnostic tests.¹

Surgical therapy for intestinal bleeding is needed in patients who are hemodynamically unresponsive to the initial resuscitation and in whom the site of haemorrhage may be localized, but the available therapeutic interventions fail to control the bleeding. It has been noted that with increasing transfusion requirements the patient mortality also increases. Therefore, patients with on-going haemorrhage whose blood requirement increases than 6-7 units should undergo urgent surgical intervention.⁹

Surgery starts with the objective of localizing the site of intraluminal bleeding. This includes visual inspection and palpation of the stomach, duodenum, the whole small and large gut for any pathology like tumours, Meckel's diverticulum, colitis etc. Applying non crushing intestinal clamps to the gut at a distance from each other and observing for any pooling in between can give a crude idea as to the site of bleeding. If no source is found, the surgeon may use on table endoscopy if facilities are available. Transillumination can identify vascular anomalies, small ulcers, or tumours. Once the bleeding site is localized, an appropriate segmental resection can be carried out. If no source of bleeding is confirmed, but appears to arise from the colon, a subtotal or total colectomy can be performed.¹⁰

In our case, we had a young patient with Crohn's disease with massive per rectal bleeding. The patient was unstable regarding her hemodynamic parameters and she was not responding to resuscitative measures. We could not proceed to the next step of management that is endoscopy because of her condition. We didn't have facilities of angiography, radionuclide scanning and on table endoscopy. Ultimately we had to proceed to exploratory laparotomy.

The things came out to be different on exploration from the one which we were suspecting beforehand. Abdomen was opened with the suspicion of intraluminal source of bleeding that would have been a tedious work to locate. But we found an extra-luminal source of bleeding, a spurting vessel in the wall of gall bladder pouring its blood directly into an anterior duodenal perforation in its first part and the sealing of the perforation by the gall bladder so that no blood or

gut contents were spilled into the peritoneal cavity. The duodenal perforation eroding into the gall bladder wall has opened up a branch of the cystic artery causing this tricky presentation of upper GI bleeding. In the scenario of Crohn's disease, it was further suspected that this perforation might be a manifestation of Crohn's, that's why a biopsy was taken from the margins of the perforation followed by omentopexy and cholecystectomy. The histopathology showed it to be nonspecific inflammation and not a manifestation of Crohn's disease. As far as we have searched the literature, we could not find any case reported regarding such a rare and unusual cause of upper GI bleeding.

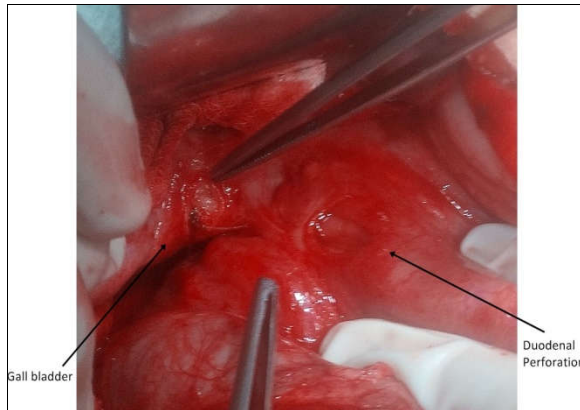


Figure: Per-operative view of perforation site

REFERENCES

1. Beck DE, Margolin DA, Whitlow CB, Hammond KL. Evaluation and management of gastrointestinal bleeding. *Ochsner J* 2007;7(3):107-13.
2. Billingham RP. The conundrum of lower gastrointestinal bleeding. *Surg Clin North Am* 1997;77(1):241-52.
3. Kovacs TO, Jensen DM. Recent advances in the endoscopic diagnosis and therapy of upper gastrointestinal, small intestinal, and colonic bleeding. *Med Clin North Am* 2002;86(6):1319-56.
4. Jensen DM, Machicado GA. Diagnosis and treatment of severe hematochezia. The role of urgent colonoscopy after purge. *Gastroenterology* 1988;95(6):1569-74.
5. Wu LM, Xu JR, Yin Y, Qu XH. Usefulness of CT angiography in diagnosing acute gastrointestinal bleeding: a meta-analysis. *World J Gastroenterol* 2010;16(31):3957-63.
6. Junquera F, Quiroga S, Saperas E, Pérez-Lafuente M, Videla S, Alvarez-Castells *et al.* Accuracy of helical computed tomographic angiography for the diagnosis of colonic angiodysplasia. *Gastroenterology* 2000;119(2):293-9.
7. Barnert J, Messmann H. Diagnosis and management of lower gastrointestinal bleeding. *Nat Rev Gastroenterol Hepatol* 2009;6(11):637-46.
8. Fallah MA, Prakash C, Edmundowicz S. Acute gastrointestinal bleeding. *Med Clin North Am* 2000;84(5):1183-208.
9. Bender JS, Wiencek RG, Bouwman DL. Morbidity and mortality following total abdominal colectomy for massive lower gastrointestinal bleeding. *Am Surg* 1991;57(8):536-40.
10. Vernava AM 3rd, Moore BA, Longo WE, Johnson FE. Lower gastrointestinal bleeding. *Dis Colon Rectum* 1997;40(7):846-58.

Address for correspondence:

Dr Kishwar Ali, Department of General Surgery, Ayub Teaching Hospital, Abbottabad-Pakistan

Cell: +92 333 947 4480

Email: drkaish1@gmail.com