

**CASE REPORT****LEFORT'S COLPOCLIESIS IN ELDERLY WOMEN HAVING PELVIC ORGAN PROLAPSE AND MEDICAL COMORBIDITIES****Uzma Khatoon, Aziz un Nisa Abbasi**

Department of Gynaecology and Obstetrics, Ayub Medical College, Abbottabad-Pakistan

Lefort's colpocliesis is surgery done in patients having pelvic organ prolapse associated with medical co-morbidities. Added to this it is done in elderly patients no more interested in marital relations. This procedure is not commonly done in our setup and there are few case reports in our region. We have very few successful case of this procedure. Here we are presenting a report of successful repair. This elderly lady presented to us with chief complaints of 3<sup>rd</sup> degree prolapse. She was diagnosed as a cardiac patient after proper investigation, so she was unfit for general anaesthesia and major surgery. Ultimately she was operated upon Lefort's procedure. On her first follow-up visit she was having healthy wound and good satisfaction.

**Keywords:** Lefort's colpocliesis, medical co-morbidities

J Ayub Med Coll Abbottabad 2015;27(3):723-4

**INTRODUCTION**

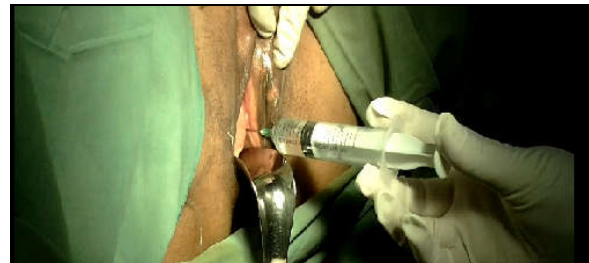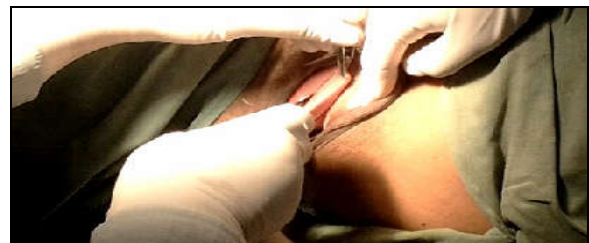
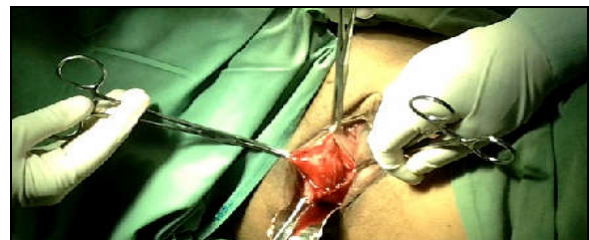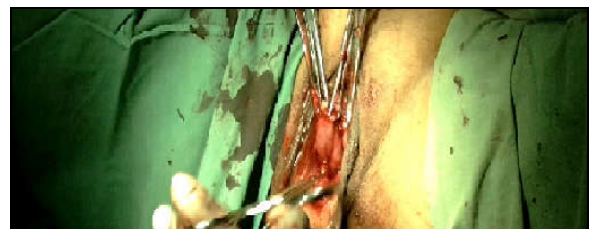Colpocliesis is derived from Greek words colpos means folds or hollow and cliesis means obliteration or closure.<sup>1</sup> Colpocliesis is an operation which treats the symptoms of prolapse by sewing the front and back wall of vagina together.<sup>2</sup> This prevents the vaginal walls from bulging either into or outside vagina and supports uterus if present.<sup>2</sup>

First report of Colpocliesis occurred in 1823 when Gerardin described denuding the anterior and posterior vaginal walls at the introitus and resuturing them. The technique currently used is a modification first described in 1877 by Leon Lefort.<sup>1</sup> It can be performed under local, epidural or spinal anaesthesia and general anaesthesia is not required. It is a quick procedure requiring only 45 minutes with minimal postoperative pain and complications. It can be coupled with tension-free vaginal tape (TVT) sling operation.<sup>3</sup>

**CASE REPORT**

An 85 years old woman was admitted through OPD in Gynaecology "A" Unit of Ayub Teaching Hospital, Abbottabad with third degree uterovaginal prolapse. She was para seven, all alive and vaginal deliveries. She was 12 years post-menopausal with complaints of pressure premium, something coming out of vagina for 5-6 years that got worse with time. She had associated complaints of backache and difficulty in daily life activities with no previous surgical history. She was prepared for vaginal hysterectomy.

All baseline investigations were normal. ECG showed left bundle branch block (LBBB). Anaesthetist declined to give Anaesthesia due to cardiac problem. We planned minimal surgery under local anaesthesia. Lefort's Colpocliesis done under local anaesthesia by the Professor (Figures 1-4). She was sent home with healthy wound.

**Figure-1: Local anaesthesia****Figure-2: Incision in anterior vaginal wall****Figure-3: Resection of redundant tissue****Figure-4: Approximation of anterior & posterior vaginal wall**

## DISCUSSION

It is estimated that nearly 50% of all women between age of 50 and 79 have some form of prolapse. The life time risk of having surgery for prolapse or incontinence by age of 80–85 is 11–19% with 30% requiring additional prolapse procedure.<sup>1</sup> Patients with pelvic organ prolapse can have extensive pelvic surgery or complex surgeries like abdominal sacropexy, sacrospinous fixation, ilioococcygeous fixation or simple obliterative procedures. Simple obliterative procedures can be of two types: one is partial Colpocleisis technique, second is total Colpocleisis. Partial Colpocleisis include partial obliteration of vagina plus perineorrhaphy also called as Lefort Colpocleisis. This procedure is recommended for women having uterus and any bleeding from uterus can come out through lateral tunnels of vagina. Second procedure is total Colpocleisis in which vagina is completely obliterated. This procedure is recommended in patients with absent uterus like vault prolapse.<sup>1</sup>

Obliterated procedure is an effective option for women who decline or there is failure of conservative therapy, frail elderly menopausal women unfit for anaesthesia due to medical comorbidities who cannot tolerate extensive reconstructive surgery, and lastly who are not planning future vaginal intercourse<sup>4</sup>. In le Fort colpocleisis, anatomical success rate was 98.1% and patients were highly satisfied, with 92.9% reported being “cured” or greatly improved.<sup>5</sup>

Although Colpocleisis has many medical and surgical advantages, there are some disadvantages like women undergone this surgery will no longer be able to have sexual intercourse that has its own psychological implications. Secondly, if

patient has vaginal bleeding where uterus is present, evaluation of the problem may be difficult because uterus will be no longer accessible. Thirdly, there can be recurrence. Lastly, patient has slightly increased risk of urinary incontinence due to change in anatomy of the urethra and bladder after surgery. Additionally, there are routine operative risks of infection, bleeding, damage to nearby organs in surgical field.<sup>6</sup>

There are few contraindications of Colpocleisis like cardiopulmonary risk factors, cervical and uterine pathology requiring extensive surgical resection and staging of dices, positive Pap smear and post menopausal bleeding.<sup>1</sup>

## REFERENCES

1. Plowright LN, Davila GW. Colpocleisis: Background, Indications, Contraindications [Internet]. [cited 2015 Jul 31]. Available from: <http://emedicine.medscape.com/article/2047195-overview>
2. International Urogynecological Association (IUGA). Colpocleisis: A guide for women. [Internet]. [cited 2015 Jul 31]. Available from: [http://c.ymcdn.com/sites/www.iuga.org/resource/resmgr/brochures/eng\\_colpocleisis.pdf?hhSearchTerms=%22resource%22fresmgr%2fbrochures%2feng\\_colpocleisis%22](http://c.ymcdn.com/sites/www.iuga.org/resource/resmgr/brochures/eng_colpocleisis.pdf?hhSearchTerms=%22resource%22fresmgr%2fbrochures%2feng_colpocleisis%22)
3. Miklos JR. Colpocleisis (Lefort Procedure) - Vaginal Prolapse Treatment [Internet]. [cited 2015 Jul 31]. Available from: <http://www.miklosandmoore.com/prolapse/vault/colpocleisis-lefort.php>
4. Jelovsek JE, Brubaker L, Eckler K. Pelvic organ prolapse in women: Choosing a primary surgical procedure [Internet]. [cited 2015 Jul 31]. Available from: <http://www.uptodate.com/contents/pelvic-organ-prolapse-in-women-choosing-a-primary-surgical-procedure>
5. Zebede S, Smith AL, Plowright LN, Hegde A, Aguilar VC, Davila GW. Obliterative LeFort colpocleisis in a large group of elderly women. *Obstet Gynecol* 2013;121(2 Pt 1):279–84.
6. Women's Health Specialists. COLPOCLEISIS. [Internet] [Cited 2015 Jul 31]. Available from: <http://www.whsobgyn.com/gyn-m-colpocleisis.html>

### Address for Correspondence:

**Dr. Uzma Khatoon**, Department of Gynaecology and Obstetrics, Ayub Teaching Hospital Abbottabad-Pakistan

**Cell:** +92 333 503 8628

**Email:** mahnoor786.mk@gmail.com