

## ORIGINAL ARTICLE

## EXCHANGE NAILING FOR NON-UNION OF FEMORAL SHAFT FRACTURES

Mohammad Naeem-ur-Razaq, Muhammad Qasim\*, Shahid Sultan

Department of Orthopaedics, Ayub Medical College, Abbottabad, \*Department of Plastic and Reconstructive Unit, Hayatabad Medical Complex, Peshawar, Pakistan

**Background:** There are many ways to treat aseptic non-union of femoral shaft fractures with reported varied success rate. Amongst all these, Exchange nailing is the simplest and most successful technique for treating aseptic non union of femoral shaft fractures. We have carried out a prospective study in the Department of Trauma & Orthopaedics, Ayub Medical College Abbottabad to analyse the role of exchange nailing for aseptic non union of femoral shaft fractures. **Methods:** Forty-three femoral shaft aseptic non-unions in 41 consecutive patients were treated using exchange IM nailing, from January 2006 to December 2007. The inclusion criteria for patients in the study was a femoral shaft fractures' aseptic non-union, has less than 1 Cm shortening with no segmental bone defect, and a radiolucent line of the non-union, and which had previously been treated by intra-medullary nail. The surgical technique included removal of previously inserted intra-medullary nail, reaming of medullary cavity up to 2 mm above the previous size, and re-insertion of statically locked exchange intra-medullary nail. **Results:** Forty-three femoral shaft aseptic non-union in 41 patients were treated; the mean age of the patients was  $38.81 \pm 13.75$  years. Thirty-nine non-union out of total 43 cases (39/43) had healed giving a union rate of 90%. Non-union persisted in the remaining four cases (4/43) in spite of extended post operative follow up of these patients for 18 months. Mean union was  $4.97 \pm 1.53$  months. No major surgical complications were noted. **Conclusion:** Exchange nailing is a simple technique for treating aseptic non union of femoral shaft fractures. Based on the results of our study, we recommend it as the procedure of choice for non comminuted, aseptic non union of femoral shaft fracture.

**Keywords:** Aseptic non-union, femoral non-union, exchange interlocking intra-medullary nailing

## INTRODUCTION

Exchange IM nailing for the treatment of a non-united long bone fracture involves removal of the current IM nail, reaming of the medullary canal, and placement of a new larger diameter IM nail.<sup>1,2</sup>

Femur fractures are commonplace due to increasing exposure to environmental and professional hazards during work and leisure activities. Treatment of femoral shaft fractures has evolved with time. However surgeons around the world currently treat these fractures which are either closed or grade 1 or 2 Gustilo type open fractures, by closed interlocking IM nails with high success rate in terms of fracture healing and fewer complications.<sup>3</sup> Even severe open femoral shaft fractures which have been initially fixed with external fixator may later be converted to reamed interlocking IM nails as advocated by many authors.<sup>4,5</sup> Although, a high union rate with a low complication rate can be achieved with closed intra-medullary nailing of long bone fractures like femur. Closed interlocking IM nailing of these fractures necessitates use of image intensifier and costlier fracture table which are not ready to hand in many hospitals in the developing countries. Under the circumstances many orthopaedic surgeons from these countries still carry out open IM nailing for these fractures with resultant increase in the rate of non-union.<sup>6</sup>

Non-union of fractures shaft femur are not uncommon. The non-union leads to serious morbidity

and considerable family burden. Many orthopaedic surgeons are faced with dilemma as to effective treatment for the non-union of femoral shaft fractures. Treatment options range from bone grafting alone to plate osteosyntheses and IM nailing with or without supplementary bone grafting to the now widely practiced closed exchange interlocking IM nail.<sup>7,8</sup> Many researchers believe that exchange interlocking IM nailing is safe, simple and cost effective way of addressing this issue, and has yielded high success rate with few complications.<sup>9,10</sup>

Exchange closed interlocking nailing provides biological and mechanical effects that promote osseous healing. Reaming of the medullary canal leads to increased periosteal blood flow, stimulates periosteal new-bone formation, and delivers internal bone graft to the non-union site, all in turn aid in healing of the non-union.<sup>11</sup> likewise improved mechanical stability due to use of larger size IM nail also leads to accelerated healing at the non-union site.<sup>11,12</sup>

High incidence of femoral shaft fractures and their non-union plus paucity of research study on the issue has prompted us to carry out a prospective study on exchange interlocking IM nailing on the perplexing issue of aseptic non-union fractures shaft of femur which have failed to heal by the prior IM nails.

The aim of this study was to determine the management outcome of non-union femoral shaft

fractures with exchange interlocking nailing in term of radiological bone healing.

## MATERIAL AND METHODS

Forty-three consecutive cases of non-union fractures shaft of femur were admitted to the Department of Trauma and Orthopaedics, Ayub Teaching Hospital/ Ayub Medical College, Abbottabad. This hospital-based descriptive study recruited patients from January 2006 to December 2007, and their informed consent obtained for the procedure.

### Inclusion criteria

1. All male and female patients who were aged 13 years and above
2. All patients who had initially closed post traumatic fractures of the shaft femur
3. All patients who had one or more times previous surgical treatment done for the fracture
4. All patients had last surgery for the fracture in the preceding 9–12 months in the form of IM nailing, (either K-nail or interlocking nail)
5. All patients had aseptic hypertrophic or atrophic non-union on clinical and radiological assessment performed at 9 months or later after the last surgery
6. All patients had less than 1 Cm shortening and no bone comminution or bone loss at the time of study

### Exclusion criteria

1. Patients with infected non-unions
2. Patients who had segmental bone defects greater than one cm
3. Patients with bent or broken IM nail/Interlocking nail which had required open removal.

Patients were given either general anaesthetic (GA) or spinal anaesthetic, positioned supine on fracture table. Both lower limbs were put in traction in a way to allow use of image intensifier for the procedure. A small incision was given extending five cm up from the tip of greater trochanter. A guide wire inserted into the medullary canal of femur antegrade way, previous IM nail was removed, and medullary canal of the femur reamed in gradual increments up to 2 mm above the previous nail size using flexible reamers. Lastly a proper size interlocking IM nail, one mm smaller diameter than the last reamer used, was inserted over the guide wire using interlocking nail assembly. Proximal locking was done using the jig and distal screws for locking were inserted free hand way under image intensifier. We used static interlocking for all the cases in our study in order to provide added stability to the construct.

Patients were given intravenous antibiotics, i.e., 1.5 gram of Cefuroxime and 80–120 mg of Gentamicin at induction of anaesthesia. These antibiotics were continued for five to seven days postoperatively. Check x-ray of the operated site for all patients were done on the 1<sup>st</sup> postoperative day to

reconfirm fracture reduction and nail locking, counselling of and showing it to patients, and as guideline for comparison with later x-rays during follow-up period. Postoperatively, all patients were permitted to ambulate with protected weight bearing as soon as possible. Quadriceps as well as knee range of motion exercise was encouraged. Patients were discharged home on 3<sup>rd</sup> to 5<sup>th</sup> postoperative day. All operated patients were followed-up in the outpatient department at 2 weeks for suture removal and wounds examination. Patients were followed up subsequently for clinical and/or radiological check up at one month intervals for minimum period of one year after the surgery or till time when bone healing at non-union site has occurred. The fracture showing radiological evidence of healing, as confirmed by independent radiologist, was considered healed. Data regarding patients' age and gender and other characteristics like femur fracture location, type of non-union as to whether hypertrophic or atrophic and injured side as to left or right, duration of fracture healing after exchange interlocking nailing, period of postoperative follow up period and complication were recorded and analysed using SPSS-10.

## RESULTS

Forty-three non-union cases were treated with exchange interlocking IM nail in one year study time. The patients' age was  $38.81 \pm 13.75$  years. The age graph shows predominantly bimodal age distribution of fracture femur with peak concentrations around age groups of 31 and 52 years as shown in Figure-1. The male to female ratio was 2.34:1. Fractures were more common on left side than right (Table-1). The type of non-union of femur and its correlation with bone healing using pre- and postoperative x-rays of the femur was analysed. The analysis shows better healing in hypertrophic non-union than in atrophic ones (Table-2). Postoperative follow-up period ranged from 6 to 18 months (Mean  $10.19 \pm 1.99$  months). Thirty-nine out of 43 cases (90%) healed uneventfully in a mean period of  $4.97 \pm 1.53$  months (Range, 3–10 months). Except for 4 out of 43 cases (10%) of persistent non-union, no significant complications occurred as shown in Table-3.

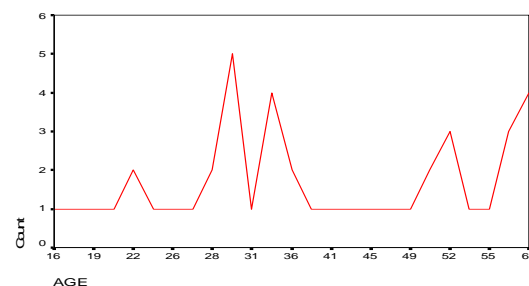


Figure-1: Age-wise bimodal distribution with high incidence of fracture

**Table-1: Location of femur fracture site**

Location	Frequency	Percent
Left	24	55.8
Right	19	44.2
Total	43	100.0

**Table-2: Non-union type and its correlation with healing**

Non-union Type	Healing after exchange interlocking nailing		Total
	Non-union	united	
Hypertrophic	1	14	15
Atrophic	3	25	28
Total:	4	39	43

**Table-3: Complication of exchange interlocking nailing**

Minor Complications	Frequency	Percent
Discolour	3	7.0
Pain	8	18.6
Swelling	6	14.0

## DISCUSSION

A non-union of long bones including that of shaft femur is a difficult proposition for orthopaedic surgeons. It has posed challenges to treating doctors over the years and still continues to be a dilemma. Femur being the strongest and the longest bone in the body, it not only takes the brunt of loads during everyday life, its fracture has serious morbidity like non-union. Such morbidity adds to family's burden too.

Many treatment modalities from non-operative to range of surgical options have been tried for treating this difficult issue. Based on vascularity and osteogenic potential of fracture fragments' ends, Non-union has been classically classified into two types, i.e., hypertrophic (hyper-vascular) type and atrophic (avascular) type. This classification has both prognostic and treatment significance. The hypertrophic type has good healing potential and is often the result of poor fixation or loss of stability at fracture site. It benefits from stable fixation. The avascular type of non-union lacks osteogenic potential beside loss or lack of stability at the fracture site and requires bone grafting in addition to stable fixation.<sup>13</sup> During the past several years, methods for non-union treatment have continuously developed.<sup>14-17</sup> Various non-operative or operative techniques are available. However, maintenance of sufficient stability with supplementation of cancellous bone grafts has been the most convincing and has achieved the highest success rate. According to reports in the literature, Exchange Intra-Medullary Nailing provides both stable fixation and internal bone grafts to the non-union site and is the superior method of treatment for femoral shaft non-union.<sup>18,19</sup>

Our data suggest that exchange interlocking nailing is effective in achieving union in both hypertrophic and atrophic non-union cases of femoral shaft fractures. Our study support the literature review

of Brinker *et al*<sup>20</sup> that exchange nailing of an atrophic non-union may stimulate a healing response in addition to augmenting mechanical stability. Our study also supports the reports by other authors that hypertrophic non-union is best treated by exchange nailing because it augments mechanical stability at the non-union site which is the major factor for achieving osseous union.<sup>13</sup>

The reported success rate of exchange nailing to treat femoral shaft delayed unions or non-unions is 53–100%.<sup>21,22</sup> Our data shows a healing rate of 90% for non-union of shaft femur fractures. In a study by Templeman *et al*<sup>23</sup> on 27 diaphyseal tibial non-unions that underwent exchange nailing, 23 healed following one exchange nailing and two healed following a second exchange nailing. The two remaining non-unions were associated with bone loss exceeding 30% of the cortical diameter. These non-unions underwent one exchange nailing and healed following a subsequent bone grafting procedure. Our study result shows that 39 patient healed uneventfully while 4 patients had failed to unite even at the end of extended follow up for 18 months in these patients. Repeat or second exchange femoral interlocking nailing with or without bone grafting was not performed for any of these four patients due to patients' non-compliance for the same procedure even after considerable counselling.

The advantages of closed interlocking exchange IM nailing have been advocated. The procedure entails only small wound(s) for nail and screws insertion with consequent shorter surgery time, lesser bleeding and wound complications.<sup>13</sup> Our data concord with Yu *et al*<sup>13</sup> as our study shows minimal complications (Table-3).

Factors favouring fracture healing are minimal gap at non-union site, provision of adequate stability, and blood supply to the fracture fragments' ends.<sup>14</sup> The size of bone defects can affect the union rate.<sup>9,24</sup> Our study support other authors' findings that exchange ILN enhances bone healing by both augmenting mechanical stability and providing internal bone graft at the non-union site provided there is lesser than one cm defect at the non-union site.

Our study support that reaming of medullary canal, for 2 mm above the previously used nail size, provides copious amount of bone graft at the non union site if the bone loss at non-union site is less than 1 Cm. This finding concords with other literature reports.<sup>8,25</sup> This study has used only static locking for exchange nailing and healing response is comparable to the other study.<sup>18</sup> Although a dynamic locked nail can provide the compressive force and further promotes fracture healing, dynamically locked exchange nailing was not found superior to the statically locked nailing.<sup>8</sup> According to the study of Wu *et al* study that with cancellous bone grafts to promote fracture healing, the

added compressive force does not seem to be so critical.<sup>18</sup>

The methods for treatment of persistent non-union after exchange nailing are many and all methods have individual advantages and disadvantages.<sup>13</sup> Our study has not included those 4 patients who showed persistent non-union in spite of the first exchange interlocking nailing procedure due to compliance reasons. Repeated exchange nailing has been reported with success and technique is the simplest.<sup>8,9</sup> As for conversion to plating, a large wound with extensive soft tissue dissection may introduce more complications.<sup>26,27</sup>

Though our study has focused only on aseptic non-union exchange nailing but literature review showed that many authors have used exchange nailing to treat infected non-union and have shown success.<sup>38</sup> In principle, exchange nailing should not be used in patients with acute infections. For those with acute infections, staged operations with conversion to external fixation may be more suitable.<sup>24-28</sup>

## CONCLUSION

Exchange femoral interlocking intra-medullary nailing is a simple technique with minimal complications. Therefore this treatment modality should be considered as the treatment of choice for aseptic, non-comminuted diaphyseal femoral non-unions which have bone gap of less than 1 Cm. We recommend static locked exchange interlocking intra-medullary nailing for the mentioned aseptic non-union of femoral fracture.

## REFERENCES

1. Court-Brown CM, Christie J, McQueen MM. Closed intramedullary tibial nailing. Its use in closed and type I open fractures. *J Bone Joint Surg Br* 1990;72:605-11.
2. Court-Brown CM, Keating JF, Christie J, McQueen MM. Exchange intra medullary nailing. Its use in aseptic tibial nonunion. *J Bone Joint Surg Br* 1995;77:407-11.
3. Herscovici D Jr, Ricci WM, McAndrews P, DiPasquale T, Sanders R. Treatment of femoral shaft fracture using unreamed interlocked nails. *J Orthop Trauma* 2000;14:10-4.
4. Grosse A, Christie J, Taglang G, Court-Brown C, McQueen M. Open adult femoral shaft fracture treated by early intramedullary nailing. *J Bone Joint Surg Br* 1993;75:562-5.
5. Brien PJ, Meek RN, Powell JN. Primary intramedullary nailing of open femoral shaft fractures. *J Trauma* 1991;31:113-6.
6. Kempf I, Grosse A, Beck GF. Closed locked intramedullary nailing: its application to comminuted fractures of the femur. *J Bone Joint Surg Am* 1985;67:709-20.
7. Carlo B, William MR, Brett RB. Results of indirect reduction and plating of femoral shaft nonunions after intramedullary nailing. *J Orthop Trauma* 2001;15:254-63.
8. David JH, Stanley SL, James AG. Success of exchange reamed

- intramedullary nailing for femoral shaft nonunion or delayed union. *J Orthop Trauma* 2000;14:178-82.
9. Oh I, Nahigian SH, Rascher JJ, Farrall JP. Closed intramedullary nailing for ununited femoral shaft fractures. *Clin Orthop* 1975;106:206-15.
10. Webb LX, Winqvist RA, Hansen ST. Intramedullary nailing and reaming for delayed union of the femoral shaft. *Clin Orthop* 1986;212:133-41.
11. Danckwardt LG. Reaming of the medullary cavity and its effect on diaphyseal bone. A fluorochromic, microangiographic and histologic study on the rabbit tibia and dog femur. *Acta Orthop Scand Suppl* 1969;128:1-153.
12. Whiteside LA, Ogata K, Lesker P, Reynolds FC. The acute effects of periosteal stripping and medullary reaming on regional bone blood flow. *Clin Orthop Relat Res* 1978;131:266-72.
13. Yu CW, Wu CC, Chen WJ. Aseptic Nonunion of a Femoral Shaft Treated Using Exchange Nailing. *Chang Gung Med J* 2002;25:191-8.
14. Wu CC. The effect of dynamization on slowing the healing of femur shaft fractures after interlocking nailing. *J Trauma* 1997;43:263-7.
15. Matelic TM Wang CJ, Chen HS, Chen CE, Yang KD. Treatment of nonunions of long bone fractures with shock waves. *Clin Orthop* 2001;381:95-101.
16. Bhandari M, Schemitsch EH. Clinical advances in the treatment of fracture nonunion: the response to mechanical stimulation. *Curr Orthop* 2000;11:372-7.
17. Nolte PA, van der Krans A, Patka P, Janssen IMC, Ryaby JP, Albers GHR. Low-intensity pulsed ultrasound in the treatment of nonunions. *J Trauma* 2001;51:693-703.
18. Wu CC, Chen WJ. Treatment of femoral shaft aseptic nonunions: comparison between closed and open bone grafting techniques. *J Trauma* 1997;43:112-6.
19. Perry CR. Bone repair techniques, bone graft, and bone graft substitutes. *Clin Orthop* 1999;360:71-86.
20. Mark RB, Daniel PO. Exchange Nailing of Ununited Fractures. *J Bone Joint Surg Am* 2007;89:177-88.
21. Weresh MJ, Hakanson R, Stover MD, Sims SH, Kellam JF, Bosse MJ. Failure of exchange reamed intramedullary nails for ununited femoral shaft fractures. *J Orthop Trauma* 2000;14:335-8.
22. Wu CC, Shih CH, Chen WJ, Tai CL. Treatment of ununited femoral shaft fractures associated with locked nail breakage: comparison between closed and open revision techniques. *J Orthop Trauma* 1999;13:494-500.
23. Templeman D, Thomas M, Varecka T, Kyle R. Exchange reamed intramedullary nailing for delayed union and nonunion of the tibia. *Clin Orthop Relat Res* 1995;315:169-75.
24. Wei FC, El-Gammal TA, Lin CH, Ueng WN. Free fibula osteoseptocutaneous graft for reconstruction of segmental femoral shaft defects. *J Trauma* 1997;43:784-92.
25. Ahmad A, Saleh M, Hashmi M. Effects of smoking on healing of nonunions in long bones. *J Bone Joint Surg Br* 2001;83:230.
26. Wu CC. Treatment of femoral shaft aseptic nonunion associated with plating failure: emphasis on the situation of screw breakage. *J Trauma* 2001;51:710-3.
27. Carlo B, William MR, Brett RB. Results of indirect reduction and plating of femoral shaft nonunions after intramedullary nailing. *J Orthop Trauma* 2001;15:254-63.
28. Wolinsky P, Tejwani N, Richmond JH, Koval KJ, Egol K, Stephen DJG. Controversies in intramedullary nailing of femoral shaft fractures. *J Bone Joint Surg Am* 2001;83:1404-15.

## Address for Correspondence:

Dr. Mohammad Naem-Ur-Razaq, Durrani House, Street-8, Tajabad Town, Jamrud Road, Peshawar-25000, Pakistan.

Tel: +92-91-5842817, Cell: +92-314-9051883

Email: mqdurrani@gmail.com