

CASE REPORT

BAND HETEROTOPIA

Alam MS, Naila N

Department of Radiology, Aga Khan University Hospital, Karachi, Pakistan

Band heterotopias are one of the rarest groups of congenital disorder that result in variable degree of structural abnormality of brain parenchyma. Band of heterotopic neurons result from a congenital or acquired deficiency of the neuronal migration.¹ MRI is the examination of choice for demonstrating these abnormalities because of the superb gray vs. white matter differentiation, detail of cortical anatomy and ease of multiplanar imaging.² We report a case of band heterotopia that showed a bilateral band of gray matter in deep white matter best demonstrated on T2 Wt. and FLAIR images.

Keywords: Heterotopia, congenital, deep white matter

INTRODUCTION

Band heterotopia is a type of neuronal migration disorder.³ Neuronal migration is the process in which neurons move from their place of origin to their permanent location. When this process is disrupted, the result is a structurally abnormal brain and can involve the cerebral hemispheres, cerebellum, or brainstem.¹ Band heterotopia forms in the white matter beneath the cortex and may be complete, surrounded by simple white matter, or partial.³

CASE REPORT

This is a case of a 15-year-old girl who was referred to the Neurology Consulting clinic AKU with history of seizures on and off which were of grand mal variety. At presentation she was mentally slow with low IQ. She had history of seizures for last 10 years. Her neurological examination showed decrease tone and power in all four limbs. Her motor and cranial nerve examination was normal. She had been given some medication by some local doctors where she lives but her symptoms persist.

In Aga Khan University Hospital, various hematological and urinary tests were performed but all were within normal limits.

MRI scan of the brain was also ordered which shows a heterotopic band of gray matter located in deep white matter in the cerebral cortex bilaterally. This band is surrounded by normal white matter laterally and medially. No post contrast enhancement noted. No other significant abnormality observed on this scan. Based on this finding, diagnosis of band heterotopia was made which is a rare entity.

After the diagnosis was made, patient was started on oral carbamazepine and now for last 2 months, she does not have any seizure episode.

DISCUSSION

During gestation, successive waves of primitive neuroblasts migrate from the germinal matrix to form the cerebral cortex and deep nuclei of the brain

between two and four month.¹ Gray matter heterotopias are collections of normal neurons in abnormal locations that result from arrest of radial migration of these neuroblasts.² Band heterotopias are one of the rarest varieties of neuronal migration disorder. They usually appear as band of gray matter situated between the lateral ventricle and cerebral cortex and separated from both by a layer of normal appearing cortex. Band may be complete surrounded by simple white matter or partial.³

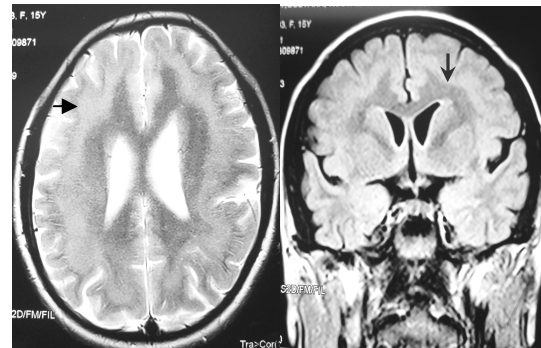


Figure-1: Heterotopic band of gray matter located in deep white matter bilaterally

These patients usually present with behavior problems and seizure disorders.⁴ Radiological Imaging can help in identifying extent of the lesion and MRI is the examination of choice for demonstrating these abnormalities because of the superb gray vs. white matter differentiation, detail of cortical anatomy and ease of multiplanar imaging.⁵ Antenatal imaging especially fetal MRI would be helpful in antenatal diagnosis of these lesions where suspicion is high.⁶

In the present case, patient antenatal history was insignificant. She presented with on and off history of grand mal epileptic seizures for last 10 years and not responded with antiepileptic medications. Prior, no imaging was performed and MR imaging clearly demonstrate heterotopic band of gray matter in the region of deep white matter bilaterally.

This is a rare entity as very few cases of band heterotopia are reported in the literature. Barkovich *et al*³ in 1989 reviewed more than 20,000 MR studies of the brain showed that five have imaging characteristic of band heterotopia. It is important to identify these anomalies because of the poor prognosis and intractable nature of seizure disorders.

REFERENCES

1. Smith AS, Weinstein MA, Ross SJ, Blaser IS. Magnetic Resonance imaging of disturbances in neuronal migration: Illustration of an embryologic process. *Radiographics* 1989;9:509-22.
2. Barkovich AJ, Kjos B. Gray matter heterotopias: MR characteristics and correlation with developmental and neurological manifestations. *Radiology* 1992;182:483-99.
3. Barkovich AJ, Jackson DE Jr, Boyer RS. Band heterotopia: a newly recognized neuronal migration anomaly. *Radiology* 1989;71:455-8.
4. Smith AS, Weinstein MA, Quencer RM, Muroff LR, Stonesifer KJ, Li FC, *et al*. Association of heterotopic gray matter with seizures: MR imaging. *Radiology* 1988;168:195-8.
5. Barkovich AJ, Chaung SH, Norman D. MR of neuronal migration anomalies. *AJNR Am J Neuroradiol* 1987;8:1009-17.
6. Barkovich AJ. Subcortical heterotopia: a distinct clinico-radiologic entity. *AJNR Am J Neuroradiol* 1996;17:1315-22.

Address for Correspondence:

Dr. Naila Nadeem, Assistant Professor, Department of Radiology, Aga Khan University Hospital, Stadium Road, Karachi, 74800, Pakistan. **Cell:** +92-300-2007345
Email: naila.nadeem@aku.edu