

## FREQUENCY OF OCULAR MANIFESTATIONS OF CHRONIC GRAFT VERSUS HOST DISEASE

Muhammad Aamir Arain, Muhammad Khizar Niazi, Muhammad Dawood Khan, Parvez Ahmed\*, Muhammad Afzal Naz, Muhammad Fayyaz

Armed Forces Institute of Ophthalmology Rawalpindi, \*Armed Forces Bone Marrow Transplantation Centre, Rawalpindi

**Background:** With the advancement of techniques for haematopoietic cell transplantation, the number of transplant survivors is increasing rapidly and so are the chances of chronic graft versus host disease (cGVHD). The ocular manifestations of this disease have not been explored in our local population. This study was conducted to determine the frequency of ocular complications in cases of cGVHD following successful bone marrow transplantation. **Methods:** Twelve diagnosed cases of cGVHD were evaluated from June 2008 to March 2009 and their ocular manifestations were noted especially the ocular surface disorders, using double staining method with fluorescein and rose-bengal. **Results:** Nine patients (75%) were having dry eyes, 7 (58.3%) with meibomian glands dysfunction, 4 (33%) with acute conjunctivitis, 2 (16.7%) with bilateral lacrimal canalicular occlusion, and 1 (8.3%) each of bilateral posterior subcapsular cataract, unilateral sterile corneal epithelial defect, anterior uveitis, retinal haemorrhages and disc oedema. **Conclusion:** The higher frequency of dry eyes along with other ocular manifestations in patients of cGVHD suggests the need of close ophthalmic monitoring in all such cases.

**Keywords:** Dry eyes, chronic graft versus host disease, haematopoietic cell transplantation

### INTRODUCTION

The first successful haematopoietic cell transplantations (HCT) were performed in 1968 in three children with congenital immune deficiency diseases. Since then, thousands of patients have received HCT to treat life threatening malignant and non-malignant diseases. Current estimates of annual numbers of HCT are 45,000–50,000 worldwide.<sup>1</sup> In Pakistan HCT was started in last one decade.

The description of graft versus host disease (GVHD) was first given by Barne and Loutil in 1955. It results from a reaction of immunologically competent donor lymphocytes with recipient tissue. GVHD was divided into acute and chronic. Acute GVHD describes a syndrome of dermatitis, hepatitis and enteritis developing within 100 days of allogenic HCT. Chronic GVHD (cGVHD) describe a more pleotropic syndrome that develops after 100 days.<sup>2</sup> Seattle classified cGVHD into limited cGVHD and extensive cGVHD. The eye is involved in the later one.<sup>3</sup>

Most of the recipients of HCT are becoming long term survivors. Their quality of life and possibility of late ocular complications are becoming increasingly important.<sup>4</sup> In the study we had conducted, we evaluated all the patients being diagnosed as cGVHD at Armed Forces Bone Marrow Transplantation Centre Rawalpindi for ocular manifestations and found that majority of them were having severe dry eyes with Schirmer test of less than 5 mm wetting.

In Pakistan data only for skin manifestation of GVHD is available<sup>5</sup> while no study was ever conducted to find out the ocular manifestations of cGVHD in local population. Keeping this aspect in mind, we conducted a cross sectional descriptive study to determine the

frequency of ocular manifestations in patients with cGVHD after allogenic HCT.

### MATERIAL AND METHODS

The study was conducted at Eye Department, Military Hospital Rawalpindi, presently known as Armed Forces Institute of Ophthalmology Rawalpindi, in collaboration with Armed Forces Bone Marrow Transplantation Centre Rawalpindi from June 2008 to March 2009. We included twelve diagnosed cases of cGVHD patients based on Seattle classification by purposive sampling. After taking informed written consent of patients and approval of hospital ethical committee, patient's data was collected. After taking complete history, ocular examination was performed by taking the visual acuity and examining the anterior and posterior segments. Intraocular pressure was taken by applanation tonometry with fluorescein. Probing and sac syringing was done where epiphora was noted to ascertain the canalicular and nasolacrimal duct patency. The condition of ocular surface was evaluated by double staining method using fluorescein and rose-bengal strips.<sup>6</sup>

The degree of rose bengal staining was quantified on a scale of 0–3 points for temporal and nasal conjunctiva and the cornea (Figure-1). Fluorescein staining was also rated from 0–9 points but only for cornea.<sup>7</sup> Tear dynamics were assessed by 4 different methods including Tear break-up time (TBUT) (Figure-2), Schirmer test with and without nasal stimulation that was performed by applying cotton swab to nasal cavity and fluorescein clearance test (Figure-3). Three values each for TBUT and both

Schirmer test were obtained at the time of examination and their mean is taken to minimise false positive/negative errors. Blepharitis associated with infectious diseases, blink disorders and contact lens related tear film disorder were excluded from diagnosis of dry eye.<sup>8</sup>

To assess the obstruction of meibomian gland orifice, digital pressure was applied on the lower tarsus and expression of meibomian secretion (meibum) was scored as follows. Grade 0: Clear meibum, easily expressed. Grade-1: Cloudy meibum expressed with varying degree of pressure. Grade-2: Meibum not expressed even with heavy pressure.<sup>9</sup>

Diagnostic criteria for dry eye were:

- When patient had any sign of tear film instability, i.e., TBUT less than or equal to 5 seconds, Schirmer test less than or equal to 5 mm, and
- Any abnormality of ocular surface, i.e., rose bengal staining score more than or equal to 3, fluorescein staining score more than or equal to 1 and/or symptoms of ocular irritation.<sup>10</sup>

Global diagnostic criteria of dry eye proposed by Lemp<sup>11</sup> was used where dry eye was diagnosed as a disorder of tear film due to tear deficiency or excessive tear evaporation which caused damage to the interpalpebral ocular surface and was associated with or without symptoms of ocular discomfort.

For statistical analysis the mean age of our patients were calculated and expressed as Mean±SD. Frequencies for all variables were calculated. SPSS version 15.0 was used to analyse the data.

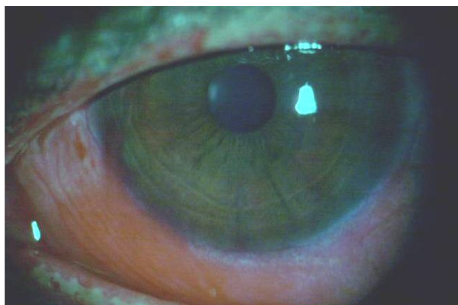


Figure-1: Rose Bengal Staining of Conjunctiva

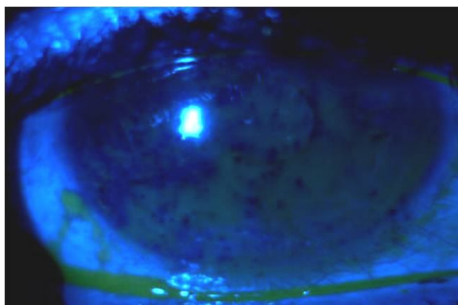


Figure-2: Tear film break-up time

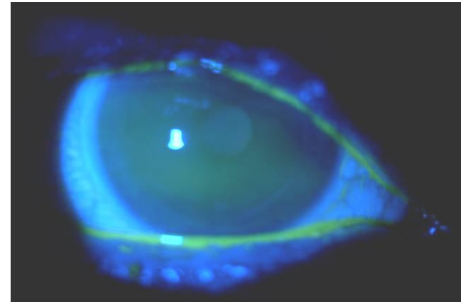


Figure-3: Fluorescein clearance test

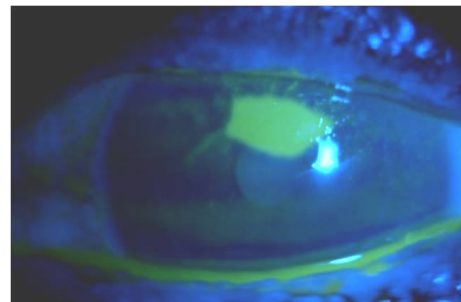


Figure-4: Sterile epithelial defect of cornea

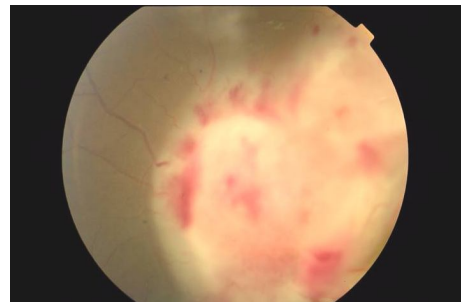


Figure-5: Disc oedema and retinal haemorrhage

## RESULTS

Twelve patients of cGVHD were evaluated for the ocular manifestations. Out of these 9 (75%) patients were having dry eye, 7 (58.3%) with meibomian glands dysfunction, 4 (33%) with acute conjunctivitis, 2 (16.7%) with bilateral lacrimal canalicular occlusion, 1 (8.3%) each of bilateral posterior subcapsular cataract, anterior uveitis, unilateral sterile corneal epithelial defect, retinal haemorrhages and disc oedema. The dry eye was the most common ocular manifestation of cGVHD. Meibomian gland dysfunction (MGD) was the second most common ocular manifestation of cGVHD after dry eye. All patients in our study, who had MGD, had also developed dry eyes.

The mean age of our patients was 40±17 years. All patients in our study were male and most probable reason is the higher cost of treatment and priority of males over females in our society. The results are summarised in Table-1.

**Table-1: Ocular Manifestations of cGVHD (n=12)**

Ocular Manifestations	Number	Frequency
Dry eyes	9	75.0%
Mebomian glands dysfunction	7	58.3%
Acute conjunctivitis	4	33.0%
Lacrimal canalicular occlusion	2	16.7%
Sterile corneal epithelial defect	1	8.3%
Posterior subcapsular cataract	1	8.3%
Anterior uveitis	1	8.3%
Retinal haemorrhages	1	8.3%
Disc oedema	1	8.3%

## DISCUSSION

In this study we have found that frequency of dry eye after onset of cGVHD in allogenic HCT was 75%. Liverey *et al* reported 81.8% dry eye in patients of cGVHD where conditioning was done by irradiation.<sup>12</sup> In our setup facility of total body irradiation (TBI) was not available and conditioning was done with immunosuppressant drugs including cyclosporin, methotrexate, mycophenolate mofetin and steroids. Fahnehjelson *et al* reported 61.6% prevalence of dry eye syndrome in children and young adults with allogenic HCT during childhood.<sup>13</sup> Fei *et al*<sup>14</sup> reported 57% dry eye in his study in China while Ogawa *et al*<sup>8</sup> reported 50% patients developing dry eye or their pre-existing dry eye worsened after developing cGVHD. Studies by Callissendoroff B *et al*<sup>15</sup>, Mencucci *et al*<sup>16</sup> and Tichelli A *et al*<sup>17</sup> also reported lesser frequency of dry eye than our study.

Reason why our patients showed higher frequency was due to the fact that in previous reports dry eye was diagnosed by simple methods while we used various modern diagnostic tests including Schirmer test with and without nasal stimulation and fluorescein/ rose bengal staining scores. Secondly our sample size was smaller and this might be the reason for increased frequency. Thirdly and most importantly our patients do not consult ophthalmologist unless they develop ocular discomfort. So our sample was mostly of those patients who had actually developed symptoms of dry eyes and then they consulted ophthalmologist. This resulted in falsely increase in frequency of patients with dry eye because many patients who were diagnosed as cGVHD and were told to consult an ophthalmologist by their treating physician do not report because of lack of awareness.

Mebomian glands functions were also impaired in patients with cGVHD. Our result of mebomian glands dysfunction (58.3%) is approx same as reported by Ogawa *et al* (47.8%).<sup>8</sup> Moreover all cases of MGD had also developed dry eyes. Our result signifies the importance of MGD in diagnosis of dry eyes thus allowing us to diagnose it earlier if regular follow up is done.

Bray LC *et al* reported 63% incidence of cataract in patients with allogenic bone marrow

transplant (BMT) after TBI and 9% incidence without TBI. All cataracts he reported were posterior subcapsular cataract in different grades.<sup>18</sup> We reported one case (8.3%) of posterior subcapsular cataract in Grade-IV. The patient was visually handicapped and was benefited from cataract surgery. The frequency of cataract in our study is same as reported earlier as the facility of TBI was not available in our setup.

Acute conjunctivitis (33%) was reported by us in comparison to 11.4% reported earlier. The higher frequency was probably due to smaller sample size and lack of ophthalmic consultation.<sup>8</sup> Similarly the frequency of bilateral anterior uveitis was 8.3% in our study. Anterior uveitis was reported in 3 patients after cGVHD by Hetting *et al*.<sup>19</sup> Our patient revealed no abnormalities on extensive uveitis screening and serological reports did not show any evidence of recent infection. No other explanation for anterior uveitis was found except for acute exacerbation of cGVHD after HCT.

Punctal occlusion and canalicular obstruction was seen in 2 patients (16.7%). Arain MA *et al* reported a case of bilateral lacrimal bicanalicular obstruction in cGVHD where all four canaliculi were obstructed resulting in epiphora. The patient was evaluated and found to have signs of dry eyes and his lacrimal by pass surgery was postponed. Thus all patients of cGVHD presenting with epiphora must be evaluated for signs of dry eyes before any surgery is contemplated.<sup>20</sup>

Sterile epithelial defects in cornea were seen in 1 patient (8.3%). Repeated conjunctival and corneal smears were negative and local antibiotics plus antiviral treatment showed no response. They were healed when bandage contact lens was placed along with preservative free artificial tears. Two such cases had been reported by Sprual *et al* where collagen shield was used.<sup>21</sup> Cases of corneal vascularisation have also been reported in literature<sup>22</sup> but none was observed in our study.

Kertl *et al*<sup>23</sup> reported 8 patients with retinal haemorrhages and 10 patients with bilateral disc oedema in patient after allogenic HCT. He reported this as manifestation of acute GVHD. Similarly case report of multifocal choroiditis after allogenic transplant has also been reported.<sup>24</sup> One of our patients had bilateral retinal haemorrhages along with disc oedema while diagnosis of cGVHD was made (Figure-5). His workup was negative for any other disease that could lead to such manifestations. It was probably due to the acute exacerbation of cGVHD.

## CONCLUSION

Dry eye is the most common ocular manifestation of cGVHD affecting the quality of life of all such patients. The higher frequency of dry eye along with other ocular complications suggests the need of close ophthalmic monitoring in all such patients.

## REFERENCES

1. Horowitz MM. Uses and growth of hematopoietic cell transplantation. In: Blume KG, Forman SJ, Appelbaum FR, eds. 3<sup>rd</sup> ed. Thomas' Hematopoietic Cell Transplantation. Oxford: Blackwell Science; 2004.p.9-13.
2. Sullivan KM. Graft-versus-host disease. In: Blume KG, Forman SJ, Appelbaum FR, eds. 3<sup>rd</sup> ed. Thomas' Hematopoietic Cell Transplantation. Oxford: Blackwell Science;2004.p.635-55.
3. Shulman HM, Sullivan KM, Weiden PL, McDonald GB, Striker GE, Sale GE, *et al.* Chronic graft-versus-host syndrome in man: a long-term clinicopathologic study of 20 Seattle patients *Am J Med* 1980;69:204-17.
4. Ogawa Y, Kuwana M, Yamazaki K, Mashima Y, Yamada M, Mori T, *et al.* Periductal area as the primary site for T-cell activation in lacrimal gland chronic graft-versus-host disease. *Invest Ophthalmol Vis Sci* 2003;44:1888-96.
5. Shahid J. Graft versus host disease (GVHD). *J Pak Assoc Derma* 1998;8(1):2-5.
6. Toda I, Tsubota K. Practical double staining for ocular surface evaluation. *Cornea* 1993;12:366-8.
7. Ban Y, Ogawa Y, Goto E, Uchino M, Terauchi N, Seki M, *et al.* Tear function and lipid layer alterations in dry eye patients with chronic graft-vs-host disease. *Eye* 2009;23(1):202-8.
8. Ogawa Y, Okamoto S, Wakui M, Watanabe R, Yamada M, Yoshino M, *et al.* Dry eye after haematopoietic stem cell transplantation *Br J Ophthalmol* 1999;83:1125-30.
9. Shimazaki J, Goto E, Ono M, Shimmura S, Tsubota K. Meibomian gland dysfunction in patients with sjogren syndrome. *Ophthalmology* 1998;105:1485-8.
10. Shimazaki J. Definition and criteria of dry eye. *Ganka (Japan)* 1995;37:765-70.
11. Lemp MA. Report of the National Eye Institute workshop on clinical trials on dry eye. *CLAOJ* 1995;21:221-32.
12. Livesey SJ, Holme JA, Whittaker JA. Ocular complication of bone marrow transplantation. *Eye* 1989;3:271-6.
13. Fahnehjelm KT, Tornquist AL, Winiarski J. Dry-eye syndrome after allogeneic stem-cell transplantation in children. *Acta Ophthalmol.* 2008;86:253-8.
14. Fei WL, Chen JQ, Du X, Liu YH, Sun MX, Lin JX, *et al.* Dry eye in graft-versus-host disease. *Zhonghua Yan Ke Za Zhi* 2003;39:686-90.
15. Calissendorff B, Azaz ME, Lonnqvist B. Dry eye syndrome in long term follow up of bone marrow transplanted patients. *Bone Marrow Transplant* 1989;4:675-8.
16. Mencucci, R, Ferrini, CR, Bosi, A, Volpe, R, Guidi, S, Salvi, G. Ophthalmological aspects in allogeneic bone marrow transplantation: Sjögren-like syndrome in graft-versus-host disease *Eur J Ophthalmol* 1997;7:13-8.
17. Tichelli A, Duell T, Weiss M, Socié G, Ljungman P, Cohen A, *et al.* Late-onset keratoconjunctivitis sicca syndrome after bone marrow transplantation: Incidence and risk factors *Bone Marrow Transplant* 1996;17:1105-11.
18. Bray LC, Carey PJ, Proctor SJ, Evans RG, Hamilton PJ. Ocular complications of bone marrow transplantation. *Br J Ophthalmol* 1991;75:611-4.
19. Hettinga YM, Verdonek LF, Finjnheer R, Rijkers GT, Rothova A. Anterior uveitis: A manifestation of chronic graft versus host disease. *Ophthalmology* 2007;114:794-7.
20. Arain MA, Khan MD, Niazi MK, Ahmed P. Bilateral lacrimal bicanalicular obstruction in chronic graft versus host disease. *Pak J Pathol* 2009;20:23-4.
21. Spraul CW, Land GE, Kang GK. Corneal ulcer in chronic graft-versus-host disease: Treatment with collagen shields. *Klin Monatsbl Augenheilkd* 1994;205:161-6.
22. Mohammadpour M. Progressive corneal vascularization caused by graft-versus-host disease. *Cornea.* 2007;26:225-6.
23. Kerty E, Vigander K, Flage J, Brinch L. Ocular findings in allogeneic stem cell transplantation without total body irradiation. *Ophthalmology* 1999;106:1334-8.
24. Alvarez MT, Hernaez JM, Ciancas E, Figueroa MS. Multifocal choroiditis after allogeneic bone marrow transplantation. *Eur J Ophthalmol* 2002;12:135-7.

### Address for Correspondence:

**Dr. Muhammad Aamir Arain**, House A-223, Block-8, AEECHS, Gulistan e Johar, Karachi. **Tel:** +92-321-2161853

**Email:** doctorarain@yahoo.com