

ORIGINAL ARTICLE

EVALUATION OF APICAL ROOT RESORPTION IN ENDODONTICALLY TREATED AND VITAL TEETH IN ADULT ORTHODONTIC SUBJECTS

Abdul Rahman Khan, Mubassar Fida, Attiya Shaikh

Department of Surgery Aga Khan University Hospital, Karachi-Pakistan

Background: External apical root resorption (EARR) is one of the detrimental outcomes of an orthodontic treatment. The study was aimed to compare the mean EARR between endodontically treated and its contralateral vital tooth in adult orthodontic subjects. **Methods:** A total of 30 subjects were included in the study. EARR was evaluated on pretreatment and post-treatment orthopantomograms using Rogan Delft View Pro-X software. Equal number of endodontically treated and their contralateral vital teeth were evaluated. Linge and Linge method was used to evaluate the pretreatment and post-treatment root lengths. For comparison of EARR between genders, treatment type and vital versus endodontically treated teeth, Mann-Whitney U Test was applied. Spearman correlation was applied to determine the correlation of EARR with age of the patient, duration of treatment and pretreatment root length. A probability value of ≤ 0.05 was kept as statistically significant. **Results:** Vital teeth showed more root resorption as compared to endodontically treated teeth and in females as compared to males. A weak positive correlation was found between the root resorption and patient's age & pretreatment root length. In vital teeth, a weak negative correlation was appeared between root resorption and duration of the treatment. However, none of these correlations were significant. **Conclusions:** EARR appeared to be greater in vital as compared to the root filled teeth and in females as compared to the males. However, EARR was not significantly correlated with duration of treatment, age of patient and pretreatment root length.

Keywords: Orthodontic Treatment, Root Resorption, Root Apex, Endodontically Treated, Vital Teeth

Citation: Khan AR, Fida M, Shaikh A. Evaluation of Apical Root Resorption in Endodontically Treated and Vital Teeth in Adult Orthodontic Subjects. J Ayub Med Coll Abbottabad 2018;30(4):506-10

INTRODUCTION

External apical root resorption (EARR) is one of the deleterious effects related to an orthodontic treatment. It has been defined as the surface resorption resulting in shortening and blunting of root apex.¹ EARR occurs as a result of inflammatory process that is sterile and complex in nature having several components including tooth roots, forces, various types of inflammatory cells, bones and its surrounding matrix, and various types of known biologic messengers.²

Various factors such as patient's age, gender, genetics, orthodontic appliances, force magnitude, tooth extractions, duration of treatment and distance through which the tooth move may affect the amount of EARR.^{3,4} Root resorption occurs both the root apex as well as lateral root surfaces. The resorption that occurs at the apical region usually fails to repair and leads to permanent loss of root length. This can be observed by evaluating the root lengths on pretreatment and post treatment orthopantomographs.⁵

Usually mild EARR has minimal effects on the life expectancy, stability and tooth function. In

contrast, orthodontic therapy may have to be stopped in cases showing severe resorption involving more than one-third of root length.⁶ In a study by Marques *et al*,⁷ 14.5% of the study sample showed a severe root resorption.

Varied results have been reported regarding EARR in vital versus endodontically treated teeth during an orthodontic treatment. Llamas-Carreras *et al*⁸ found no significant difference in root resorption between endodontically treated and vital teeth. Lee and Lee⁵ and Bender *et al*,⁹ reported that vital teeth showed more root resorption as compared to the endodontically treated teeth. In contrast, Mah *et al*¹⁰ reported less resorption in vital teeth as opposed to endodontically treated teeth. They proposed that the periapical inflammation present prior to the commencement of treatment may result in increased resorption.

There is conflicting evidence that endodontically treated teeth when moved orthodontically may show greater resorption as compared to the vital teeth. Hence, this study aimed to evaluate the resorption present at the apical region of the root in endodontically treated and vital teeth during an orthodontic treatment in adult subjects.

MATERIAL AND METHODS

A retrospective study with sample comprising of 30 endodontically treated with 30 corresponding contralateral vital teeth action as controls was conducted. As data were collected from the records of patients who underwent orthodontic treatment at our dental clinics, an exemption (4395-Sur-ERC-16) was obtained from the institutional ethical review committee prior to conducting the study. The subjects were included based on the following inclusion criteria:

Good quality pretreatment and post-treatment standardized panoramic radiographs from same radiographic machine

- Endodontically treated tooth without any periapical radiolucency and root filled upto complete length prior to commencement of orthodontic treatment having contralateral vital tooth.
- Endodontically treated tooth followed for one year and having no periapical changes
- Orthodontic treatment exceeding more than 12 months
- No occlusal equilibration done
- Patients with no known para-functional habits such as bruxism, clenching

Subjects with endodontic treatment during orthodontic treatment, dental anomalies of number, size, form and position and missing contralateral non-vital tooth or endodontically treated with a history of trauma excluded.

OpenEpi software (version 3.0) was used for the calculation of sample size using the findings of Lee and Lee⁵ who reported the mean apical root resorption in endodontically treated teeth as 0.46 ± 1.41 mm and 0.53 ± 1.18 mm in vital teeth. The power of the study was set at 80% and a confidence interval of 95%. It was calculated that at least 15 subjects will be required in each study group. However, to increase the power of the study the maximum numbers of available subjects was included. We included 30 subjects consisting of 17 males and 13 females and 18 had non-extraction orthodontic treatment therapy while 12 had extraction treatment therapy. The subjects were treated with the Roth prescription having a slot size 0.022" with wires sizes progressively been increased, the initial wire of 0.012" NiTi till the finishing wire as 17×25 S.S were used by a team of resident under a single supervisor. The samples' mean age was 26.37 ± 2.4 years and mean treatment duration was 3.17 ± 1.09 years.

Data were obtained from the orthopantomograms of adult patients presenting to our dental clinics. The crown length and root

length measurements were analyzed on Rogan Delft View Pro-X software (Rogan-Delft, Veenendaal, The Netherlands) according to Linge and Linge prescribed method¹¹ (Figure 1).

Millimetric measurement of EARR was done. The difference in EARR for each endodontically treated tooth along with its contralateral tooth having vital pulp was calculated using the following method:

$$\text{EARR Difference} = \text{EARR in Endodontically treated tooth (ETT)} - \text{EARR in contralateral vital pulp tooth (VPT)}$$

Data were analyzed using SPSS version 20.0. Ten radiographs were randomly selected and measurements were repeated by the principal investigator and another author of the study to assess the intra and inter-examiner reliability. The Intra-class correlation coefficient showed a strong correlation between the measurements obtained by two authors. Kolmogorov-Smirnov test was used to test the normality of measurements which showed non-normal distribution. Hence non-parametric tests were used.

Mann-Whitney U Test was employed for comparison of root resorption between gender, treatment type, and vital versus root filled teeth. To evaluate the correlation of root resorption with age, treatment duration and root length, Spearman correlation was used. A probability value of ≤ 0.05 was considered to be statistically significant.

RESULTS

The vital teeth showed more root resorption as compared to the endodontically treated teeth. ($p = 0.045$) (Table-1). Females in comparison to the males showed more root resorption ($p = 0.024$) (Table-2).

When the difference in root resorption across gender in endodontically teeth versus vital teeth was checked the results showed a statistically significant difference in males only. In males, endodontically treated teeth showed less root resorption as compared to the vital teeth ($p = 0.005$) while in females the difference was not significant ($p = 0.979$) (Table-3).

Both the vital and the endodontically treated teeth showed more resorption in non-extraction cases as compared to the extraction cases but the results were not statistically significant. In extraction cases, the vital teeth showed more root resorption as compared to the endodontically treated teeth ($p = 0.004$). (Table-4).

The associated factors such as treatment duration, patient's age and pretreatment root length showed no statistically significant correlation with root resorption (Table-5).

Table-1: Root resorption in root filled teeth versus vital teeth

Tooth	Root length(mm) Mean±SD		Mean Difference (Root Resorption)	p - value
	Pretreatment	Post-Treatment		
Contralateral Vital	16.54±2.47	15.36±2.34	1.18±0.71	0.045*
Endodontically Treated	15.23±2.58	14.38±2.47	0.85±0.68	

n=60; Mann-Whitney U test. * $p \leq 0.05$

Table-2: Root Resorption in males versus females

	Males (Mean±SD) (n=17)	Females (Mean±SD) (n=13)	Mean Difference	p-value
Root Resorption (mm)	0.81±0.54	1.27±0.82	0.45	0.024*

n=60; Mann-Whitney U test. * $p \leq 0.05$

Table-3: Gender differences in root resorption of root filled versus vital teeth

	Root Resorption (mm) Mean±SD		p-value
	Endodontically Treated	Contralateral Vital Teeth	
Males (n=17)	0.40±0.27	1.08±0.55	0.005*
Females (n=13)	1.24±0.78	1.30±0.89	0.979

n=60; Mann-Whitney U test. * $p \leq 0.05$

Table-4: Root resorption in extraction versus non-extraction treatment types

	Root Resorption (mm) Mean±SD		p-value
	Endodontically Treated	Contralateral Vital Teeth	
Extraction (n=12)	0.62±0.52	1.08±0.74	0.004*
Non-Extraction (n=18)	1.00±0.75	1.24±0.70	0.633
p- value	0.141	0.554	

n=60; Mann-Whitney U test. $p \leq 0.05$

Table-5: Factors associated with root resorption

	Vital		Root Filled	
	r - Value	p - value	r - Value	p-value
Treatment Duration	-0.18	0.35	0.15	0.42
Age of the Patient	0.41	0.82	0.05	0.76
Pretreatment Root Length	0.29	0.19	0.33	0.07

n=60; Spearman Correlation. $p \leq 0.05$

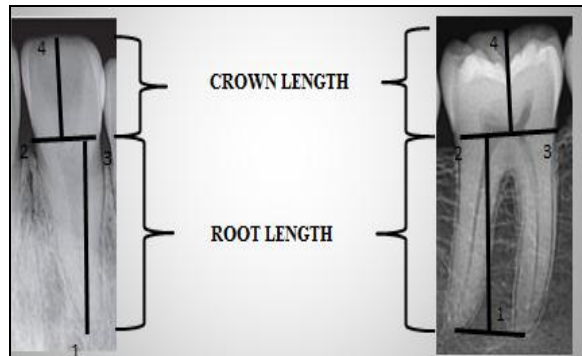


Figure-1: Reference lines and points are according to the study of Linge and Linge.¹¹ A line was marked from point 2 to 3 representing the CEJ, which is the anatomical junction between the crown and root of the tooth. For multi-rooted teeth another line was marked on orthopantomogram connecting the root apices. To measure the crown height a perpendicular is dropped from the top most of the crown point 4 to the CEJ. Similarly to measure the root length a perpendicular is dropped from the CEJ to the root apex or in the center of the line joining the root apices in case of multi rooted tooth demarcated as point 1

DISCUSSION

Among the deleterious effects associated with orthodontic treatment, EARR is one of the most undesirable complications. The resorption is difficult to predict. In the present study, vital teeth showed more root resorption as compared to the endodontically treated teeth ($p=0.045$). Our results are in agreement to the study reported by Lee and Lee⁵ ($p = 0.0001$) and Spurrier *et al.*¹² This is according to the hypothesis that decreased vascularity in endodontically treated teeth may result in decreased neuropeptides. The presence of these neuropeptides in vital teeth may be responsible for increased apical root resorption.¹⁰ Furthermore in endodontically treated teeth, the role of calcium hydroxide has also been proposed in decreasing the amount of root resorption as compared to the vital teeth. In contrast, other studies have reported no significant root resorption difference between filled and vital teeth.^{8,13,14}

In our study, females underwent more root resorption as compared to the males. This is in

concordance to study by Llamas-Carreras *et al.*⁸ In contrast, more resorption in males was reported by Baumrind *et al.*¹⁵ A similar study by Sameshima *et al.*¹⁶ and Lee and Lee⁵ failed to find a difference between gender and root resorption. Brazniak and Wasserstein¹⁸ in their study reviewed 13 relevant articles too assess association between apical resorption and gender. Amongst these, five reported no association, seven studies reported more resorption in females and only one study concluded that males showed greater resorption. This may be either because of difference in orthodontic forces that are applied or may be due to genetic dimorphism. The role of sex hormones in females has also shown to cause more root resorption.¹⁶

The treatment type may also influence the EARR as well. In our sample non-extraction treatment cases showed more root resorption as compared to the extraction treatment. This is in concordance to the study carried out by Baumrind *et al.*⁴ and Mcfadden *et al.*¹⁷ Lee and Lee⁵ reported that teeth underwent greater root resorption in extraction cases as compared to the non-extraction cases. They further suggested that resorption in vital and endodontically treated teeth showed no significant differences in extraction cases. In contrast, other studies have shown more root resorption in extraction cases.^{12,18-20} In our study, more resorption was present in non-extraction cases. This could either be due to excessive forces that are applied in non-extraction cases in order to finish the cases earlier. The treatment type, whether teeth were extracted or not, did not influence the root resorption in filled teeth as well as endodontically treated teeth to a statistically significant level. The vital teeth showed more resorption than root filled teeth in extraction cases, whereas in non-extraction cases no significant differences were present between the two groups.

In vital teeth, root resorption showed a weak negative trend with the treatment duration, whereas endodontically treated teeth showed a weak positive trend. Lee and Lee⁵ reported significantly increased resorption in endodontically treated teeth with increased treatment duration. The difference in results may be due to the fact that long treatment duration could be either due to missed appointments, breakages and non-compliance to the elastics by the patient. A weak to moderately strong positive trend was found between root resorption and age of the patient in endodontically treated teeth and vital teeth, respectively. These findings are in concordance with other studies conducted on larger sample.^{4,16,21} In contrast, Lee and Lee⁵ reported a weak positive correlation between age and root resorption of endodontically treated teeth ($p = 0.0318$). The root resorption was found to be statistically insignificant with pretreatment root length in both vital and

endodontically treated teeth. This means that neither long nor short roots effects the root resorption in both vital and endodontically treated teeth.

As endodontically treated teeth showed less root resorption, orthodontic treatment may be performed safely without risk of severe root resorption. Cautious biomechanics should be employed in males as well as non-extraction cases due of increase risk of resorption. As the current study is a single centered study with a low sample size, hence a CBCT based study with larger sample size and a multi-center study should be conducted to identify the root resorption in vital versus contralateral teeth and associated factors.

CONCLUSIONS

Root resorption in vital teeth was found to be greater as compared to endodontically treated teeth and in females as compared to males. In males, vital teeth showed more resorption as compared to the endodontically treated teeth. Root resorption was found to be greater in non-extraction cases as compared to the extraction cases. In extraction cases, endodontically treated teeth showed less resorption as compared to the vital teeth. Root resorption was not correlated with patient's age, treatment duration and pretreatment root length.

AUTHORS' CONTRIBUTION

ARK participated in study conception, data collection, statistical analysis and manuscript formatting. MF and AS participated in study conception and manuscript formatting. The final manuscript was read and approved by all the authors.

REFERENCES

1. Kocadereli I, Yesil TN, Veske PS, Uysal S. Apical root resorption: a prospective radiographic study of maxillary incisors. *Eur J Dent* 2011;5(3):318-23.
2. Al-Qawasmi RA, Hartsfield JK Jr, Everett ET, Flury L, Liu L, Foroud TM, *et al.* Genetic predisposition to external apical root resorption. *Am J Orthod Dentofacial Orthop* 2003;123(3):242-52.
3. Baumrind S, Korn EL, Boyd RL. Apical root resorption in orthodontically treated adults. *Am J Orthod Dentofacial Orthop* 1996;110(3):311-20.
4. Jiang RP, McDonald JP, Fu MK. Root resorption before and after orthodontic treatment: a clinical study of contributory factors. *Eur J Orthod* 2010;32(6):693-7.
5. Lee YJ, Lee TY. External root resorption during orthodontic treatment in root-filled teeth and contralateral teeth with vital pulp: A clinical study of contributing factors. *Am J Orthod Dentofacial Orthop* 2016;149(1):84-91.
6. Proffit WR, Fields HW, Sarver DM. Contemporary orthodontics. 5th ed. St. Louis: Mosby, 2013.
7. Marques LS, Ramos-Jorge ML, Rey AC, Armond MC, Ruellas AC. Severe root resorption in orthodontic patients treated with the edgewise method: prevalence and predictive factors. *Am J Orthod Dentofacial Orthop* 2010;137(3):384-8.
8. Llamas-Carreras JM, Amarilla A, Solano E, Velasco-Ortega E, Rodriguez-Varo L, Segura-Egea JJ. Study of external root

- resorption during orthodontic treatment in root filled teeth compared with their contralateral teeth with vital pulps. *Int Endod J* 2010;43(8):654–62.
9. Bender IB, Byers MR, Mori K. Periapical replacement resorption of permanent, vital, endodontically treated incisors after orthodontic movement: report of two cases. *J endod.* 1997;23(12):768-73.
 10. Mah R, Holland GR, Pehowich E. Periapical changes after orthodontic movement of root-filled ferret canines. *J Endod* 1996;22(6):298–303.
 11. Linge L, Linge BO. Patient characteristics and treatment variables associated with apical root resorption during orthodontic treatment. *Am J Orthod Dentofacial Orthop* 1991;99(1):35–43.
 12. Spurrier SW, Hall SH, Joondeph DR, Shapiro PA, Riedel RA. A comparison of apical root resorption during orthodontic treatment in endodontically treated and vital teeth. *Am J Orthod Dentofacial Orthop* 1990;97(2):130–4.
 13. Yang L, Tiwari SK, Peng L. Differences in root resorption between root canal treated and contralateral vital tooth during orthodontic tooth movement: a systematic review. *Orthod J Nepal* 2016;6(1):41–4.
 14. Esteves T, Ramos AL, Pereira CM, Hidalgo MM. Orthodontic root resorption of endodontically treated teeth. *J Endod* 2007;33(2):119–22.
 15. Sirisoontorn I, Hotokezaka H, Hashimoto M, Gonzales C, Luppapanornlarp S, Darendeliler MA, *et al.* Tooth movement and root resorption; the effect of ovariectomy on orthodontic force application in rats. *Angle Orthod* 2011;81(4):570–7.
 16. Sameshima GT, Sinclair PM. Predicting and preventing root resorption: part II. Treatment factors. *Am J Orthod Dentofacial Orthop* 2001;119(5):511–5.
 17. McFadden WM, Engstrom C, Engstrom H, Anholm JM. A study of the relationship between incisor intrusion and root shortening. *Am J Orthod Dentofacial Orthop* 1989;96(5):390–6.
 18. Liou EJW, Chang PMH. Apical root resorption in orthodontics patients with en-masse maxillary anterior retraction and intrusion with miniscrews. *Am J Orthod Dentofacial Orthop* 2010;137(2):207–12.
 19. Maués CP, Nascimento RR, Vilella OD. Severe root resorption resulting from orthodontic treatment: prevalence and risk factors. *Dent Press J Orthod* 2015;20(1):52–8.
 20. Motokawa M, Sasamoto T, Kaku M, Kawata T, Matsuda Y, Terao A, *et al.* Association between root resorption incident to orthodontic treatment and treatment factors. *Euro J Orthod* 2011;34(3):350–6.
 21. Ravanmehr H, Javadein S. Changes in root lengths of maxillary incisors during orthodontic retention period. *J Dent Med* 2005;18(4):13–21.

Received: 3 June, 2017

Revised: 22 September, 2017

Accepted: 16 January, 2018

Address for Correspondence:

Abdul Rahman Khan, House No. 61, Survery 444-5 Near Tina Square Model Colony Karachi-Pakistan

Email: abdulrahman.khan@aku.edu