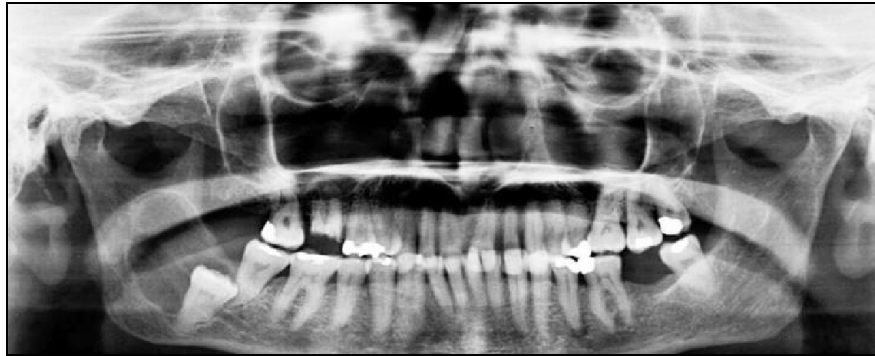


PICTORIAL

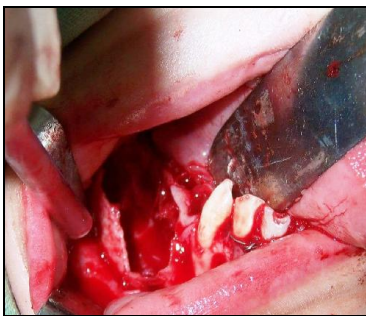
**HAEMANGIOMATOUS AMELOBLASTOMA OF MANDIBLE  
ASSOCIATED WITH IMPACTED THIRD MOLAR SIMULATING UNI-  
CYSTIC AMELOBLASTOMA**

**Manas Bajpai**

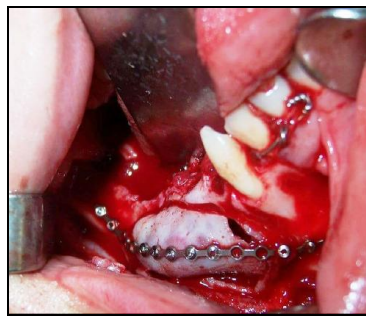Department of Oral and Maxillofacial Pathology, NIMS Dental College, Jaipur-India



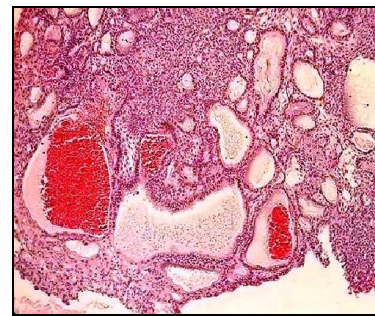**Figure-1: Multilocular radiolucent lesion involving right posterior mandible**



**Figure-2: Intra operative view showing enblock resection of the lesion.**



**Figure-3: Insertion of the reconstruction plate.**



**Figure-4: Anastomosing cords of ameloblastomatous epithelium with highly vascular stroma showing large spaces filled with blood. (Haematoxylin and eosin staining X20)**

**Citation:** Bajpai M. Haemangiomatous ameloblastoma of mandible associated with impacted third molar simulating uni-cystic ameloblastoma. J Ayub Med Coll Abbottabad 2018;30(4):623-4.

A 30-year-old male presented to the Department of Oral Medicine and Radiology, NIMS Dental College Jaipur (India) with the chief complaint of swelling on the right lower back region of the jaw from 1 year. Family history and past medical history was not relevant to the present symptom.

Extra oral examination revealed an asymmetry on the right side of the face. A swelling was extending from the corner of the mouth, inferiorly till the line extending from the tragus of the ear, posteriorly to the ramus of the mandible and anteriorly up to the corner of the mouth, measuring 3×3 cm approximately. Intra oral examination revealed a hard-bony swelling extending from #42 to the ramus of the mandible. The colour of the swelling was pink. There were no signs of ulceration and

discharge. Panoramic radiograph revealed a large multilocular osteolytic lesion of the right posterior mandible extending from #47 involving the angle of the mandible to the ramus. Tooth #48 was impacted. The peripheral margin of the lesion was sclerotic. (Figure-1) Fine needle aspiration (FNA) was done and it was found to be non-conclusive. No other radiographic examination was done and based on relatively larger radiolucency than dentigerous cysts. A provisional diagnosis of uni-cystic ameloblastoma (UA) was given, with the differential diagnosis of dentigerous cyst.

An incisional biopsy was performed and soft tissue section revealed the features of plexiform ameloblastoma microscopically.

Enblock resection was performed under general anaesthesia with the extraction of #46, #47 and impacted #48. (Figure-2) The defect was restored with reconstruction plates (Figure-3) and enblock resection tissue was sent to the Department of Oral and Maxillofacial Pathology for histopathological evaluation. The follow up period is going on and no recurrence and other complication have been noted so far. Histopathological examination of haematoxylin and eosin stained sections revealed a highly vascular tissue stroma comprised of numerous large sinusoidal spaces filled with blood with various anastomosing cords of ameloblastomatous epithelium lined by tall columnar cells and having stellate reticulum like cells inside. Few cords showed cystic degeneration also. (Figure-4) Based on histopathology a final diagnosis of HA was rendered. Ameloblastomas are benign tumours whose importance lies in its potential to grow into enormous size with resulting bone deformity.<sup>1</sup> Solid multi-cystic ameloblastoma (SMA) has common histopathological patterns including, Follicular, plexiform, Granular cell, Acanthomatous

and rare patterns include spindle cell, papuliferous, basal cell and haemangiomas.

Haemangiomas ameloblastoma (HA) is characterized histopathologically by an ameloblastoma having large spaces filled with blood or large endothelial lined capillaries.<sup>2</sup> An exhaustive literature review could reveal less than 15 published cases in English literature; moreover, none of them was associated with impacted third molar.

HA is a rare variant of SMA described as an ameloblastoma that has large blood-filled vascular spaces or dilated blood vessels lined by endothelial cells.<sup>2,3</sup>

## REFERENCES

1. Bajpai M, Agarwal D, Bhalla A, Kumar M, Garg R, Kumar M. Multilocular unicystic ameloblastoma of mandible. *Case Rep Dent* 2013;835892.
2. Kasangari MD, Gundamaraju K, Jyothsna M, Subash AV, Aravind K. Hemangiomas ameloblastoma- A case report of a very rare variant of ameloblastoma. *J Clin Diagn Res* 2015;9(5):ZD8-10.
3. Tamgadge AP, Sirur D, Bhalerao S, Pariera T, Tamgadge S. Hemangiomas Ameloblastoma: A case report of a rare variant of ameloblastoma. *Int J Contemp Dent* 2010;1(2):16-9.

*Received: 24 October, 2017*

*Revised: --*

*Accepted: 23<sup>rd</sup> February, 2018*

### Address for Correspondence:

**Dr. Manas Bajpai**, Department of Oral and Maxillofacial Pathology, NIMS Dental College, Shobha Nagar, Jaipur-Delhi Highway (NH-11C), Jaipur-303121, Rajasthan-India  
**Tel:** +91 9799415000  
**Email:** dr.manasbajpai@gmail.com