

PICTORIAL

A MOLAR TOOTH BRAINSTEM WITH A BAT-WING FOURTH VENTRICLE: JOUBERT SYNDROME

Muhammad Awais, Yousuf Husen, Abdul Rehman

Department of Radiology, Aga Khan University Hospital, Karachi-Pakistan

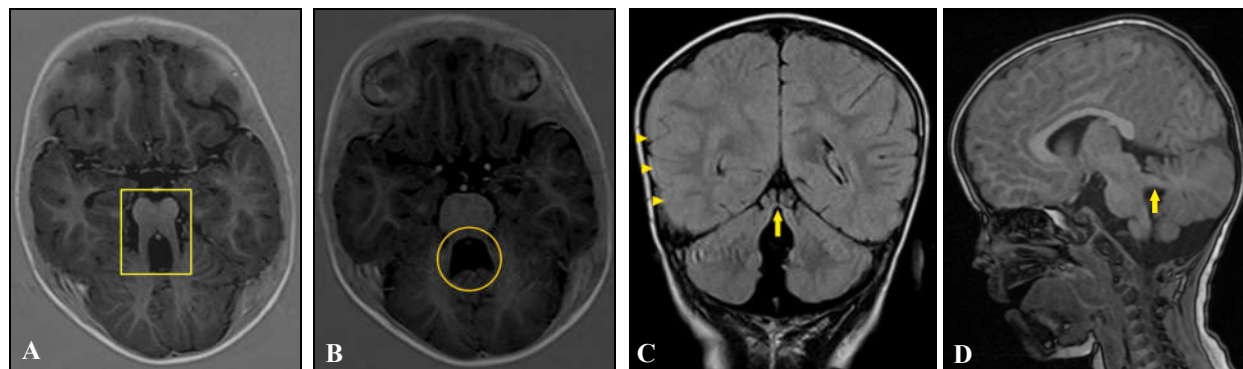


Figure-1: T1W (A, B, D) and FLAIR (C) images showing molar tooth configuration of the brainstem (square), bat-wing appearance of fourth ventricle (circle), thickened cortical gyri (arrowheads), absent inferior cerebellar vermis, and elongated, horizontally placed superior cerebral peduncles (arrows). Overall appearances are consistent with a diagnosis of Joubert syndrome.

A 28-month-old boy was brought by his parents for evaluation of poor growth. Parents reported that the child started neck-holding and sitting at 14 and 24 months of age respectively. He was also unable to walk. His speech was limited to 'mama' and 'dada' only. Examination showed generalized hypotonia and strabismus. Mother reported that one of the child's maternal cousins has had similar symptoms. Magnetic resonance imaging (MRI) of the brain was obtained, which showed a molar tooth configuration of the brainstem, bat-wing appearance of the fourth ventricle, absent inferior cerebellar vermis and horizontally placed cerebral peduncles. These radiographic appearances were consistent with a diagnosis of Joubert syndrome. This disease is a rare inherited ciliopathy characterized by typical malformations of the brainstem. Based on genetic analysis, Joubert syndrome is now recognized as a group of several related genetic disorders, which manifest phenotypically in a similar manner. The most common genetic defect implicated in this disorder is a mutation in the gene *ARL13B* encoding for adenosine diphosphate ribosylation factor like GTPase 13B. Patients usually present early in life with developmental delay and cerebellar ataxia. Most patients have associated abnormal eye movements (usually jerk nystagmus) and an abnormal pattern of breathing (episodic apnoea and tachypnea). Prognosis of such patients is dependent upon the presence of associated abnormalities. About 50% of children eventually learn to walk independently with an ataxic gait.

Keywords: Joubert syndrome; Ciliopathy

Citation: Awais M, Husen U, Rehman A. A molar tooth brainstem with a bat-wing fourth ventricle: Joubert syndrome. J Ayub Med Coll Abbottabad 2018;30(2):313-4.

CASE DESCRIPTION

A 28-month-old boy was brought by his parents for evaluation of poor growth. Parents reported that the child started neck-holding and sitting at 14 and 24 months of age respectively. He was also unable to walk. His speech was limited to 'mama' and 'dada' only. Examination showed generalized hypotonia and strabismus. Mother reported that

one of the child's maternal cousins has had similar symptoms. Magnetic resonance imaging (MRI) of the brain was obtained, which is shown in the accompanying figures. MRI brain showed a molar tooth configuration of the brainstem, *bat-wing* appearance of the fourth ventricle, absent inferior cerebellar vermis and horizontally placed cerebral peduncles. These radiographic appearances were consistent with a diagnosis of Joubert syndrome.

DISCUSSION

Joubert syndrome is an inherited ciliopathy characterized by typical malformations of brainstem that are readily detectable on radiologic imaging of the brain. This rare disorder is estimated to occur in 1 in 80,000 live-births.¹ However, in certain high-risk populations (e.g. Ashkenazi Jews), its prevalence may be as high as 1 in 34,000. Based on genetic analysis, Joubert syndrome is now recognized as a group of several related genetic disorders, which manifest phenotypically in a similar manner. The most common genetic defect implicated in this disorder is a mutation in the gene *ARL13B* encoding for adenosine diphosphate ribosylation factor like GTPase 13B.² This disorder usually follows an X-linked, or autosomal recessive, inheritance pattern. Patients usually present early in life with developmental delay and cerebellar ataxia. Most patients have associated abnormal eye movements (usually jerk nystagmus) and an abnormal pattern of breathing (episodic apnea and tachypnea).³ Typical radiologic signs include a bat-wing appearance of the fourth ventricle and the molar tooth sign, which results from a combination of cerebellar vermis hypodysplasia, an abnormally deep interpeduncular fossa, and thickened, elongated and horizontally placed cerebral peduncles.¹ Dandy-Walker malformation is an important differential diagnosis of this disorder and can be differentiated from Joubert

syndrome by the presence of cystic dilatation of fourth ventricle along with an upward-rotated, hypoplastic cerebellar vermis.³ Prognosis of such patients is dependent upon the presence of associated abnormalities. About 50% of children eventually learn to walk independently with an ataxic gait.²

Key Points

- Joubert syndrome is an inherited ciliopathy characterized by hypodysplasia of the cerebellar vermis and malformations of the brainstem.
- Affected patients have developmental delays, ataxic gait and abnormal eye movements.
- Typical radiographic signs on magnetic resonance imaging of the brain are a molar tooth brainstem and a bat-wing fourth ventricle.
- Prognosis of patients is variable and depends upon the presence of associated abnormalities.

REFERENCES

1. Romani M, Micalizzi A, Valente EM. Joubert syndrome: congenital cerebellar ataxia with the molar tooth. *Lancet Neurol* 2013;12(9):894–905.
2. Cantagrel V, Silhavy JL, Bielas SL, Swistun D, Marsh SE, Bertrand JY, *et al.* Mutations in the cilia gene *ARL13B* lead to the classical form of Joubert syndrome. *Am J Hum Genet* 2008;83(2):170–9.
3. Saleem SN, Zaki MS. Role of MR imaging in prenatal diagnosis of pregnancies at risk for Joubert syndrome and related cerebellar disorders. *AJNR Am J Neuroradiol* 2010;31(3):424–9.

Received: 23 November, 2017

Revised: --

Accepted: 15 February, 2018

Address for Correspondence:

Muhammad Awais, Resident, Department of Radiology, Aga Khan University Hospital, P.O. box 3500, Stadium Road, Karachi 74800-Pakistan.

Cell: +92 300 903 4827

Email: awais_aku@yahoo.com