

## ORIGINAL ARTICLE

## CAN ULTRASOUND ABDOMEN HELP IN EARLY DIAGNOSIS OF DIABETES MELLITUS? AN OBSERVATIONAL STUDY

Javed Anwar, Muhammad Omer Aamir, Sanaullah, Zeeshan ul Hasnain Imdad, Ishrat Parveen, Nasreen Yousaf

Combined Military Hospital, Multan-Pakistan

**Background:** Diabetes mellitus is a common disease. Similarly, ultrasound findings of fatty change and renal crystals are commonly seen on ultrasound. In the personal observation of the main author over the past so many years it was noticed that Diabetes Mellitus, Fatty liver and renal crystals all sit well together. This study tries to establish a relationship between diabetes mellitus renal echogenic foci and fatty liver. This study is first of its kind, as nobody has ever before investigated an association between the renal echogenic foci and fatty liver in relation to diabetes mellitus. **Methods:** This cross-sectional, observational study was conducted at Radiology Department Combined Military Hospital, Kohat From 2<sup>nd</sup> June 2013 to 30<sup>th</sup> May 2014. Three hundred patients were collected on the basis of having fatty liver and renal echogenic foci on ultrasound and three hundred more patients were collected who had no fatty liver or renal echogenic foci on ultrasound. Their labs were done for diabetes mellitus. **Results:** The patients having renal echogenic foci together with fatty liver had 83% positive rate of being diabetics, while patients with no fatty liver and no echogenic foci on ultrasonography had only 0.6% Positive rate of being diabetics. **Conclusion:** Our results provided the first demonstration of an association between renal echogenic foci together with fatty liver with the diabetes mellitus. Thus ultrasound examination of abdomen can be helpful in its early diagnosis if we make a protocol of doing fasting and random blood sugars in all those patients who have positive renal echogenic foci and fatty liver on their ultrasound examination.

**Keywords:** Diabetes Mellitus, Ultrasound Abdomen, Fatty Liver, Renal Echogenic Foci

J Ayub Med Coll Abbottabad 2015;27(4):807-10

## INTRODUCTION

The Ultrasound abdomen has become a very common and basic investigation in routine clinical practice. It is cost effective and readily available non-invasive real time imaging modality. Fatty liver is a very common finding, quite often, seen in cases of diabetes mellitus and also as an incidental finding on ultrasound abdomen. It is an established non-invasive diagnostic modality for fatty liver and its accuracy rate is 78%.<sup>1</sup>

Hepatic fatty change is a known complication of diabetes mellitus with a reported frequency of 42.1–75.2%.<sup>2</sup> The most common clinical manifestation of fatty liver is enlarged liver, and mostly these patients have normal or mildly deranged liver function tests. The fatty infiltration may advance to fibrosis or cirrhosis. “Type-1 diabetes is not associated with fatty infiltration if blood sugar is well controlled, but type-2 diabetes may have a 70% correlation regardless of blood glucose control”<sup>3</sup> or we can say the degree of sugar control in type-2 DM does not go well with the presence or absence of fatty liver.<sup>3</sup>

The diabetes mellitus has very well recognized renal complications like renal papillary necrosis, non-specific urinary tract infections, pyelonephritis, Xanthogranulomatous pyelonephritis and chronic pyelonephritis, which can variedly be identified on ultrasound abdomen.<sup>3</sup> It is very much possible that these renal echogenic foci, in a way, may represent the

sonographic manifestations of these conditions. Diabetes mellitus is the most common condition reported in approximately 30% of the cases of renal papillary necrosis, which can be manifesting itself because of sloughing of the tips of renal papillae and resultantly giving echogenic foci on ultrasound abdomen.<sup>4</sup> The rationale of this study is to find out any relationship between renal echogenic foci and fatty liver as demonstrated on ultrasound with the diabetes mellitus.

## MATERIAL AND METHODS

This study was carried out in the radiology department of Combined Military Hospital Kohat from 2<sup>nd</sup> June 2013 to 30<sup>th</sup> May 2014, after approval from Ethical review committee of the hospital. All patients irrespective of their age and gender, reporting for any reason for ultrasound abdomen and having fatty liver and renal echogenic foci (size range 1–5 mm) demonstrated on our ultrasound examination were included in this study. These renal echogenic foci were bright foci, which were not giving significant distal acoustic shadowing. They were usually located at tips of papillae, close to the calyces and sometimes in renal pelvises.

The patients having fatty liver showed bright liver with vascular obscuration of the hepatic parenchyma. The group of those patients who were

having no fatty liver and no renal echogenic foci on ultrasound was included in second phase.

A sample of 300 patients was selected fulfilling the inclusion criteria in first phase. Ultrasounds of the entire patients were done on Toshiba Nemio XG machine using 3.75 MHz curvilinear probe. All patients were subjected to same method of examination and were assessed in longitudinal, transverse and different plans in grey scale. The color Doppler was of no help in the evaluation of these foci & was not done as a protocol. No further imaging was done on these patients. Data of all the patients including demographic data, sonographic findings and the final blood sugar random and fasting reports was collected. In the second phase three hundred more patients were selected who were having no fatty change and no renal echogenic foci and were subjected to fasting and random blood sugar with their consent.

**RESULTS**

In the first group out of 300 patients 251 (83%) patients had diabetes as shown in figure 1. So the positivity rate was 83%. In second phase, Out of 300 patients only 2 patients turned out to be diabetics. So the positivity rate was only 0.6%.

Mean age of patients was 52.2 years (SD=13.9) with age range of (18–90) years with 159 (53%) males and 141 (47%) females, All 300 patients in the first group had (100%) fatty liver and all of these (100%) had renal echogenic foci. The sizes of the renal echogenic foci varied between 1–5 mm with average of 2.62mm (SD=1.002). Average fasting blood glucose was 145.18 mg/dl (SD=57.58) with range of 55–455 mg/dl. Average random blood glucose was 272.22 mg/dl (SD=78.9) with range of 140–558 mg/dl. Out of 300 patients, 249 (83%) patients had diabetes. So the positivity rate was 83%.

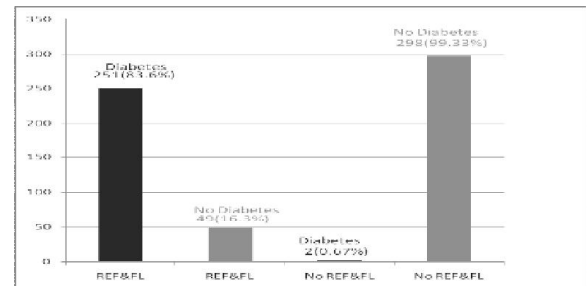
In second phase out of 300 patients only 2 patients turned out to be diabetics, shown in figure-1. So the positivity rate in this group was only 0.6 %. Average age of patients was 48 years (SD=15) with age range of (15–66) years with 180 (60%) males and 120 (40%) females.

Out of 600 patients, the minimum fasting blood sugar recorded is 40 and maximum fasting blood sugar recorded is 455.4 with mean 106.94 and standard deviation 56.91. The minimum random blood sugar recorded is 22 and maximum random blood sugar recorded as 558 with mean 192.25 and standard deviation 100.39. The minimum age is 16 while maximum age of the patients is 90 with mean 45.66 and standard deviation 15.55, as shown in table-1

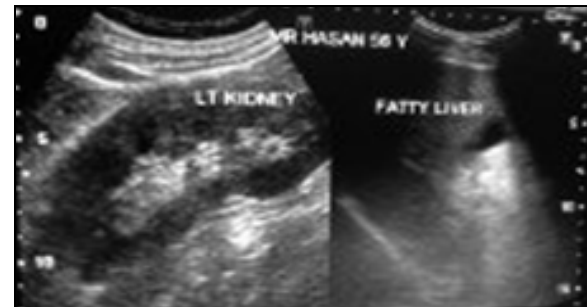
The results of correlation analysis are shown in table-2. The results show that the fasting blood sugar, random blood sugar, diabetes mellitus (DM) and fatty liver as well as renal echogenic foci (FL\*REF) are

significantly positively correlated with increase of age of patients. The fasting blood sugar is also significantly positively correlated with random blood sugar, diabetes mellitus and FL\*REF. Random blood sugar is significantly positively correlated with diabetes mellitus and FL\*REF. Similarly, diabetes mellitus is significantly positively correlated with fatty liver as well as renal echogenic foci (FL\*REF).

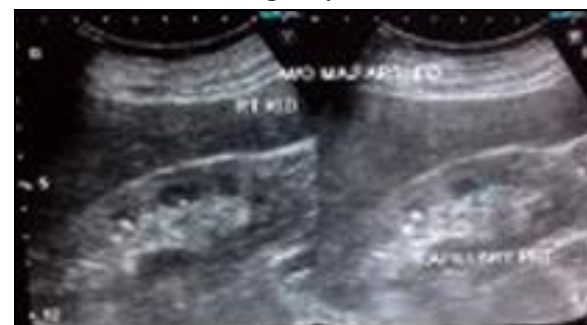The results of regression analysis are shown in table 3. The results are evident that the existence of diabetes mellitus is highly dependent on fatty liver as well as renal echogenic foci, fasting blood sugar and random blood sugar. The results are highly significant as the t-values are greater than the bench mark that is 2. The diagnostic statistics show that the results are free from model specification biasness and the results can be used for future forecast. The value of R-square represents that there is 78 percent variation in diabetes mellitus is due to fatty liver as well as renal echogenic foci, fasting blood sugar and random blood sugar.



**Figure-1: Comparison of renal echogenic foci & fatty liver with diabetes in both groups**



**Figure-2: Left kidney showing echogenic foci and liver showing fatty infiltration.**



**Figure-3: Both kidneys showing echogenic foci**

**Table-1: Descriptive Analysis**

	n	Min	Max	Mean	SD
Fasting blood sugar	600	40	455.4	106.94	56.91
Random blood sugar	600	22	558	192.25	100.39
Age	600	16	90	45.66	15.55

**Table-2: Correlation Analysis**

Correlations					
	Age	Fasting blood sugar	Random blood sugar	DM	FL*REF
Age	1	.361**	.418**	.433**	.426**
Fasting blood sugar (FBS)	.361**	1	.784**	.748**	.668**
Random blood sugar (RBS)	.418**	.784**	1	.834**	.797**
Diabetes mellitus (DM)	.433**	.748**	.834**	1	.819**
Fatty liver and renal echogenic foci (FL * REF)	.426**	.668**	.797**	.819**	1

\*\*Correlation is significant at 0.01 level (2 tailed)

FL\*REF :fatty liver and renal echogenic foci DM: Diabetes mellitus

**Table-3: Regression Analysis: Diabetes mellitus is the dependent variable**

Variables	Coefficients	Standard Error	t-values	Probability
Constant	-.298	.023	-12.773	.000
FL * REF	.395	.032	12.376	.000
Fasting blood Sugar	.002	.000	6.325	.000
Random blood sugar	.002	.000	9.293	.000

Diagnostic Statistic: R-Square=0.776, Adjusted R-Square=0.775, Reliability Statistic (Cronbach's Alpha)=0.956, Correlation Coefficient=0.881

**DISCUSSION**

This study is first of its kind, as nobody has ever before investigated an association between the renal echogenic foci and fatty liver in relation to diabetes mellitus. This study explains the potential role of Ultrasonography in diagnosing diabetes mellitus in patients having renal echogenic foci and fatty liver as demonstrated on ultrasound abdomen. It was observed in the study that 83% of the patients having renal echogenic foci together with fatty liver on ultrasound abdomen finally turned out to be having Diabetes Mellitus. Although we did not focus on age or gender this observation had no gender or age discrimination as it equally affected patients of all the ages and in both the genders. The 17% of the patients in the study didn't have the diabetes mellitus on the laboratory reports and we could not ascertain the underlying disease process in these patients because it was beyond the scope of this study. However this aspect can be looked into in the future studies. As far as this study is concerned we have found that the ultrasound can have a positive role in the diagnosis of diabetes mellitus if we make a protocol of doing

fasting and random blood sugars in all such cases of renal echogenic foci together with fatty liver on ultrasound abdomen. Further studies can be conducted to ascertain my observation.

It is a known fact that “the renal echogenic foci” is a common finding, known to the radiologists doing ultrasounds and there wouldn't be a radiologist who wouldn't be aware of this finding although he or she may be giving this different names like renal echogenic foci, concretion, crystals or just particles because these actually don't fit into the sonographic attributes of renal calculi.<sup>5</sup> However the relationship of these echogenic foci with fatty liver and diabetes mellitus has never been studied before, both locally or internationally. Diabetes mellitus is known for its renal complications and fatty liver, which can easily be observed on ultrasound abdomen.<sup>6</sup> Diabetes mellitus, is seen in approximately 50% of the cases of renal papillary necrosis<sup>4</sup> that can be one of the possible causes of renal echogenic foci on ultrasound. These renal echogenic foci of various sizes can also be due to mucosal sloughing and accumulation of proteinacious material adjacent to the tips of the renal papillae and calyceal cups which latter on undergo varied calcifications, as we know diabetes mellitus is known to cause calcifications at various locations. The long-term effects of diabetes on the genitourinary system include diabetic nephropathy, papillary necrosis, renal artery stenosis, diabetic cystopathy and vas deferens calcification.<sup>4, 6</sup> Randall plaques mentioned in the literature that can be a reason of these echogenic foci however, we did not find any reference in literature regarding the precise imaging finding of these Randall's plaques especially in relation to diabetes mellitus. It is believed that Randall's plaques are soft tissue calcific lesions located in the deep renal medullae about the surface epithelia of the papillae and act as a nidus for renal calculi formation. These plaques have been described to be composed of carbapatite (poorly crystallized carbonated calcium phosphate or carbonated apatite).<sup>7</sup>

It is mentioned in the literature that one-fifth of the patients undergoing imaging have renal calcifications, which may be labeled "renal stones"<sup>5,8</sup> but many of these calcifications are Randall plaques and not actual renal stones because they can neither be picked up on plain X ray KUBs nor on excretory urograms and which if done may cause extra radiation exposure to these patients. On CT scans also they may sometimes appear as mere punctate foci but are not identified in most of the cases and therefore CT better be avoided considering the radiation hazards. It is also mentioned in the studies that these Randall plaques can make their way into the renal collecting system and become renal calculi

later on.<sup>9,10</sup> I suspect that in the light of this study that these UIOs (unidentified Objects) are the ones often seen as renal echogenic foci on our ultrasound examinations.

The renal colics are quite common in diabetics and the cause could be either frequent infection, which is a known complication of diabetes mellitus or because of obstruction of the collecting system at miniature level. It has been mentioned in literature that Randall plaques could result in intraparenchymal obstruction of ducts of Bellini and cause colics often in patients of diabetes mellitus.<sup>5</sup> It is also mentioned in literature that although the Randall plaques may be the precursor foci for a renal stones but they are never equal to stones.<sup>11</sup> The line that could differentiate these two findings remain hazy and is an unexplored radiological arena which needs further research work especially in relation to fatty liver and diabetes mellitus.<sup>5</sup>

Fatty liver is a known complication of diabetes with a reported frequency of 42.1–75.2%.<sup>2</sup> However its relationship with renal echogenic foci with reference to diabetes mellitus on ultrasound abdomen has never been studied before.

## CONCLUSION

It is concluded that the patients having renal echogenic foci together with fatty liver as demonstrated on ultrasound examination have a positive rate of 83% for being diabetics and these renal echogenic foci together with the fatty liver do have a relationship with diabetes mellitus. The ultrasound abdomen can thus be helpful in predicting its diagnosis if we make a protocol of doing fasting and random blood sugars in all those patients who have renal echogenic foci and fatty liver and who might have not yet started the typical symptoms of diabetes. We suggest naming this as Javed Anwar's

sonographic criteria of early diagnosing Diabetes Mellitus and also its follow up.

## AUTHOR'S CONTRIBUTION

JA: The main author had the main contribution in conceiving his observation and collecting the data. MOA, S, ZuHI, IP, NY: helped in analyzing the data and statistics.

## REFERENCES

1. Cazzo E, de Felice Gallo F, Pareja JC, Chaim EA. Nonalcoholic fatty liver disease in morbidly obese subjects: correlation among histopathologic findings, biochemical features, and ultrasound evaluation. *Obes Surg* 2014;24(4):47–61.
2. Lv WS, Sun RX, Gao YY, Wen JP, Pan RF, Li L, *et al.* Nonalcoholic fatty liver disease and microvascular complications in type 2 diabetes. *World J Gastroenterol* 2013;19(20):3134–42.
3. Levinthal GN, Tavill AS. Liver disease and diabetes mellitus. *Clin Diabetes*. 1999;17(2):73–93.
4. Rodriguez-de-Velasquez A, Yoder IC, Velasquez PA, Papanicolaou N. Imaging the effects of diabetes on the genitourinary system. *Radiographics* 1995;15(5):1051–68.
5. Chi T, Miller J, Stoller ML. Randall plaque versus renal stone? *Transl Androl Urol* 2012;1:66–70.
6. Klouwens MJ, Blok WL, Witmer AN, Verouden CJ, Mura M. Serious complications of urinary tract infection in diabetes: emphysematous pyelonephritis and endogenous endophthalmitis. *Ned Tijdschr Geneesk* 2013;157(7):A5243.
7. Carpentier X, Bazin D, Jungers P, Reguer S, Thiaudière D, Daudon M. The pathogenesis of Randall's plaque: a papilla cartography of Ca compounds through an ex vivo investigation based on XANES spectroscopy. *J Synchrotron Radit* 2010;17(3):374–9.
8. Ciftçioğlu N, Vejdani K, Lee O, Mathew G, Aho KM, Kajander EO, *et al.* Association between Randall's plaque and calcifying nanoparticles. *Int J Nanomedicine* 2008;3(1):105–15.
9. Brenner DJ, Hall EJ. Computed tomography--an increasing source of radiation exposure. *N Engl J Med* 2007;357(22):2277–84.
10. Evan AP, Coe FL, Lingeman JE, Worcester E. Insights on the pathology of kidney stone formation. *Urol Res* 2005;33(5):383–9.
11. Williams JC Jr, Matlaga BR, Kim SC, Jackson ME, Sommer AJ, McAteer JA, *et al.* Calcium oxalate calculi found attached to the renal papilla: Preliminary evidence for early mechanisms in stone formation. *J Endourol* 2006;20(11):885–90.

## Address for Correspondence:

Dr Javed Anwar, Combined Military Hospital, Multan-Pakistan

Cell: +92 321 693 2996

Email: javenerz@hotmail.com