

## **UNUSUAL FOREIGN BODIES IN GIT**

*Gul Muhammad, Syed Jamil-ur-Rahman and Assad Bangush*

### **INTRODUCTION:**

A wide variety of foreign bodies have been found in the gastrointestinal tract and ingenious methods have been used for their removal. Recently several reports have shown the usefulness of fibropticendoscopes in removing foreign bodies from upper and lower parts of GIT. In this report we describe a child in whom nature and number of foreign bodies necessitated the use of rigid sigmoidoscopes for removal.

### **DISCUSSION:**

People who swallow foreign bodies can be divided into different categories. Adults may accidentally swallow pieces of meat, fish bone, dentures etc. Children form a completely separate group because of their natural curiosity which leads them to swallow anything they can put in their mouths. Psychotics fall in totally a different group and they habitually swallow articles deliberately like razors, blades, spoons, handles etc. Some patients think that any such thing swallowed will turn into gold, the majority of foreign bodies if not impacted in esophagus will pass through gastrointestinal tract without any complication.

The usual practice in managing foreign bodies is by watchful waiting with series of X-rays and if needed, endoscopic removal. Impacted foreign bodies or complications such as obstruction, perforation, bleeding etc. necessitates surgical removal. Here in our patient watchful waiting and use of rigid sigmoidoscopes was very successful.

### **CASE REPORT**

A young boy — Master Iqbal, aged 10 years was referred from casualty department with severe abdominal pain and acute urinary retention since 1 day. Nothing very suggestive was hinted by the mother regarding past illness except for history of geophagy and worm infestation. Apart from acute distress, abdominal distension and rigidity, the patient was found to exhibit extreme tenderness on P/R examination and in fact this procedure could not be carried out until the patient was relieved of pain. Symptomatic treatment was carried out to ease the distress and retention. Later, P/R examination showed inflamed anal margins and stony-hard masses and one such mass

---

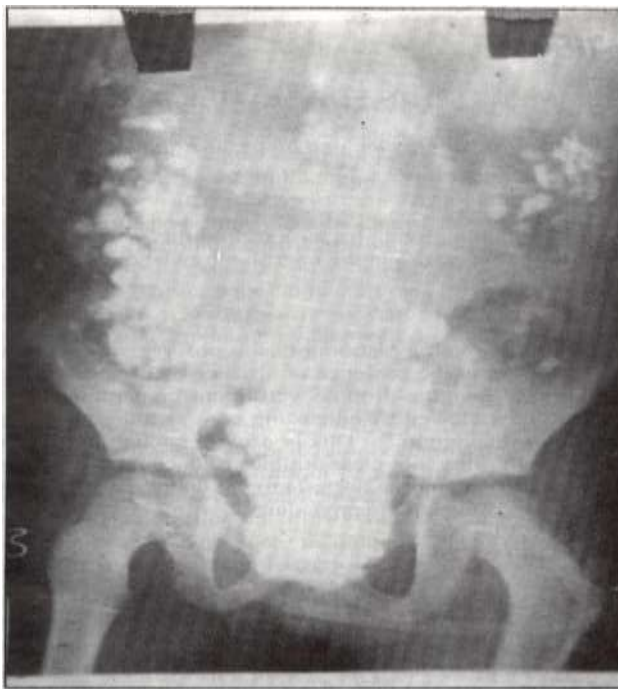
From Ayub Medical College, Abbottabad.

GUL MOHAMMAD, FRCS, Associate Professor, Department of Surgery.

SYED JAMIL-UR-RAHMAN, MS (USA), FRCS (Edin), Principal/Professor & Head of Department of Surgery.

ASSAD BUNGUSH, TMO, Surgical 'A' Unit.

on removal from rectum turned out to be a stone. X- rays of abdomen were carried out and they showed multiple stones spread throughout the gastrointestinal tract and the rectosigmoid region was packed with impacted stones.



As digital removal of stones was not much helpful in relieving the obstruction, so the patient was shifted to operating theater and under G.A. the impacted stones in rectums were removed by the use of rigid sigmoidoscopes with minimal injury to the rectal mucosa. Later by the end of the day, the patient started passing stones all by himself and by the lime he was discharged which was six days later, he had passed 113 stones per rectum and repeat X-rays of abdomen revealed a clear abdomen. With consultation from the hospital Psychiatrist he was discharged from the Unit and family counselling was done regarding the psychological care of the child as well.

#### **REFERENCES:**

1. Singh, K.J. Unusual foreign bodies in GIT. Internal surgery, 1978; 63:47-48.
2. Marsh, B.R. Swallowed foreign bodies. BMJ, 1975.
3. Ghani. A., Hashmi, M.S. Large foreign bodies of GIT. Internal surgery, 1981; 66: 271-72.
4. Short Note on endoscopic removal of duodenal foreign bodies. BMJ, 1974; 29: 502-3.
5. Short Report on removal of impacted rectal foreign bodies. BMJ, 1976; 19: 44-45.