

CASE REPORT

A TRICHOBEZOAR DIAGNOSED BY ULTRASOUND

Mohammad Idrees & Shah Jehan Afridi

*Trichobezoar is rare and its diagnosis by ultrasound even rarer. It results from eating hair, a type of pica, usually found in irrisolute women below thirty. Traditionally its diagnosis has been made on barium meal examination. The case under review clinically presented as a big epigastric mass for which ultrasound was advised. Trichobezoar produces a very characteristic and diagnostic appearance on ultrasound and must be considered in the diagnostic workup of such a condition.*

INTRODUCTION

A bezoar is a mass of foreign material in the stomach. Trichophagia leading to trichobezoar is rarely encountered almost exclusively in females. Over 80% of the patients are under 30 years of age and often are feeble-minded<sup>1</sup>. Trichobezoar shows well on barium meal examination. It has a characteristic appearance on ultrasound. Very few cases of trichobezoar diagnosis by ultrasound have been reported in our country, although the description of the entity in world literature is not sparse<sup>2</sup>.

We present here an interesting case which was diagnosed by ultrasound and confirmed by barium meal.

CASE

A woman aged 30 years from Balakot, district Mansehra, was admitted in surgical unit of District Headquarter Hospital, Abbottabad, presented with large mass in epigastrium and vomiting of six months' duration. She was referred for ultrasound examination of the mass. Previous ultrasound examination at Mansehra had reported a complex mass without any comment on its origin.

Ultrasound study with a 3.5 Mhz linear probe revealed a large 10 cm highly reflective area with posterior acoustic shadowing to the left of the spine, rather close to the anterior abdominal wall. Fig. 1

Examination following drinking of two glasses of water confirmed the location. Change of position of the patient showed very little movements of the mass.

A confident diagnosis of trichobezoar was given as

As rest of the organs were found normal morphologically. Barium meal showed typical filling defect consistent with trichobezoar. (Fig. 2)

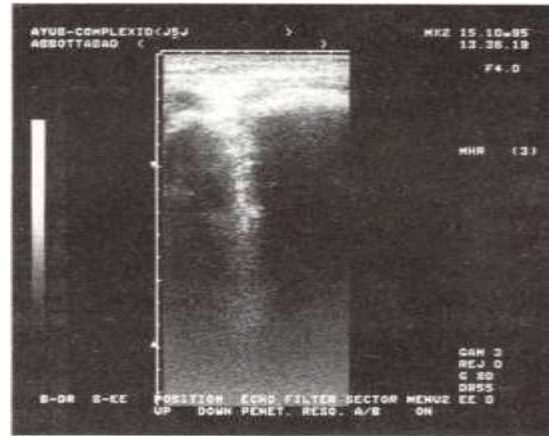

Fig. 1. Sonogram showing trichobezoar as echogenic area to the left of spine showing acoustic shadowing.

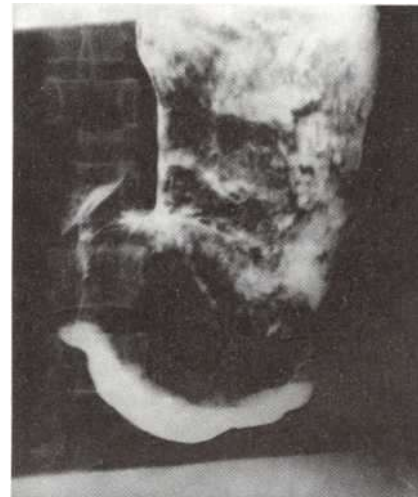


Fig. 2. Barium meal film displaying a large filling defect which showed a slight movement on change of position of the patient.

From: Ayub Medical College, Abbottabad.  
**DR. MOHAMMAD IDREES**, MBBS, DMRD, FCPS, Assistant Professor, Department of Radiology  
**DR. SHAH JEHAN AFRIDI**, MBBS, DMRS, Professor and Head of Radiology Department

**DISCUSSION**  
Trichobezoar results from trichophagia, almost exclusively found in females below thirty years of age. Majority of these patients have psychiatric problems.

Diagnosis of hair ball of the stomach has been fairly easy on barium meal that reveals a large, irregular, persistent filling defect. The condition rarely presents as abdominal mass<sup>3</sup>.

Ultrasound has penetrated the gut and is being used to diagnose the inflammatory and mass lesions<sup>4</sup>. Trichobezoar displays a very characteristic appearance on ultrasound as a strongly echogenic area with acoustic shadowing. It may reveal slight movement on change in position. Ingestion of copious amounts of water is of much assistance in establishing the location in the stomach.

Trichobezoar is a serious surgical condition which may result in gastritis, haematemesis, perforation and peritonitis. It is also a rare cause of intestinal obstruction and inanition<sup>5</sup>.

This case is of special interest because she was operated for perforation/peritonitis in February 1989 and hair ball was removed from the stomach<sup>6</sup>. She again landed with epigastric mass in 1995 with a trichobezoar second time. Recurrent development of trichobezoar has also been reported by other authors<sup>7, 8</sup>.

Thus basic cause needs to be rectified by psychotherapy and behavior therapy. Although surgery is mainstay in the treatment of trichobezoar, nonsurgical methods like lithotripsy have also been tried<sup>9</sup>.

## REFERENCES

1. Sidhu BS. Trichobezoars. *J Indian Med Assoc*, 1993 April;91(4): 100-1.
2. Malpani A. Role of sonography in trichobezoars. *J Ultrasound Med*, 1989 Dec;7(12):661-63.
3. Qureshi NH. Trichobezoar - a condition to think of in cases of mobile abdominal mass. *Irish Medical J*, 1992;85(2):4.
4. Fleischer AC, et al. Real time sonography in bowel. *Clinics in Diagnostic Ultrasound*, 1982; 117:135.
5. Mann CV, Russel RCG & Williams NS (Eds). *Trichobezoar. In Bailey and Love's Short Practice of Surgery*. ELBS with Chapman & Hall, London, 1995, p 698.
6. Aurangzeb G & Humayun A. Trichobezoar. *JAMC* 1991 ;4(1):54-55.
7. Korak Kov IUA. Repeated development of trichobezoar in the stomach. *Klin Khir* 1991 (80):73 - (English translation from Russian).
8. Jain K. Recurrent trichobezoar due to psychosocial stresses. *J Indian Med Assoc* 1987 Dec; 85(12):363-64.
9. Bennes J. Treatment of gastric bezoars by extracorporeal shock wave lithotripsy. *Endoscopy* 1991 Nov;23(6): 146-48.