

## ORIGINAL ARTICLE

# ARE THEIR YOUNG CORONARIES OLD ENOUGH? ANGIOGRAPHIC FINDINGS IN YOUNG PATIENTS WITH ACUTE MYOCARDIAL INFARCTION

Muhammad Anjum, Muhammad Zaman, Fareed Ullah

Punjab Institute of Cardiology, Lahore-Pakistan

**Background:** Increasing affection of younger patients with ischemic heart disease is an enhanced concern in developing Asian nations. This study elaborates the morphology and distribution of coronary lesions in young Asians presenting with acute coronary syndrome (ACS). **Methods:** Patients (aged  $\leq 35$  years) with (ACS) undergoing angiography were studied. Their angiographic disease was analysed to determine the common sites, severity and types (AHA and SCAI) of lesions. The association of LV dysfunction with lesion parameters was identified. Patients with cocaine or other drug abuse and valvular heart disease were excluded. **Results:** Two hundred and twenty-one patients aged 16–35 ( $31.4 \pm 3.5$ ) years were studied with predominant males (195, i.e., 88.2%). On angiography 51 (23.1%) patients showed normal coronaries while 108 (48.9%) had single, 48 (21.7%) had double and 14 (6.3%) had multivessel disease. On the whole, involvement of left anterior descending artery (LAD) either singly or in combination with other vessels was seen in 146 (66%), right coronary artery (RCA) in 56 (25.3%), left circumflex (LCX) in 43 (19.5%) and left main stem in 06 (2.7%) of total patients. Regarding lesion characteristics, tight lesions (45.4%), AHA type-A (47.8%) and SCAI-I (70.1%) lesions were common. The mid segment was commonly involved in LAD and LCX while proximal segment in RCA. Severe LV dysfunction was associated with presence of LAD disease. **Conclusions:** Coronary angiograms can be normal in up to one fourth of young ACS patients. Others show a predominance of LAD artery involvement with morphologically simple lesions.

**Keywords:** Coronary angiography; Coronary lesions; Young patients

**Citation:** Anjum M, Zaman M, Fareedullah. Are their young coronaries old enough? Angiographic findings in young patients with acute myocardial infarction. J Ayub Med Coll Abbottabad 2019;31(2):151–5.

## INTRODUCTION

The emerging epidemic of coronary artery disease in younger age group is a new alarm in native Asians.<sup>1,2</sup> The mortality from ischemic heart disease (IHD) has been showing a steady decline in the high income western countries.<sup>2</sup> Contrary to this, the mortality from IHD in low income regions including central Asian countries is on a persistent rise.<sup>2</sup> As an example the age standardized mortality per 100,000 population from IHD between 2000 and 2009 fell from 18.9 to 8.9 in Netherlands, 29.3 to 16.7 in UK, while it rose from 71.8/100,00 to 91.5 in Kyrgyzstan which is a low to middle income central Asian country.<sup>2</sup> The mean age at presentation in these regions is showing a downward trend leading to high mortality in young working age group.<sup>2</sup> This obviously has adverse social, economic and health consequences.<sup>3</sup> Risk profile is different in patients younger than 35 years as compared to older patients<sup>1</sup>, so can be the angiographic pattern of disease. Risk profile and angiographic disease can also be different in younger Asian patients as compared to the western youth, where cocaine and drug abuse is prevalent.<sup>4-8</sup> Up to 6% of young patients show acute myocardial infarction (MI) who present to emergency room with chest pain after cocaine abuse in western studies.<sup>4</sup> A significant number of western young patients do not exhibit atherosclerotic lesions on angiography.<sup>9</sup> But in young Asians traditional risk factors

like unhealthy eating habits, smoking, tobacco use and sedentary lifestyle are still the major risk factors for premature CAD.<sup>1</sup> So the angiographic pattern of CAD in western youth cannot be generalized to young Asian patients. Whether their angiographic lesion distribution and disease severity differ from patients of same age group in the west, needs to be sought out. Angiography remains the gold standard in defining anatomy of coronary arteries. Our study aims at a detailed angiographic description of the distribution, severity and types of coronary artery lesions, as well as their relation with LV dysfunction on coronary angiography (CA) in a younger Asian patients' population presenting with ACS. Published data on detailed angiographic characterization of coronary lesions in young patients is scarce in our region<sup>1</sup>, necessitating the need for more research on this important subject. In the studies already done, focus has been on ratio of normal coronaries and single versus multivessel disease in the young, and description of lesion characteristics is not elaborated which is crucial factor in decision making. This study tries to fill the gap and aims at detailed characterization of lesion morphology, including application of AHA and SCAI classifications.

## MATERIAL AND METHODS

This study was done at a tertiary care, high volume interventional cardiology centre with more than 16000

diagnostic and interventional procedures annually. Young patients aged 35 years or less were included into this study after taking informed consent.

Patients of both genders aged 15–35 years who were admitted with acute coronary syndrome (ACS) and underwent coronary angiography were included into this study. Patients with a history of drug abuse (cocaine, marijuana or any other potent vasoactive drug) and Prinzmetal angina were excluded because these patients have transient vasospasm as the mechanism of ACS rather than true coronary artery atherosclerotic disease. Patients with history of valvular heart disease, hypertrophic cardiomyopathy, connective tissue disease or renal disease were also excluded from the study.

A minimum sample size of 179 patients was calculated with 95% confidence level, a 5% margin of error and an expected significant coronary artery disease to be present in 65% of the young patients undergoing angiography.<sup>10</sup>

$$n = \frac{z^2 \cdot p \cdot (1-p)}{d^2}$$

where

$$Z^2_{1-\alpha/2} = 1.96, \text{ (for 95\% confidence level)}$$

**P**=0.65 (expected proportion of 65% patients having significant coronary disease based on previous study.<sup>10</sup> It is shown in decimal)

**D**=0.05 (expected 5% margin of error, shown in decimal)

A purposive Consecutive sampling technique was used. All the consecutive patients ≤35 years of age, undergoing coronary angiography after an episode of ACS were included into the study over a period of approximately 06 months.

## MATERIAL AND METHODS

All patients underwent coronary angiography using Judkins catheters and non-ionic contrast. The angiographic findings were interpreted by two operators and the findings entered on a proforma. Visual estimation of lesion severity and morphology as well as quantitative coronary angiography was used. All the lesions involving LMS, LAD, LCX and RCA were noted. Site of the lesion, severity of stenosis, AHA as well as SCAI class of each lesion was noted. Ostial lesion was defined as starting with in 2mm of the origin of any artery. Mild, moderate and severe stenosis was defined as <40%, b/w 40–69 % and ≥70% angiographic luminal narrowing as compared to the reference vessel diameter. For LMS artery >50% stenosis was regarded as severe and 30–50% as moderate. Total occlusion was defined when there was TIMI 0 flow beyond a point into the distal vessel. AHA type A, B or C and SCAI class I to IV were defined according to standard criteria. Mild, moderate and severe

LV dysfunction was defined as ejection fraction between 46–54%, 31–45% and ≤30% respectively. The association of LV dysfunction with site and characteristics of lesions was described. All the data was analysed using SPSS software version 16.

## RESULTS

A total of 221 patients admitted with ACS underwent corner angiography. Their baseline characteristics and risk profile are shown in table-1. Minimum age was 16years and maximum age 35 years. Males were predominant, 195(88.2%) men and 26(11.8%) women. The mean age was 31.4 (±3.5) years. Women had a relatively higher age in this subset of patients (mean age 33.3±2 for women vs 31.2±3.6 years for men).

During analysis of the angiograms we focused on and thus described how many patients had single, double and triple vessel disease, and the proportion of involvement of various arteries along with their segments (Table-2). The severity and commonest morphology of lesions was also analysed (Table-2, 3). It was seen that coronary artery disease was present in 170 (76.9%) patients, while almost one fourth of the cases showed normal coronary angiogram. Regarding disease pattern single vessel disease was most common, seen in 108 (48.9%) patients. Double and triple vessel disease was present in 48 (21.7%) and 14(6.3%) patients respectively. LAD was found to be the most commonly diseased vessel in young patients. A subgroup analysis of 108 single vessel disease patients showed that LAD was culprit vessel in 88 (81.5%), RCA in 15 (13.9%), LCX in 4 (3.7%) and LMS in 1 (0.93%) patient. Among 48 patients with two vessel disease, 25(52.1%) had a combination of LAD and RCA 25 (52.1%), 16 (33.4%) had LAD and LCX, while 6 (12.5%) had LCX and RCA involved in combination. One patient (2.1%) showed a combination of LMS and LAD. On the whole among the 221 patients, the LAD was involved in 146 (66%) either singly or in combination with other vessels, RCA in 56 (25.3%), LCX in 43(19.5%), while LMS in 06 (2.7%) patients (Figure-1). Now regarding lesion characteristics, the commonest site for occurrence of a lesion was mid segment in LAD and LCX, and proximal segment in RCA. Tight lesions were more frequent in each vessel. When these lesions were segregated according to AHA and SCAI classification systems we found that type A and type I lesions were most frequent. It implies that morphologically most of the lesions were simple one, favouring percutaneous intervention (Table-2).

LMS disease was relatively uncommon 2.7% (6 patients). Three of these patients had tight disease, all in the distal LMS. Isolated LMS lesion was seen in one patient only.

The degree of LV dysfunction is shown in Figure-2. Severe LV dysfunction was seen more frequently in patients with a lesion in LAD.

**Table-1: Baseline characteristics and risk profile of patients. (Total number of patients 221)**

Mean age	31.4(±3.5) years
Mean age among men	31.2±3.6 years
Mean age among women	33.3±2 years
No of men	195 (88.2%)
DM	48 (21.7%)
HTN	56 (25.3%)
Smoking	143 (64.7%)
Family history of ischemic heart disease at age <40	32 (14.5%)
Junk Food	150 (67.9%)
Physical Inactivity	190 (86%)

**Table-2: Frequency of site of lesions and severity of stenosis. Total number of lesions = 251**

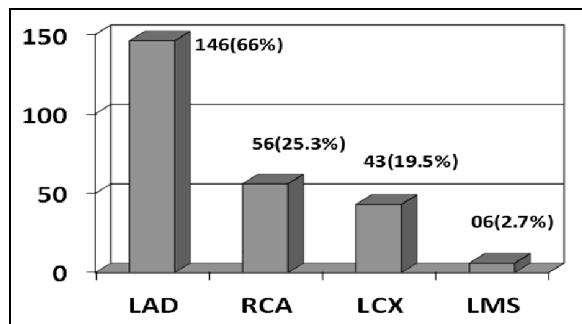
	LAD 146 (58.2%)	LCX 43 (17.1%)	RCA 56 (22.3%)	LMS 06 (2.4%)	TOTAL no of lesions = 251
<b>Site of lesion</b>					
OSTIAL	8 (5.5%)	5 (11.6%)	1 (1.8%)	1 (16.7%)	15(6%)
PROXIMAL	62 (42.5%)	10 (23.3%)	23 (41.1%)	1 (16.7%)	96(38.2%)
MID	75 (51.4%)	23 (53.3%)	22 (39.3%)	0	120(47.8%)
Distal	1 (0.7 %)	5 (11.6%)	10 (17.9%)	4 (66.7%)	20(8%)
<b>Severity of lesion</b>					
mild	33 (22.6%)	3 (7 %0)	8 (14.3%)	03 (50%)	47 (18.7%)
moderate	18 (12.3%)	9 (20.9%)	9 (16.1%)	0	36 (14.3%)
tight	65 (44.5%)	22 (51.2%)	24 (42.9%)	03 (50%)	114 (45.4%)
total occlusion	30 (20.5%)	9 (20.9%)	15 (26.8%)	00	54 (21.5%)

LAD; Left anterior descending artery, LCX; left circumflex artery, LMS; Left main stem artery, RCA; right coronary artery. Mild stenosis < 50% luminal diameter stenosis, moderate 50-69%, tight≥70%, total occlusion= TIMI-0 flow.

**Table-3: Lesions Morphology; AHA and SCAI categories of lesions**

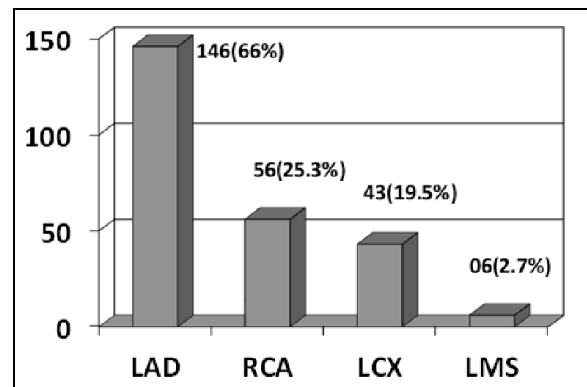
	LAD 146 (58.2%)	LCX 43 (17.1%)	RCA 56 (22.3%)	LMS 06 (2.4%)	TOTAL no of lesions = 251
<b>AHA class of lesion</b>					
A	75 (51.4%)	18 (41.9%)	24 (42.9%)	03 (50%)	120 (47.8%)
B	51 (34.9%)	21 (48.8%)	19 (33.9%)	03 (50%)	94 (37.5%)
C	20 (13.7%)	4 (9.3%)	13 (23.2%)	00	37 (14.7%)
<b>SCAI type of lesion</b>					
I	107 (73.3%)	29 (67.4%)	34 (60.7%)	06 (100%)	176 (70.1%)
II	8 (5.5%)	5 (11.6%)	5 (8.9%)	00	18 (7.2%)
III	11 (7.5%)	5 (11.6%)	4 (7.1%)	00	20 (8%)
IV	20 (13.7%)	4 (9.3%)	13 (23.2%)	00	37 (14.7%)

LAD; Left anterior descending artery, LCX; left circumflex artery, LMS; Left main stem artery, RCA; right coronary artery, AHA; American heart association, SCAI; Society of coronary angiography and intervention (USA)



**Figure-1: Number of patients showing coronary artery disease in individual vessels among the total 221 Patients**

LAD; left anterior descending artery, LCX; left circumflex artery, LMS; left main stem artery, RCA; right coronary artery



**Figure-2: Degree of left ventricular dysfunction in patients with coronary artery**

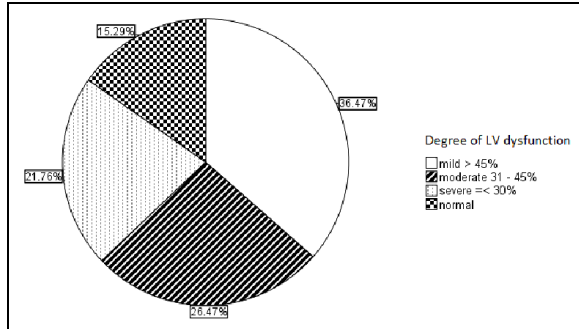


Figure-3: Severity of LV dysfunction

## DISCUSSION

Ischemic heart disease was relatively uncommon in developing countries a couple of decades ago, but owing to the rapid changes in lifestyle specially eating habits and sedentary life, there has been a rapid outburst of the disease. The appearance of this epidemic in their younger subgroup has followed even a more aggressive pattern with shifting of mean age of presentation from sixth to fifth and fourth decades of life in the recent years.<sup>1</sup> The younger patients usually present with ACS, and stable CAD as a primary presentation is rarely seen. Now angiography is the primary tool to assess the nature and severity of CAD in these patients. Our study is one of the earliest in Southeast Asia to show in detail angiographic assessment of CAD in ACS subjects younger than 35 years of age. This included arterial distribution of the disease, predominant sites of lesions, and predominant lesion characteristics according to standard AHA and SCAI classification systems. A study by Christus *et al* done in Gulf region showed significant CAD to be present in a high proportion of their young patients undergoing angiography, a result similar to our study. There are certain similarities in findings when we compared our study to published data on young IHD patients. Like there has been a very high young male predominance reaching upto more than 85%.<sup>12</sup> Single vessel disease is more prevalent as shown by Zhang in china<sup>13</sup>, Colkesen<sup>14</sup> in turkey and sricharan<sup>12</sup> in India (73.3%, 69% and 57.1% respectively). Zimmerman<sup>15</sup> and Choudhury *et al* have also shown similar results in their studies in USA. The LAD artery is culprit vessel most of the times (found in 60%, 63.3% and 61% percent of patients by colkesen<sup>14</sup>, sricharan<sup>12</sup> and zimmerman<sup>15</sup> *et al* respectively). Following LAD the Prevalence of disease to be present in RCA and then LCX has been similarly shown by Zimmerman *et al*.<sup>15</sup> The frequency of LM involvement remains very low in young patients.<sup>1</sup> The mean degree of LV dysfunction was shown to be <45% by zimmerman<sup>15</sup> *et al* while slightly lesser degree of LV dysfunction was seen in our population. These similarities in

results among various studies might suggest similar pathological processes and hemodynamic responses leading to development of CAD in young patients. It might suggest that in younger age, eating habits and other modifiable risk factors rather than ethnicity can determine CAD presentation and distribution. The mean age in our study population was lowest than all of above studies, making it truly representing the CAD in youngest population ever studied. Moreover, our study has classified lesions according to AHA and SCAI classifications, a detail presented for first time by any study on young patients. AHA and SCAI lesions categorization directly affects decision making for PCI.

Our study had some limitations, like IVUS or OCT was not used. This was also not used in previous studies. But it can be a subject for future research, especially in myocardial infarction with normal coronaries (MINOCA).

**Acknowledgements:** We pay special thanks to Professor Nadeem Hayyat Mallick, director of our cath lab for his encouragement and guidance. We will like to thank all the staff in our catheterization lab for their cooperation, especially Mr. Sheraz, Amjad, Usman and Tariq.

## AUTHORS' CONTRIBUTION

MA: Study design, data collection, analysis of results, manuscript writing. MZ: data collection, data entry to SPSS, data analysis. FU: data collection, data analysis, discussion review

## RERERENCES

1. Saghir T, Qamar N, Sial J. Coronary Angiographic Characteristics of Coronary Artery Disease in Young Adults Under age Forty Years Compare to Those over Age Forty. Pak Heart J 2008;41(3-4):49.
2. Finegold JA, Asaria P, Francis DP. Mortality from ischaemic heart disease by country, region, and age: statistics from World Health Organization and United Nations. Int J Cardiol 2013;168(2):934-45.
3. Sharma M, Ganguly NK. Premature Coronary Artery Disease in Indians and its Associated Risk Factors. Vasc Health Risk Manag 2005;1(3):217-25.
4. McCord J, Jneid H, Hollander JE, de Lemos JA, Cercek B, Hsue P, *et al*. Management of Cocaine-Associated Chest Pain and Myocardial Infarction. A Scientific Statement from the American Heart Association Acute Cardiac Care Committee of the Council on Clinical Cardiology. Circulation 2008;117(14):1897-907.
5. Kayo N, Shitole S, Beheshtian A, Srinivas V, Scheuer J, Kize J. Profile, acute care and outcome of cocaine-associated st-elevation myocardial infarction in a vulnerable urban community. Acute coronary syndromes. J Am Coll Cardiol 2014;63(12 Suppl):A125.
6. Kasim S, O'Donabhain R, Mcfadden E. Cocaine-associated myocardial infarction: should they all be stented? Case Rep Cardiol 2011;2011:347806.
7. Mir A, Obafemi A, Young A, Kane C. Myocardial Infarction Associated With Use of the Synthetic Cannabinoid K2. Pediatrics 2011;128(6):e1622-7.

8. Thomas G, Kloner RA, Rezkalla S. Adverse Cardiovascular, Cerebrovascular, and Peripheral Vascular Effects of Marijuana Inhalation: What Cardiologists Need to Know. *Am J Cardiol* 2014;113(1):187–90.
9. Choudhry L, Marsh JD. Myocardial infarction in young patients. *Am J Med* 1999;107(3):254–61.
10. Christus T, Shukkur AM, Rashdan I, Koshy T, Alanbaei M, Zubaid M, *et al.* Coronary Artery Disease in Patients Aged 35 or less – A Different Beast? *Heart Views* 2011;12(1):7–11.
11. Wong CP, Loh SY, Loh KK, Ong PJ, Foo D, Ho HH. Acute myocardial infarction: Clinical features and outcomes in young adults in Singapore. *World J Cardiol* 2012;4(6):206–10.
12. Sricharan KN, Rajesh S, Rashmi. Study of acute myocardial infarction in young adults: risk factors, presentation and angiographic findings. *J Clin Diagn Res* 2012;6(2):257–60.
13. Zhang WP, Yuan ZY, Liu Y, Jiaa L, Cheng H, Qi J, *et al.* Risk factors and coronary angiographic findings in young and elderly patients with acute myocardial infarction: a comparative analysis. *Nan Fang Yi Ke Da Xue Xue Bao* 2008;28(5):718–21.
14. Colkesen AY, Acil T, Demircan S, Sezgin AT, Muderrisoglu H. Coronary lesion type, location, and characteristics of acute ST elevation myocardial infarction in young adults under 35 years of age. *Coron Artery Dis* 2008;19(5):345–7.
15. Zimmerman FH, Cameron A, Fisher LD, Ng G. Myocardial Infarction in Young Adults: Angiographic Characterization, Risk Factors and Prognosis (Coronary Artery Surgery Study Registry). *J Am Coll Cardiol* 1995;26(3):654–61.

*Submitted: 3 March, 2018*

*Revised: 30 December, 2018*

*Accepted: 23 January, 2019*

**Address for Correspondence:**

**Muhammad Anjum**, New doctors' residence, Punjab institute of cardiology, Jail Road, Lahore-Pakistan

**Cell:** +92 331 148 6039

**Email:** anjum\_nish@yahoo.com