

## CASE REPORT

### FIBRO DYSPLASIA OSSIFICANS PROGRESSIVA

Waqas Ahmed, Aqeel Safdar, Iftikhar Ahmed, Naveed Ahmed

Department of Surgery, Military Hospital Rawalpindi, National University of Medical Sciences Pakistan

We present a case of 7 years old boy with a very rare debilitating autosomal dominant disorder characterized by heterotopic ossification. Fibro dysplasia ossificans progressiva affects 1 in 2 million individuals with only 2 previous cases reported from this region. The disease manifests as multiple foci of bone formation in muscles, fasciae, tendons and ligaments often triggered by trauma. The child was born with bilateral short hallux valgus and aplasia of distal phalanges of both thumbs. In the last 3 years he had developed hard bony swellings in the scalp, followed by limitation of neck mobility. He developed palpable nodules on the right lateral thoracic cage over the last 1 year following trauma. Heterotopic bone formation was also seen in both tibias. FOP causes irreversible lesions of ossification thus early institution of prophylactic measures, counselling regarding avoidance of trauma and surgery can significantly reduce acute exacerbations of this rare disease.

**Keywords:** Fibro dysplasia ossificans progressive; Heterotopic ossification; Hallux valgus

**Citation:** Ahmed W, Safdar A, Ahmed I, Ahmed N. Fibro dysplasia ossificans progressiva. A rare debilitating disease. J Ayub Med Coll Abbottabad 2019;31(1):123–6.

## INTRODUCTION

Fibro dysplasia Ossificans Progressiva or more commonly Myositis Ossificans is a very rare autosomal dominant disorder comprising of ectopic osteogenesis in fasciae, ligaments, muscles, ligaments and joint capsules.<sup>1</sup> It was first described by Guy Patin in 1968. The disease is mainly diagnosed clinically on the basis of two features, i.e., The foci of heterotopic bone formation and congenital deformities of the big toes. The prevalence rate is 1: 2,000,000. The disease is pan-ethnic and doesn't have a gender predisposition.<sup>2,3</sup>

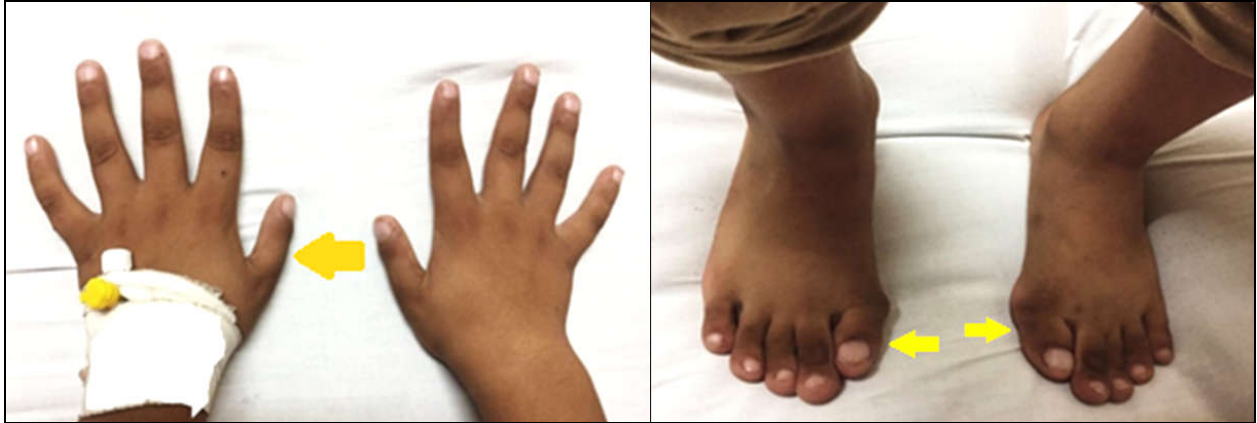Overexpression of bone morphogenetic protein (BMP-4) has been found to be associated with the disease with most cases resulting from point mutations.<sup>4</sup> There are approximately 800 known patients of the disease worldwide. Increased awareness of the disease is of utmost importance as accurate and early diagnosis is fundamental to prevention of progression to severe disease.<sup>5,6</sup>

We present a case of a seven-year-old boy who presented with multiple hard bony swellings in the scalp, neck and thorax with the aim of highlighting the challenging nature of the disease and to highlight the triggers for the bone formation (trauma & surgery). Since there is no definite cure available for the disease at present therefore minimizing the acute flare-ups and prevention of formation of newer bony swellings is the prime target.

## CASE REPORT

A 7-year-old school going boy was brought to outpatient clinic of Paediatric Surgery Department, Military Hospital Rawalpindi with a history of development of multiple hard bony swellings over the scalp, neck and thorax over the past 03 years. The bony swellings developed gradually secondary to traumatic falls and were now restricting the expansion of the chest on the right side. The child also had restricted mobility of neck on the right side. (Figure 3, 4) He had no other systemic complaints.

He was the first-born full-term baby boy with normal developmental milestones born of a consanguineous marriage. There was no family history of any skeletal or connective tissue disease. He was born with bilateral hallux valgus deformity and aplasia of distal phalanges of both thumbs. (Figure 1, 2) There was no other congenital anomaly in the child. He first developed hard swellings in the scalp after a fall at home at the age of 4 years but the parents did not consult any doctor for it. Over the course of next couple of years, he developed nodules on the right side of neck which were initially soft but gradually developed into hard bony swellings. The trigger for the formation of neck swellings was not known. However, neck movements on the right side were compromised. The child developed palpable hard nodules on the right lateral thoracic cage over the last 1 year following a traumatic fall while riding a bicycle. As the swellings hardened, there was restriction of his chest expansion more pronounced on the right side. He had a number of consultations from various hospitals where he was advised multiple options ranging from conservative treatment to surgery.



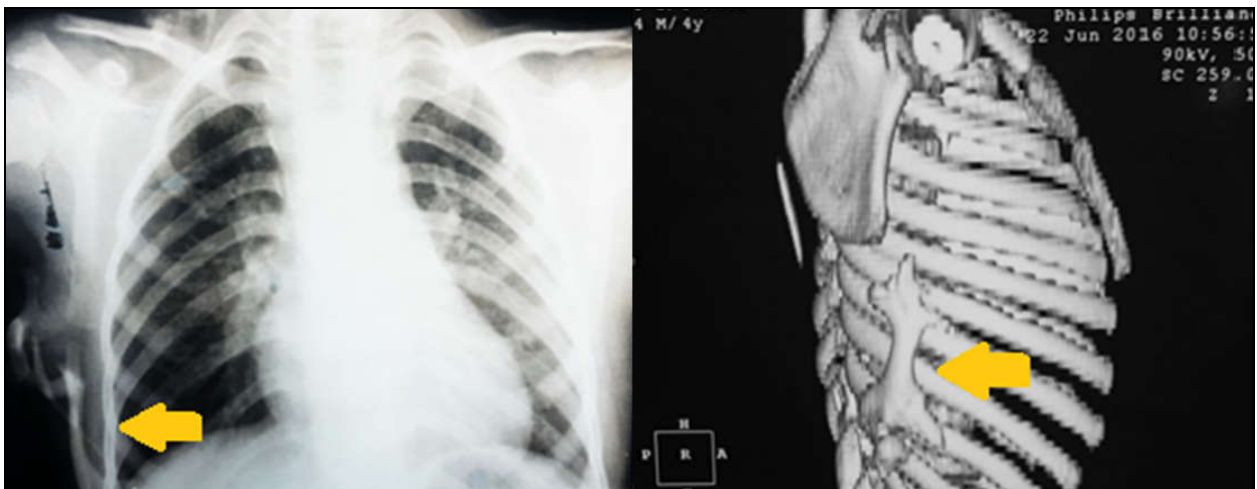
Figures-1 and 2: Clinical photograph showing aplasia of distal phalanges of both thumbs and bilateral hallux valgus deformity of big toes.

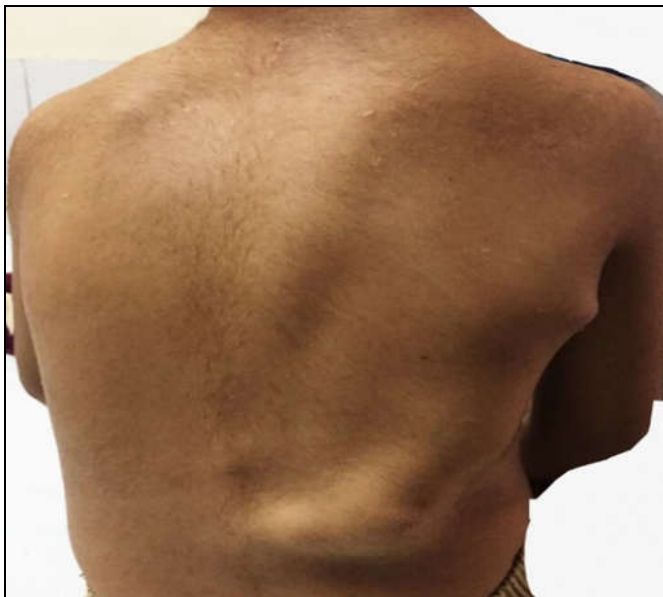

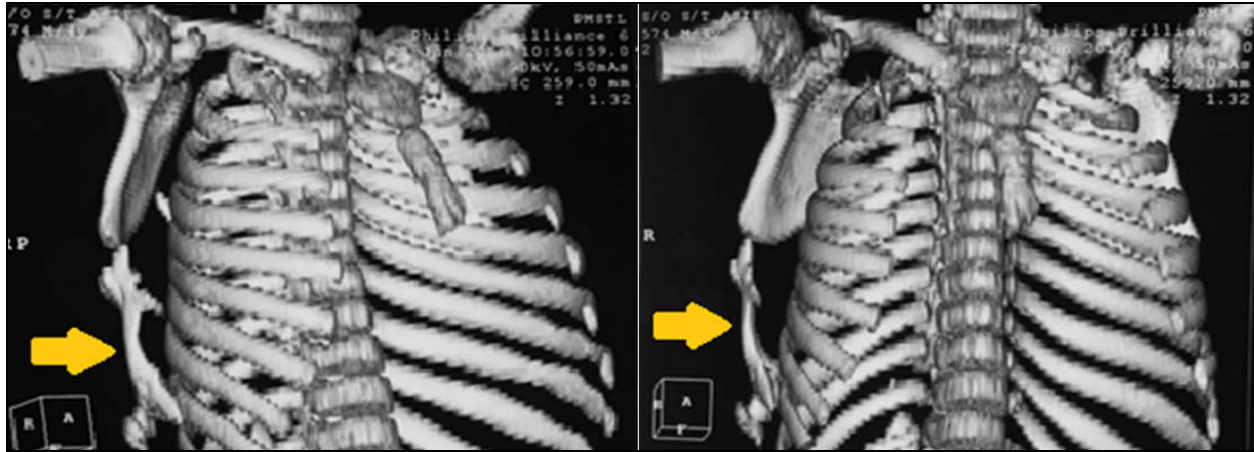
Figure-3: Shows clinical photograph showing multiple swellings on the right side of chest and back

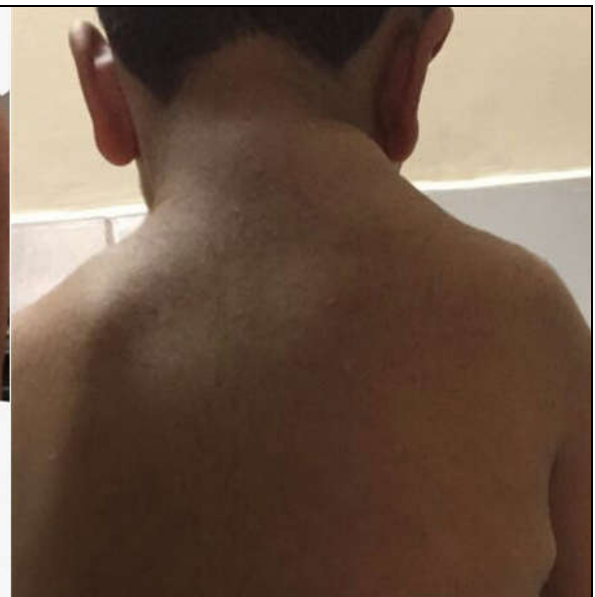

Figure-4: Shows swellings on right side of neck.

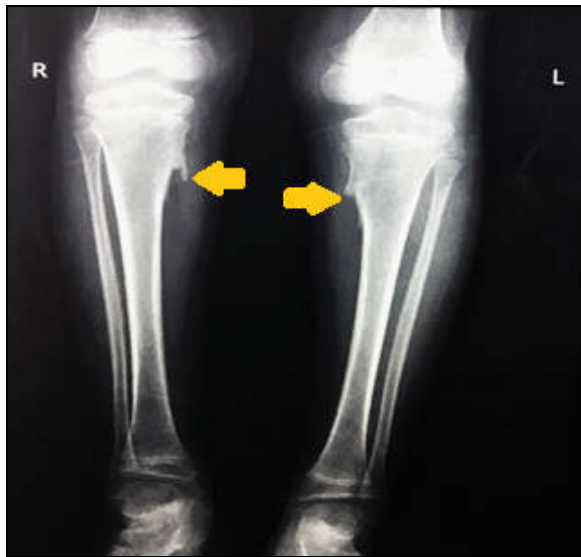

Figures-5, 6: The Chest X-Ray and HRCT Chest with 3-D Reconstruction showing ectopic bone foci.



Figures-7, 8: The Chest X-Ray and HRCT Chest with 3-D Reconstruction showing ectopic bone foci.

The radiograph of both tibia and fibula revealed medial tibial osteochondromas bilaterally. (Figure 9) Based on the history, examination and investigation a diagnosis of fibro dysplasia ossificans progressive was made.



Figures-9: The radiograph of tibia & fibula showing bilateral medial tibial osteochondromas.

The case was discussed in a multidisciplinary team meeting involving paediatric surgeon, orthopaedic surgeon and paediatrician and a conservative management plan was agreed upon. Detailed counselling of the patient and his parents was done to explain them about the nature of the disease and measures regarding avoidance of trauma. They were also counselled to avoid getting surgery as it may serve as a trigger for trauma in such patients. The boy is a school going child therefore the teachers of the child were also involved. He was discharged with advice to get regular follow up.

## DISCUSSION

Fibro dysplasia ossificans progressive (FOP) also known as Munch Meyer's disease is a rare debilitating autosomal dominant disease characterized by progressive ectopic mature lamellar bone formation in the connective tissues of the body.<sup>4</sup> Activating heterozygous mis-sense mutations in the ACVR1 gene (activin A receptor, type I) located on chromosome 2, which encodes the bone morphogenetic protein (BMP) type I receptor protein, were discovered by Shore *et al* in 2006 as the cause of FOP.<sup>7</sup>

Most of the patients present in early childhood with development of soft tissue swellings in the scalp, neck and upper torso which gradually ossify into hard bony stigmata. The swellings may initially be painful with compromise of movements of the affected body parts.<sup>4</sup> There are two characteristic features of the disease, i-e. Presence of heterotopic bone formation and hallux valgus deformity of the big toes since birth. Presence of hallux valgus deformity of big toes is pathognomonic of the condition with the deformity reported in almost 100% of the cases.<sup>9</sup> Maftai *et al* in 2014 reported the first case of FOP that was diagnosed prenatally on ultrasound by identification of the hallux valgus deformity of the big toes.<sup>10</sup> Therefore genetic testing should commence in all children born with hallux valgus deformity of big toes. More than 50% cases of the disease also have medial tibial osteochondromas (seen in our patient).<sup>11</sup>

There is no gender or ethnic predisposition for FOP. The triggers for ectopic bone formation in connective tissues include blunt trauma during routine activities or surgical procedures however spontaneous onset has also been reported in literature.<sup>12</sup> The mean age of onset of symptoms is generally five years. The sternocleidomastoid muscle is usually the initial site of involvement with the disease progressing down to involve the thoracic and lumbar regions. In severe cases there is bridging between axial and appendicular

skeleton, between ribs (as was the case in our patient) and between thorax and pelvis with severe restriction of motion. The respiratory complications include recurrent infections and atelectasis which usually occur due to restriction of chest expansion secondary to disease progression.<sup>5</sup> The disease is misdiagnosed in up to 90% of cases and resultantly may cause severe iatrogenic injuries by doing hasty surgeries.<sup>4,9</sup> The differential diagnosis includes osteosarcoma, soft tissue sarcoma, dermatomyositis, rheumatoid arthritis, desmoid tumours, aggressive juvenile fibromatosis and acquired heterotopic ossification.<sup>4, 6</sup> Laboratory investigations in these patients are usually normal. Plain radiographs can identify the deformities of hand and feet and can also identify bony bridges in different fascial planes. CT scan and MRI can detect the lesions in the perosseous stages which may manifest as oedema of the fascial planes and muscular bundles. Bone scan using Gallium 67 citrate and Tc-99 diphosphonate can also help to diagnose the lesions in earlier stages.<sup>5,6</sup> Biopsy of lesions is avoided since it can itself be a trigger to bone formation.<sup>1</sup>

Fibro dysplasia ossificans progressiva is one of the diseases in which molecular gene therapy (signal transduction inhibitors etc) directed at blocking Activin A type 1 receptor (ACVR1) might promise recovery from the predicament of the sufferers in future.<sup>13</sup> Definitive cure is not available yet and current focus of treatment is on early diagnosis, prevention of trauma, and avoidance of invasive procedures. Different treatment regimens including steroids, bisphosphonates, NSAIDs, rosiglitazone, and even radiotherapy have been tried to treat the disease but the disease progression was never curtailed.<sup>5</sup> In almost all instances in which surgery was performed resulted in recurrence and aggravation of the heterotopic bone formation. Steroids, NSAIDs and bisphosphonates have been effective in treating acute flare-ups, result in improvement of mobility and decrease the disease severity.<sup>13, 14</sup>

## CONCLUSION

Since there is no curative treatment available for patients with fibro dysplasia ossificans progressive therefore the primary goal is the earliest possible diagnosis of FOP before the heterotopic ossification occurs so as to avoid trauma or any procedure or treatment that could initiate the disease process. Children with congenital deformities of hands and feet particularly hallux valgus of big toes, possibly picked on prenatal ultrasound should raise alarm. Thorough counselling of the patient and attendants regarding

avoidance of trauma and invasive procedures and early institution of prophylactic and precautionary measures, can significantly reduce the acute exacerbations of this rare disease, Steroids, NSAIDs and bisphosphonates are the mainstay of treatment during acute flare-ups. Gene therapy directed at ACVR1 may give hope to the patients in future.

**Conflict of interest & funding:** None.

**Informed consent:** Informed consent was obtained from patient's father.

## REFERENCES

1. Vamshi R, Moorthy GVS, Prasad VKV, Vishwanath M, Srinivas C, Vivekananda B. Case Report of Fibrodysplasia Ossificans Progressiva. *Indian J Case Reports* 2016;2(4):117–20.
2. Magryta CJ, Kligora CJ, Temple HT, Malik RK. Clinical Presentation of Fibrodysplasia Ossificans Progressiva: Pitfalls in Diagnosis. *J Pediatr Hematol Oncol* 1999;21(6):539–43.
3. Zafar A, Maroof SA, Ali Z. A case of fibrodysplasia ossificans progressiva with primary ammenorrhea. *KUST Med J* 2010;2(2):73–5.
4. Sferopoulos NK, Kotakidou R, Petropoulos AS. Myositis ossificans in children: a review. *Eur J Orthop Surg Traumatol* 2017;27(4):491–502.
5. Al-Salmi I, Raniga S, Al-Hadidi A. Fibrodysplasia Ossificans Progressiva - Radiological Findings: A Case Report. *Oman Med J* 2014;29(5):368–70.
6. Hashemi J, Shahfarhat A, Beheshtian A. Fibrodysplasia Ossificans Progressiva: Report of a Case and Review of Articles. *Iran J Radiol* 2011;8(2):113–7.
7. Shore EM, Xu M, Feldman GJ, Fenstermacher DA, Cho TJ, Choi IH, *et al*. A recurrent mutation in the BMP type I receptor ACVR1 causes inherited and sporadic fibrodysplasia ossificans progressiva. *Nat Genet* 2006;5(38):525–7.
8. Shaikh N, Arif F. Fibrodysplasia Ossificans Progressiva. *J Pak Med Assoc* 2011;61(4):397–9.
9. Raees-Karami SR, Jafarieh H, Ziyayi V, Foumani RS, Aghighi Y. Evaluation of 20 years' experience of fibrodysplasia ossificans progressiva in Iran: lessons for early diagnosis and prevention. *Clin Rheumatol* 2012;31(7):1133–7.
10. Maftai C, Rypens F, Thiffault I, Dubé J, Laberge AM, Lemyre E. Fibrodysplasia ossificans progressiva: bilateral hallux valgus on ultrasound a clue for the first prenatal diagnosis for this condition-clinical report and review of the literature. *Prenat Diagn* 2015;35(3):305–7.
11. Deirmengian GK, Hebel NM, O'Connell M, Glaser DL, Shore EM, Kaplan FS. Proximal tibial osteochondromas in patients with fibrodysplasia ossificans progressiva. *J Bone Joint Surg Am* 2008;90(2):366–74.
12. Zhang W, Zhang K, Song L, Pang J, Ma H, Shore EM, *et al*. The phenotype and genotype of fibrodysplasia ossificans progressiva in China: A report of 72 cases. *Bone* 2013;57(2):386–91.
13. Pignolo RJ, Shore EM, Kaplan FS. Fibrodysplasia ossificans progressiva: diagnosis, management, and therapeutic horizons. *Pediatr Endocrinol Rev* 2013;10(Suppl 2):437–48.
14. Kaplan FS, Shore EM, Glaser DL, Emerson S. The medical management of fibrodysplasia Ossificans Progressiva current treatment considerations. *Clin Proc Intl Clin Consort FOP* 2011;4:1–100.

Submitted: 14 March, 2018

Revised: --

Accepted: 2 November, 2018

## Address for Correspondence:

Waqas Ahmed, Military Hospital Rawalpindi; National University of Medical Sciences Pakistan

Cell: +92 300 536 5579

Email: waqasahmedsurgeon@gmail.com