

## ORIGINAL ARTICLE

## PATTERN OF PRESENTATION OF NASAL FOREIGN BODIES, AN EXPERIENCE WITH 155 PATIENTS

Tahira Sajid, Mohammad Imran Shah, Syeda Rifaat Qamar Naqvi

ENT Department, Ayub Medical Institution, Abbottabad

**Background:** Children commonly present to outpatient department with foreign bodies in the nose. Sometimes the history is straightforward but not infrequently presentation is with a foul-smelling unilateral discharge and obstruction. Most of the foreign bodies are inert and do not cause any local tissue reaction but some of these can cause serious complications. The frequency of the different types of foreign bodies is not known in our setup. Our study aims to determine the types and frequencies of different foreign bodies in our catchment area so as to make the attending surgeon aware of the different possibilities he may have to encounter. Also, we aimed to make the general public aware of the hazards which the foreign bodies can create. **Methods:** This descriptive cross-sectional study was carried out at Department of ENT of Ayub Teaching Hospital Abbottabad, from 1<sup>st</sup> June to 30<sup>th</sup> November 2017. During the period of study, patients presenting in outpatient department with nasal foreign bodies were included in the study. We recorded patients' age and gender. Types of foreign bodies recovered from the nose were documented and their frequency was calculated. **Results:** A total of 155 patients were included in the study. 60% of the foreign objects were inserted in the nasal passage by male children. Children below the age of 4 years comprised more than 55% of the cases. Mean age 4.5±2.36 years. Right nostril was predominantly involved (58%). Various seeds were commonly retrieved (40%). Plastic beads were the second most common foreign bodies (21.2%). Other foreign bodies found were buttons (9%), dry batteries (1.2%), stones (9%), toy pieces (4.5%), and food particles (10%). **Conclusion:** The commonest nasal foreign objects in children were organic seeds followed by plastic beads.

**Keywords:** Nasal cavity; Foreign body; Airway, Airway Obstruction

**Citation:** Sajid T, Shah MI, Naqvi SRQ. Pattern of presentation of nasal foreign bodies, an experience with 155 patients. J Ayub Med Coll Abbottabad 2018;30(4):548-50.

## INTRODUCTION

Foreign body nose has always been a challenge for the treating Otorhinolaryngologist because of the diversity in types of the foreign bodies. Intra-nasal foreign bodies have been frequently reported in children. In adults, nasal foreign bodies are rare and if reported may be due to injury in accident, trauma or associated with coexisting mental disorders.<sup>1-4</sup>

Various studies have described different foreign objects found in the nasal cavities around the world. These objects can be inorganic including beads, buttons, stones, battery cells and toy parts or organic such as food particles, seeds, wood, etc.<sup>5,6</sup> Sometimes the history is not straight forward and the patient may present with unilateral nasal obstruction, foul smelling nasal discharge, epistaxis, sneezing, and non-specific features like headache, pain & temperature.<sup>5</sup>

Most of the foreign bodies are inert and can remain in the nose for years without causing any damage to nasal mucosa. However, some foreign objects initiate congestion, swelling of the mucosa, ulceration, mucosal destruction and epistaxis. Serious complications like septal perforation or necrosis can occur with button batteries.<sup>7</sup> There are certain foreign bodies, such as vegetables which absorb water from the tissues and swell and can evoke an intense inflammatory

reaction that can be sufficient to produce toxemia.<sup>8</sup> Thus several significant complications may occur with the presence of a nasal foreign body, that include formation and development of rhinoliths, erosion into a contiguous structure, toxic shock syndrome and development of infections in surrounding structures including acute sinusitis or otitis media, periorbital cellulitis, meningitis, acute epiglottitis, diphtheria, and tetanus.<sup>9,10</sup> The foreign bodies that stay for a long-time act as a nuclei for concretion to form calculus deposits and become encrusted with calcified material and granulation tissue.<sup>11</sup>

We have no local data as regards the different types of foreign bodies in Hazara, Gilgit Baltistan and Kohistan area.<sup>12</sup> The objective of this study would be to determine the frequency of different types of foreign body nose. This data is needed to facilitate the attending health care professional in urgent identification and removal of the foreign body. It will also be useful to make the general public aware of different types of foreign bodies with a view to prevent their occurrence and thus saving patients from morbidity. However other studies found the most common nasal foreign bodies are plastic beads (27%), foam and paper (23%), food material (15%), button battery (7%); and others including seeds, stones, buttons, erasers and crayons (28%).<sup>13</sup>

**MATERIAL AND METHODS**

This descriptive cross-sectional study was conducted at department of ENT, Ayub Teaching Hospital, Abbottabad from 1 June to 30 November 2017.

Children aged 1 through 10 years, from both sexes, who had history of impacted nasal foreign body, confirmed on clinical examination, were included in our study. Moreover, accidentally found nasal foreign bodies on rhinological examination even when the history was not given, were also included in our study.

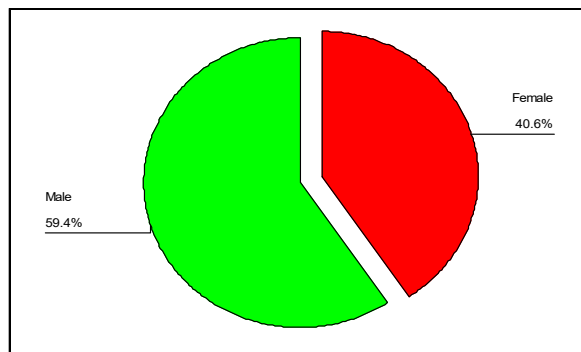
Patients with living foreign bodies, rhinoliths and symptoms suggestive of nasal foreign body but actually had no foreign body, were excluded from our study. An informed written consent was taken from parents/attending relatives before data collection, after explaining the nature of procedure and anesthesia (if any). Confidentiality of the data was ensured. The institutional ethical committee had granted approval for the study. Data was collected from history and physical examination on a proforma and entered in SPSS 10 for processing. Frequency and percentages of various categorical variables were measured.

**RESULTS**

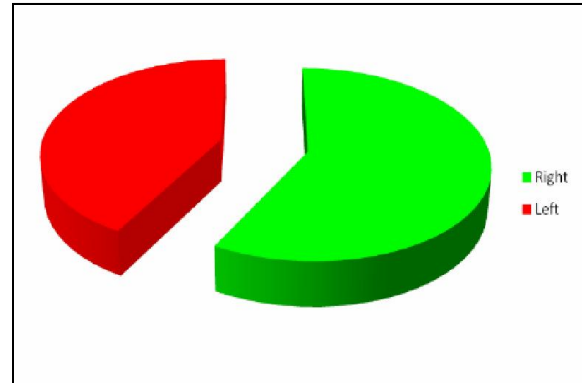
The mean age of the patients was 4.30±2.36 years Age stratification is shown in table-1. Gender distribution is shown in figure-1 comprising of 93 (60%) males and 62 (40%) females. Side of the foreign body revealing 90 (58%) on right side and 65 (42%) on the left side is depicted in figure 2. The nature and type of foreign bodies is shown in figure 3, comprising plastic beads 21.2%, seeds 40%, dry battery 1.2%, button 9%, stones gravel 9%, toy pieces 4.5%, food particles 10% and metallic particles 5.1% patients.

**Table-1: Distribution of patients by age (n=155)**

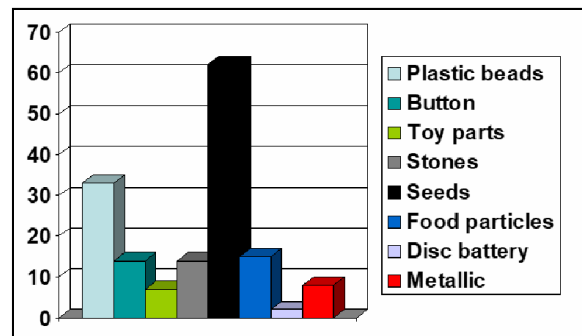
Age	No. of patients	Percentage
1-2	33	21.3
3-4	67	43.2
5-6	24	15.5
7-8	21	13.5
9-10	10	6.5
Mean±SD	4.30±2.36	
Range	1-10	



**Figure-1: Distribution of Patients by Sex (n=155)**



**Figure-2: Distribution of foreign body nose by site of impaction**



**Figure 3: Distribution of Patients by type of foreign body (n=155)**

**DISCUSSION**

This descriptive cross-sectional study has been conducted to determine the frequency of the different types of foreign bodies found in the nose of the children. This is the largest study in Pakistan (including 155 patients) which demonstrates the pattern of presentation of pediatric nasal foreign bodies. Before these many studies were carried out on foreign bodies in tracheobronchial airway and esophagus but, no study was carried out in our area regarding nasal foreign bodies. However, there are many cases reports available in literature about the foreign bodies in the nose.

The mean age of the patients in our study was 4.30±2.36 years which shows that foreign bodies in nose are common among children of younger age. In our study 58% of the foreign bodies were found on right side of nose while remaining were found on left side with no bilateral foreign bodies found. Memis M in a study found mean age to be 3.65±2.31 years with plastic toys (43.8%) being the most commonly encountered foreign bodies and 56.9% were found on right side of nose<sup>14</sup> Cetninkaya EA, *et al* also reported that the nasal foreign bodies were mostly found in patients with ages 2-5 years<sup>15</sup> This gives strong evidence that foreign body nose is commonly seen among children of younger age group. Majority of the patients in our study were males which correspond to the studies performed by Abou-

Elfadl M illustrating male predominance (1.4) with mean age 3 years<sup>16</sup> His finding is almost similar to the study by Yaroko who described male predominance (60.5%) with most foreign bodies seen at age of 3 years (48.83%)<sup>17</sup>.

In our study organic seeds were the commonest foreign bodies found in nose, 62 (40%) patients followed by plastic beads which were found in 33 (21.2%) patients. Wang Y also described in his study that vegetable foreign bodies were most commonly found with frequency of 61.8%.<sup>18</sup> Orech AC also described different types of nasal foreign bodies with beads comprising 27% of foreign bodies in nose followed by seeds which constituted 22.1 %<sup>19</sup>. Another study by Svider PF, which also documented the types of foreign bodies with most common foreign bodies being jewelry beads, paper products, food, plastic toys, and small household items.<sup>20</sup> Another study by Kiger *et al* found the commonest foreign body to be a plastic toy or bead.<sup>7</sup>

Organic seeds can cause local erosion by release of oils, and can also cause foreign body reaction which will lead to permanent damage to septum and long-term sequelae. Same is the case with button batteries. Prompt identification of the nature of foreign body will definitely help the caregiver to decide immediately regarding the management of foreign body.

## CONCLUSION

Although children can present to the Otorhinolaryngologist with any foreign object in their nose, the most common foreign objects are seeds followed by plastic beads. Early recognition and adaptation of prompt actions for removal can avoid complications associated with nasal foreign bodies especially battery cells and organic foreign bodies.

## AUTHORS' CONTRIBUTION

TS: Literature search, data analysis, data interpretation, write up. MIS: Data collection, conceptualization of study, write up. SRQN: literature search, write up, proof reading.

## REFERENCES

- Okoye BC, Onotai LO. Foreign bodies in the nose. Niger J Med 2006;15(3):301-4.
- Burduk PK, Garstecka A, Betlejewski S. Nasal foreign body in an adult. Eur Arch Otorhinolaryngol 2005;262(6):517-8.
- Tariq M, Akram A, Khan AM, Elahi F, Akbar F. Bilateral intranasal button batteries. Ann King Edward Med Univ 2007;13(1):1-2.
- Tay AB. Long-standing intranasal foreign body: an incidental finding on dental radiograph: a case report and literature review. Oral Surg Oral Med Oral Pathol Oral Radiol Endod 2000;90(4):546-9.
- Figueiredo RR, Azevedo AA, Kos AO, Tomita S. Nasal foreign bodies: description of types and complications in 420 cases. Braz J Otorhinolaryngol 2006;72(1):18-23.
- Ogunleye AO, Sojebi OA. Nasal foreign bodies in the African children. Afr J Med Med Sci 2004;33(3):225-8.
- Kiger JR, Brenkert TE, Losek JD. Nasal foreign body removal in children. Pediatr Emerg Care 2008;24(11):785-92.
- Kalan A, Tariq M. Foreign bodies in the nasal cavities: a comprehensive review of the aetiology, diagnostic pointers, and therapeutic measures. Postgrad Med J 2000;76(898):484-7.
- Oh TH, Gaudet T. Acute epiglottitis associated with nasal foreign body: occurrence in a 30-month-old girl. Clin Pediatr (Phila) 1977;16(11):1067-8.
- Sarnaik AP, Venkat G. Cephalic tetanus as a complication of nasal foreign body. Am J Dis Child 1981;135(6):571-2.
- Cheng PT, Pritzker KP, Richards J, Holmyard D. Fictitious calculi and human calculi with foreign nuclei. Scanning Microsc 1987;1(4):2025-32.
- Fischer JJ, Tarabar A. Foreign Bodies, Nose: eMedicine Emergency Medicine 2008. [Internet]. [cited 2018 Jan]. Available from: URL: <http://emedicine.medscape.com/article/763767-overview>.
- Glynn F, Amin M, Kinsella J. Nasal foreign bodies in children: should they have a plain radiograph in the accident and emergency? Pediatr Emerg Care 2008;24(4):217-8.
- Memiş M, İlhan E, Ulucanlı S, Yaman H, Güçlü E. Nasal foreign bodies: an analysis of 130 patients. Kulak Burun Bogaz İhtis Derg 2015;25(2):109-12.
- Cetinkaya EA, Arslan İB, Cukurova İ. Nasal foreign bodies in children: Types, locations, complications and removal. Int J Pediatr Otorhinolaryngol 2015;79(11):1881-5.
- Abou-Elfadl M, Horra A, Abada RL, Mahtar M, Roubal M, Kadiri F. Nasal foreign bodies: Results of a study of 260 cases. Eur Ann Otorhinolaryngol Head Neck Dis 2015;132(6):343-6.
- Yaroko AA, Baharudin A. Patterns of nasal foreign body in northeast Malaysia: A five-year experience. Eur Ann Otorhinolaryngol Head Neck Dis 2015;132(5):257-9.
- Wang Y, Su H, Wu Y, Zhao Y. Clinical analysis of 249 cases of children with foreign bodies in the nasal cavity and paranasal sinus. Lin Chung Er Bi Yan Hou Tou Jing Wai Ke Za Zhi 2016;30(3):233-4.
- Orech AC, Folorunsho D, Ibekwe TS. Actualities of management of aural, nasal, and throat foreign bodies. Ann Med Health Sci Res 2015;5(2):108-14.
- Svider PF, Sheyn A, Folbe E, Sekhsaria V, Zuliani G, Eloy JA, Folbe AJ. How did that get there? A population-based analysis of nasal foreign bodies. Int Forum Allergy Rhinol 2014;4(11):944-9.

Received: 11 June, 2018

Revised: 7 July, 2018

Accepted: 3 October, 2018

## Address for Correspondence:

Dr. Tahira Sajid, ENT Department, Ayub Medical Institution, Abbottabad-Pakistan

Email: tahirahsk@yahoo.com