

ORIGINAL ARTICLE

EXPLORING DEMOGRAPHICS AND OUTCOMES FOR SPINAL TUMOURS FOLLOWING SURGERY IN COMBINED MILITARY HOSPITAL, PESHAWAR

Muhammad Junaid, Afeera Asheen, Muneeb Ur Rehman*, Mamoon Ur Rashid, Syed Sarmad Bukhari**, Mamoon Ahmed***

Combined Military Hospital, Peshawar, *Army Medical College, National University of Sciences and Technology, Islamabad, **Khyber Teaching Hospital, Peshawar-Pakistan

Background: Tumours of the spinal cord, spinal meninges and cauda equina are relatively rare and their spectrum has not been studied extensively in Khyber Pakhtun Khawa province. We describe here the cases of spinal tumours treated in our setup over a period of two years. **Methods:** This Descriptive Case Series was carried out with of 80 patients operated in our centre from January 2013 to January 2015. The clinical presentation of these tumours as well as demographic findings was analysed. Patients who underwent surgery for their tumours were included in the study. Patients were selected for surgery depending on their radiological and clinical findings. Lesions that were suggestive of metastasis were biopsied and further care was shared between specialized departments depending on the primary source. **Results:** Male to female ratio was 1.5:1. Most of the spinal tumours were secondary tumours while meningiomas were the most common primary tumours. Most commonly patients belonged to young age group A (below 30 years.) 32.5%. Most common presentation was with paraparesis (27.5%) and paralysis (25%). A majority of patients regained good neurological function and did not show signs of recurrence at 1 year follow up. **Conclusion:** Given the limited experience at our centre, we believe that a wide range of spinal tumours can be successfully treated provided that clinical end points are kept in mind and treatment is individualized. Frankel grading is useful to assess surgical outcome in the patients.

Keywords: Epidemiology; Histology; Malignancy; Meningioma; Spinal tumour

J Ayub Med Coll Abbottabad 2015;27(4):869–73

INTRODUCTION

Involvement of the spinal cord by a neoplastic growth can be due to a variety of reasons, each with its unique aetiology. Spinal neoplasm is a blanket term that includes tumours arising primarily from the nervous tissues of the spinal cord, tumours arising from the structures surrounding the spinal cord or tumours that have spread from other locations to involve the spinal cord.¹

After leukemia, tumours of the central nervous system are the most common form of neoplasia in children.² Common sources of metastatic tumours to the spinal cord include lung, breast, skin (malignant melanoma) and kidney (in decreasing order of frequency). Metastatic tumours present as multiple, well-circumscribed lesions at the grey-white junction. Primary tumours are classified (World Health Organization's Classification, 2000) according to the cell type of origin, i.e, astrocytes, meningothelial cells, ependymal cells, schwannomas or oligodendrocytes. Glioblastoma multiforme is a high-grade malignant tumour of astrocytes and is the most common primary CNS tumour of adults and carries a poor prognosis with a mean survival of 3 months without treatment.^{2,3}

Meningioma is the most common benign CNS tumour in adults. It is more commonly seen in women; rarely in children because the tumour cells have oestrogen and progesterone receptors.⁴ Meningiomas account for 13–19% of total intracranial tumours.^{5,6} Spinal meningiomas represent 12% of all meningiomas and 25–45% of intradural spine tumours.⁷ Spinal meningiomas lead to spinal cord compression symptoms and myelopathy. Surgery is the definitive treatment.⁸

Ependymoma arises in the cauda equina in the adults and forth ventricle in children.⁹ Ependymomas are glial in origin that morphologically resembles ependymal cells which line the ventricles of the central nervous system.¹⁰ Ependymomas account for 3–6% of all CNS tumours. In children and young adults, it is the second most common malignant brain tumour and its incidence is also highest in them. Usually, these tumours occur intracranially within the posterior fossa while in adults it occurs in spinal cord. Ependymomas are classified into three major subtypes histopathologically: myxopapillary ependymoma (WHO grade-I), ependymoma (WHO grade II) and anaplastic ependymoma (WHO grade III).¹¹ First line treatment is surgery, followed by radiotherapy and chemotherapy.¹²

Primary tumours of the spinal cord, spinal meninges, and cauda equina are relatively rare. Spinal tumours can present with a number of signs and symptoms. These include back pain, faecal or urinary incontinence, or paraesthesias. Ninety percent of patients with malignant spinal cord compression have pain and up to 50% of patients may be unable to walk and have sensory, bladder or bowel dysfunction.¹ MRI of the spinal cord is the most important diagnostic tool. The goal of treatment is to prevent nerve damage from compression of the spinal cord.³ Treatment options include surgical removal, corticosteroids and radio- and chemo-therapy.

The purpose of our study was to get a general picture of the spectrum of spinal tumours operated in CMH Peshawar including the age, sex, histopathological diagnosis, the level upon which the tumour was operated and the outcome of the surgery.

MATERIAL AND METHODS

Our study is a descriptive case series of patients operated in our centre for spinal tumours. We analyzed the clinical notes of all the patients diagnosed and operated in our setup for spinal tumours from Jan 2013 to Jan 2015. These patients belonged to different age, socioeconomic and geographical regions of Pakistan. The excised tissue was sent to the laboratory of our hospital for histopathological analysis and the results were recorded.

A total of 80 cases that were histopathologically diagnosed in our laboratory were included in this study. All these cases were surgical biopsy specimens, either incisional or excisional. These specimens were fixed in 10% neutral formalin, processed in routine histologic preparation and stained with H & E. Reticulin, Masson's trichrome, PAS and immunohistochemical staining. All the clinical and surgical findings along with the location of tumour were also studied. The tumours were classified according to latest WHO classification of nervous system tumours. Patients were arbitrarily divided into four groups, i.e., group-A (30 and less than 30 years), group-B (31–40 years of age), group C (41–50 years of age) and group D (Above 50 years of age)

The patients were followed up at intervals of 2 weeks, 3 months, 6 months and 1 year. The follow up period for the duration of the study was 1 year. All follow up care was carried out in our outpatient clinic and the post-operative neurological status was compared to pre-operative status by using Frankel grading. Functional

outcome and return to original job was also determined. MRI with and without contrast was used to determine if local recurrence was present at follow up interval of 2nd week and 6th month. Frankel grading is a useful clinical tool to test the spinal cord function after the spinal trauma. In our research, we used it to assess the neurological status of the patients, preoperatively and postoperatively, for the surgical outcome. It was very useful, convenient and less time consuming. Following grades were used:

Grade-A: When there is complete paralysis

Grade-B: Only Sensory functions are lost below the level of injury

Grade-C: Motor functions are lost below the level of injury

Grade-D: When motor function below injury level was fair to good

Grade-E: All functions were normal

RESULTS

A total of 80 cases were included in our study. Out of these, 60% were male and 40% were females. Majority of patients were young (32.5%) and belonged to group A (below 30 years). The frequency of tumours in other age groups is given in the table-1.

The histopathological reports of each of these cases revealed the frequencies which are shown in table-2. Secondary tumours (Metastasis) were most common tumours (25%) in the spinal cord, with metastasis from papillary carcinoma of thyroid (3 patients), small cell carcinoma of lung (8 patients), breast carcinoma (1 patient), hepatocellular carcinoma (5 patients) and renal cell carcinoma (3 patients). Commonest primary spinal tumours were benign meningiomas (15%), followed by spinal nerves schwannomas (12.5%).

From the Figure-1, it is clear that Metastatic tumours, Osteoblastomas, Multiple Myeloma and Spinal Arteriovenous Malformations (AVM) were more common in the males, while Meningiomas and Spinal Nerves Schwannomas were common in the females.

Majority of the patients (Figure-2) were from Peshawar (30%), Mardan (12.5%), Sawabi (10%) and Charsadda (10%).

The clinical presentations (table 3) of the patients were with backache, heaviness in limbs, paraparesis, numbness, paraplegia, post cervical swelling, quadriparesis, sciatica and sphincter disturbance. Most of the patients presented with paraparesis (27.5%), paraplegia (25%) and sciatica (17.5%),

The surgical outcome of the patients according to the Frankel grading system, which

was used for the assessment of the patients, is shown in the table-5. Improvement, as measured by Frankel grading, was seen in 90% of patients while rest of the patients (10%) continued to have the symptoms. We found out that the results of surgeries for Meningiomas, Spinal Nerve Schwannomas, Spinal AVM, Non-Hodgkin Lymphomas, Ependymomas, Ewing's Sarcomas were good with improvement in Frankel grades while for Osteoblastomas, Dermoid cysts and Primitive Neuroectodermal tumours, patients continued to have the symptoms and no improvement was seen on Frankel grading. The details of patient's pre-operative and post-operative neurological status are mentioned in the table-4. Some of the patients had no neurological deficit.

Most of tumours involved cervical region (30%), cervicothoracic region (20%), thoracic region (35%) and conus region (10%). Surgeon was able to do complete resection in (75%) of the cases and partial resection and biopsy in (25%) of cases. No cases of further neurological worsening were seen after operation.

Table-1: Frequency of patients in age groups

Age Group	Frequency	Percentage
Group A (30 and less than 30 years)	26	32.5%
Group B (31-40 years of age)	14	17.5%
Group C (41-50 years of age)	18	22.5%
Group D (Above 50 years of age)	22	27.5%
Total	80	100.0%

Table-2: Different types of spinal tumours

Histopathological diagnosis	Frequency	Percent
Arachnoid cyst	2	2.5
Dermoid cyst	6	7.5
Diffuses large B cell NHL	2	2.5
Ependymoma	8	10.0
Ewing's Sarcoma	4	5.0
Meningioma	12	15.0
Metastasis	20	25.0
Multiple Myeloma	2	2.5
Osteoblastoma	4	5.0
Primitive Neuroectodermal Tumours	2	2.5
Schwanoma	10	12.5
Spinal AVM	6	7.5
Astrocytomas	2	2.5
Total	80	100.0

Table-3: Various presenting complaints of the patients

Presenting complaints	Frequency	Percentage
Backache	12	15.0%
Heaviness in upper limbs	4	5%
Paraparesis	22	27.5%
Paraparesis + numbness in lower limbs	2	2.5%
Paraplegia	20	25.0%
Post cervical swelling	2	2.5%
Quadraparesis	2	2.5%
Sciatica	14	17.5%
Sphincteric disturbance + Sciatica	2	2.5%
Total	80	100.0%

Table-4: Preoperative and Postoperative neurological status of patients assessed 2 weeks after operation

Tumour	Pre-Op Status	Post-Op Status
Arachnoid Cyst [2 Patients]	No Deficit	No Deficit
Dermoid Cyst [4 Patients]	Frankel C	Frankel C
Dermoid Cyst [2 Patients]	No Deficit	No Deficit
Diffuse Large B Cell Nhl [2 Patients]	Frankel C	Frankel E
Ependymoma [2 Patient]	Frankel C	Frankel E
Ependymoma [6 Patient]	No Deficit	No Deficit
Ewing's Sarcoma [2 Patient]	Frankel A	Frankel C
Meningioma [12 Patients]	Frankel C	Frankel E
Metastasis [4 Patients]	Frankel A	Frankel C
Metastasis [6 Patients]	Frankel C	Frankel E
Metastasis [10 Patients]	No Deficit	No Deficit
Multiple Myeloma [2 Patients]	No Deficit	No Deficit
Osteoblastoma [2 Patients]	No Deficit	No Deficit
Osteoblastoma [2 Patients]	Frankel E	Frankel E
PNET [2 Patients]	Frankel E	Frankel E
Schwanoma [2 Patients]	Frankel A	Frankel C
Schwanoma [6 Patients]	Frankel C	Frankel E
Schwanoma [2 Patients]	No Deficit	No Deficit
Spinal AVM [2 Patients]	Frankel A	Frankel D
Spinal AVM [2 Patients]	Frankel C	Frankel E
Spinal AVM [2 Patients]	No Deficit	No Deficit
Astrocytomas [2 Patients]	No Deficit	No Deficit

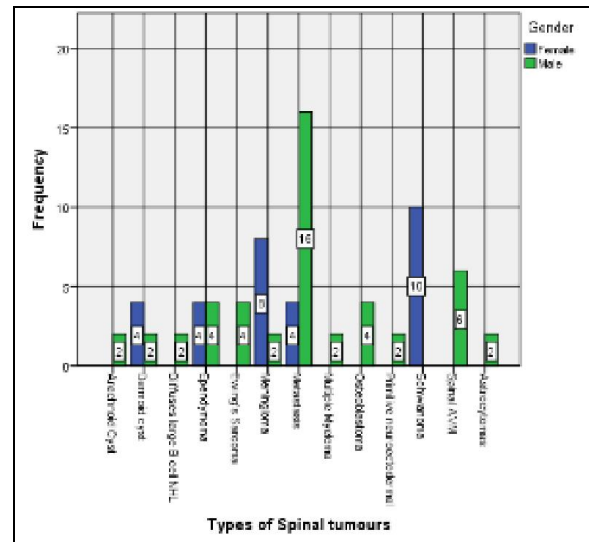


Figure-1: Gender distribution of spinal tumours

DISCUSSION

Primary tumours of spinal cord, spinal meninges and cauda equina, which are collectively known as spinal tumours are relatively rare^{13,14} and there is dearth of literature present on their epidemiology¹⁵. This lack of knowledge can seriously affect the mode of treatment and prognosis of these tumours.

Our study provides a deeper insight into the epidemiology of spinal tumours in our setup. As we have been treating patients from all over Khyber Pakhtunkhwa, hence our study carries a good significance on a provincial level.

Our study reveals meningiomas to be one of the most common (15%) spinal tumours. A previous study by Schellinger *et al*, supports this claim, although the percentage of meningiomas in their study was 29%.¹⁵ Meningiomas were also the most prevalent in US but their frequency was also much higher at 33%.¹⁶

Meningiomas most frequently occur in middle-aged females.^{17,18} All the twelve cases diagnosed with meningiomas in our study were above 45 years of age. Eight of these cases presented with paraparesis while four presented with sciatica. We treated all these cases with total excision and obtained excellent results.

The results of our study are comparable to the results of study by Sandalcioglu *et al*.¹⁹ In our study tumours in cervical and cervicothoracic region were (50%), thoracic region were (35%) and conus region were (10%). Similar results were shown by the study¹⁹, with tumours in cervical and cervicothoracic region (55%), in the thoracic region (32%) and the medullar conus (13%). Surgical outcome was good in 90% of our cases and no case was reported with further worsening of symptoms. While in the study by Sandalcioglu *et al*¹⁹, improvement or no change was seen in of (65.4%) patients, with worsening of symptoms in (34.6%). Total resection was achieved in (75%) of patients in our study as compare to the study by Sandalcioglu *et al*¹⁹, where it was achieved in (83.3%) of cases.

The grade of the tumour and extent of tumour resection play important role in determining the progression-free survival of the patient and hence it is recommended to diagnose and treat the patient as early as possible.²⁰ Similarly, other studies show that early detection and treatment of intradural spinal tumours is extremely important in preventing neurological conditions later on in life, caused by spinal cord compression.^{21,22}

Primary spinal cord tumours account for almost 5–10% of all spinal tumours and the most common ones are meningiomas and nerve sheath tumours. Our study also showed meningiomas to be the most common one. Amongst the intramedullary spinal cord tumours, astrocytomas and ependymomas are the commonest ones.²³ Study conducted by Bhatti *et al*²⁴ in the same province on intramedullary spinal tumors had the same observation. They also concluded that surgical removal of intramedullary lesions carry acceptable surgical risk with better outcome in patients with good pre-operative Frankel grade.

Arachnoidal cells are believed to be the origin of meningiomas. Meningiomas are typically benign and slow growing tumours.²⁵ Surgery is the only definitive treatment for meningiomas as they

may lead to chronic spinal cord compression and myelopathy if left untreated. However, studies show that even after a successful surgery, progressive spinal cord compression may lead to neurological deficits including permanent deterioration of neurological functions which may be due to damage that has already be done by the compression or iatrogenic.^{26–28} Previous studies show the peak incidence to be found between sixth and eighth decade of life.^{27–30} Our study claims it to be a bit different as all of our patients reporting with this were either in their fourth or fifth decade of life. We treated our patients of meningiomas with total excision and obtained good results. All our patients were treated by a single surgeon in our tertiary care facility.

CONCLUSION

Given the experience at our centre, we believe that a wide range of spinal tumours can be successfully treated provided that clinical end points are kept in mind and treatment is individualized. We found out the Frankel grading as useful tool for assessment of the spinal tumour patients preoperatively and postoperatively. Both, preoperative neurological status and type of tumours; influenced the outcome of patients.

AUTHOR'S CONTRIBUTION

MJ: Design and acquisition of data, final approval of the article, concept and design. AA: Contribution to drafting of the article. MUR: Contribution to final approval of the article. MUR: Contribution to analysis and interpretation of data, and revision of article for intellectual content. SSB: Contribution to final approval of the article. MA: Drafting of the article, contribution to conception.

REFERENCES

1. Spinal tumor: MedlinePlus Medical Encyclopedia [Internet]. 2015 [cited 2015 Feb 21]. Available from: <http://www.nlm.nih.gov/medlineplus/ency/article/001403.htm>
2. Rosemberg S, Fujiwara D. Epidemiology of pediatric tumours of the nervous system according to the WHO 2000 classification: a report of 1,195 cases from a single institution. *Childs Nerv Syst* 2005;21(11):940–4.
3. Kumar V, Abbas AK, Aster JC, editors. Robbins and Cotran pathologic basis of disease. Ninth edition. Philadelphia, PA: Elsevier/Saunders; 2015. p.1391.
4. Goljan EF. Rapid review pathology. Philadelphia, PA: Saunders/Elsevier; 2014.
5. Schick U, Marquardt G, Lorenz R. Recurrence of benign spinal neoplasms. *Neurosurg Rev* 2001;24(1):20–5.
6. Schiffer D: Brain tumours. Pathology and its Biological Correlates. *BRAIN Pathol-ZURICH-*. 1993;3:193–3.
7. Helseeth A, Mørk SJ: Primary intraspinal neoplasms in Norway, 1955 to 1986. A population-based survey of 467 patients. *J Neurosurg* 1989;71(6):842–5.

8. Setzer M, Vatter H, Marquardt G, Seifert V, Vrionis FD. Management of spinal meningiomas: surgical results and a review of the literature. *Neurosurg Focus* 2007;23(4):E14.
9. Sattar H. Fundamentals of pathology: medical course and step 1review. Chicago: Pathoma.com; 2011.
10. Hasselblatt M. Ependymal tumours. *Recent Results Cancer Res* 2009;171:51–66.
11. Louis DN, Ohgaki H, Wiestler OD, Cavenee WK, Burger PC, Jouvet A, *et al.* The 2007 WHO classification of tumours of the central nervous system. *Acta Neuropathol* 2007;114(2):97–109.
12. Paulino AC. Radiotherapeutic management of intracranial ependymoma. *Pediatr Hematol Oncol* 2002;19(5):295–308.
13. Engelhard HH, Villano JL, Porter KR, Stewart AK, Barua M, Braker FG, *et al.* Clinical presentation, histology, and treatment in 430 patients with primary tumours of the spinal cord, spinal meninges, or cauda equina. *J Neurosurg Spine* 2010;13(1):67–77.
14. Central Brain Tumor Registry of the United States. CBTRUS Statistical Report: Primary Brain tumours in the United States, 1998-2002. Hinsdale, IL: CBTRUS; 2005.
15. Schellinger KA, Propp JM, Villano JL, McCarthy BJ. Descriptive epidemiology of primary spinal cord tumours. *J Neurooncol* 2008;87(2):173–9.
16. Duong LM, McCarthy BJ, McLendon RE, Dolecek TA, Kruchko C, Douglas LL, *et al.* Descriptive Epidemiology of Malignant and Nonmalignant Primary Spinal Cord, Spinal Meninges, and Cauda Equina tumours , United States, 2004-2007. *Cancer* 2012;118(17):4220–7.
17. Gezen F, Kahraman S, Canakci Z, Bedük A. Review of 36 cases of spinal cord meningioma. *Spine (Phila Pa 1976)* 2000;25(6):727–31.
18. King AT, Sharr MM, Gullan RW, Bartlett JR. Spinal meningiomas: a 20-year review. *Br J Neurosurg* 1998;12(6):521–6.
19. Sandalcioğlu IE, Gasser T, Asgari S, Lazorisak A, Engelhorn T, Egelhof T, *et al.* "Functional outcome after surgical treatment of intramedullary spinal cord tumours : experience with 78 patients." *Spinal Cord* 2005;43(1):34–41.
20. Choi GH, Oh JK, Kim TY, You NK, Lee HS, Yoon DH, *et al.* The clinical features and surgical outcomes of pediatric patients with primary spinal cord tumor. *Childs Nerv Syst* 2012;28(6):897–904.
21. Seppälä MT, Haltia MJ, Sankila RJ, Jääskeläinen JE, Heiskanen O. Long-term outcome after removal of spinal schwannoma: A clinicopathological study of 187 cases. *J Neurosurg* 1995;83(4):621–6.
22. Klekamp J, Samii M. Surgical results for spinal meningiomas. *Surg Neurol* 1999;52(6):552–62.
23. Segal D, Lidar Z, Corn A, Constantini S. Delay in diagnosis of primary intradural spinal cord tumours. *Surg Neurol Int* 2012;3(1):52.
24. Bhatti SN, Khan SA, Raja RA, Shah R, Aurangzeb A, Khan AA, *et al.* Outcome of intramedullary spinal cord tumours: experience with 18 patients operated at Ayub Teaching Hospital, Abbottabad. *J Ayub Med Coll Abbottabad*. 2010;22(3):15-7
25. Lantos PL, Vandenberg SR, Kleihues P, tumours of the nervous system. Graham DI, Lantos PL: Greenfield's Neuropathology ed 6. London: Oxford University Press, 1997, p.583–879.
26. Gezen F, Kahraman S, Canakci Z, Bedük A. Review of 36 cases of spinal cord meningioma. *Spine (Phila Pa 1976)* 2000;25(6):727–31.
27. Gottfried ON, Gluf W, Quinones-Hinojosa A, Kan P, Schmidt MH. Spinal meningiomas: surgical management and outcome. *Neurosurg Focus* 2003;14(6):e2.
28. Peker S, Cerçi A, Ozgen S, Isik N, Kalelioglu M, Pamir MN. Spinal meningiomas: evaluation of 41 patients. *J Neurosurg Sci* 2005;49(1):7–11.
29. Slooff JL, Kernohan JW, MacCarty CS. Primary Intramedullary tumours of the Spinal Cord and Filum Terminale Philadelphia, WB Saunders, 1964.
30. Chen TC, Chamberlain MC. Adjuvant therapy for unresectable meningiomas: benign and malignant. *Neurosurg Focus* 2007;23(4):1.

Address for Correspondence: (KINDLY CHECK THE LINE SIZE)

Dr. Mamoon Ahmed, House 391, Lane 1, Aslam Shaheed Road, Lalazar, Rawalpindi Cantt-Pakistan

Cell: +92 331 500 5539

Email: mamoonmalick@gmail.com