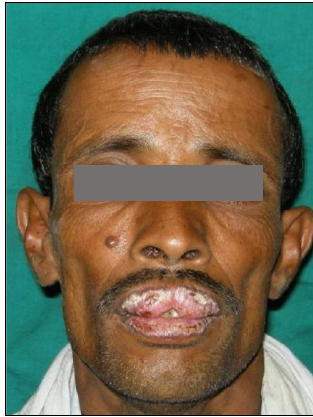

## PICTORIAL

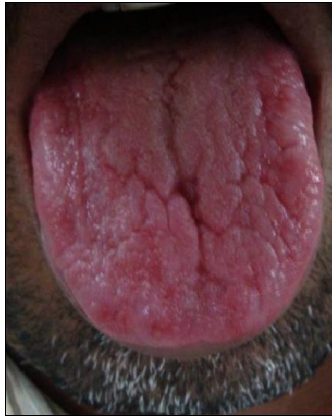## MELKERSSON–ROSENTHAL SYNDROME–A RARE FINDING

Manas Bajpai, Nilesh Pardhe

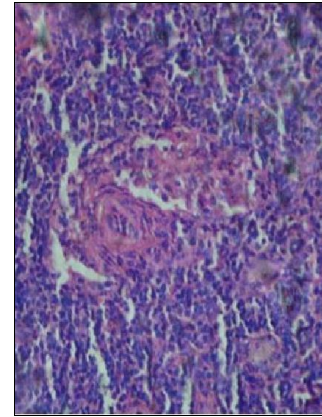
Department of Oral and Maxillofacial Pathology, NIMS Dental College, Jaipur, Rajasthan-India



**Figure-1: Swollen lips with cracking surfaces**



**Figure-2: Scrotal tongue**



**Figure-3: Histological examination reveals multiple non-caseating granulomas with epithelioid cells and lymphocytes**

A 43 year old male presented with the chief complaint of non-painful swelling of upper and lower lips from past one year. At anamnesis, we did not find any allergic disease, trauma and/or past recent injuries. Personal history revealed a facial palsy at the age of ten years as a singular manifestation. The physical examination revealed a painful, swollen upper and lower lip with bleeding and cracking on the surface (Figure-1) and scrotal tongue (Figure-2). Presence of all three manifestation from the past until present, prompted us to perform a biopsy from lip. Histological examination revealed several non caseating granulomas made up of lymphocytes centrally and large epithelioid cells at periphery, many multinucleated giant cells some of them are langerhans type dispersed in the connective tissue stroma, Areas of lymphoid follicle with germinal center were also seen (Figure-3). With the correlation of all the findings, a final diagnosis of monostotic Melkersson – Rosenthal syndrome was made.

Melkersson – Rosenthal syndrome (MRS) is a very rare clinical entity. Its classical form is characterized by following triad: Facial nerve palsy, cheilitis granulomatosa and fissured tongue.<sup>1</sup> The presence of two or one manifestation mentioned above with cheilitis granulomatosa in biopsy, is sufficient to diagnose monostotic MRS.<sup>2</sup> Patients with a moderate form of granulomatous cheilitis show more benefit from the administration of steroids. Surgery is reserved for patients whose cheilitis does not respond to steroid therapy or who present a reasonable face deformation.<sup>3</sup>

J Ayub Med Coll Abbottabad 2016;28(1):214

## REFERENCES

1. Ang KL, Jones NS, Melkersson–Rosenthal syndrome. *J Laryngol Otol* 2002;116(5):386–8.
2. Cocuroccia B, Gubinelli E, Annessi G, Zambruno G, Girolomoni G. Persistent unilateral orbital and eyelid oedema as a manifestation of Melkersson–Rosenthal syndrome. *J Eur Acad Dermatol Venereol* 2005;19(1):107–11.
3. Răchișan AL, Hrușcă A, Gheban D, Căinap S, Pop TL, Băican A, *et al.* Granulomatous cheilitis of Miescher: the diagnostic proof for a Melkersson-Rosenthal syndrome. *Rom J Morphol Embryol* 2012;53(3 Suppl):851–3.

## Address for Correspondence:

**Dr. Manas Bajpai**, Department of Oral and Maxillofacial Pathology, NIMS Dental College, Shobha Nagar, Jaipur-Delhi Highway (NH-11C), Jaipur-303121, Rajasthan-India

**Tel:** +91 9799415000

**Email:** dr.manasbajpai@gmail.com