

CASE REPORT

BEHCET'S DISEASE PRESENTING WITH LIFE THREATENING
MANIFESTATION OF CEREBRAL VENOUS THROMBOSIS

Ushna Naveed, Aneela Iqbal, Qurrat-Ul Ain, Muhammad Afzal Hamdani, Mujeeb-Ur-Rehman Abid Butt, Muhammad Atif Ashraf

Department of Medicine, Shalamar Hospital Lahore-Pakistan

Behcet's disease (BD) presents as uncommon inflammatory disorder involving multiple systems, identified by longstanding relapsing path. Its chief manifestations are oral and genital ulcers together with involvement of the eyes, skin and joints. Neurological and vascular complications are significant. We report a case of a twenty-four years old young male who presented with headache, fever, and vomiting along with decreased vision; and repeated oral and genital ulcers. Diagnosis of BD complicated with cerebral venous thrombosis (CVT) was made. He was treated with corticosteroids, immunosuppression therapy and colchicine along with anticoagulation therapy. He responded well to the given treatment. Cerebral venous thrombosis complications in with BD can lead to serious consequences. Early recognition and treatment may lessen poor outcomes.

Keywords: Behcet's disease; Life threatening manifestation; Cerebral venous thrombosis

Citation: Naveed U, Iqbal A, Ain Q, Hamdani MA, Butt MRA, Ashraf MA. Behcet's disease presenting with life threatening manifestation of cerebral venous thrombosis. J Ayub Med Coll Abbottabad 2020;32(1):124-6.

INTRODUCTION

Behcet's disease (BD) is an immune-mediated disorder characterized by repeated oral and genital ulcers with joints, eye brain and gastrointestinal involvement. Young adults of 20–40 years are usually affected.¹ Behcet's disease has a distinguishable geographic distribution, more prevailing in areas beside the ancient Silk Road. It is reported in Japan and Middle East countries more compared to northern Europe.²

Neurological manifestations of Behcet's disease are also called neuro-Behcet's disease (NBD). The prevalence of neurological manifestation amongst BD differs between 2–49%. Central nervous system (CNS) association of Behcet's disease may be grouped as parenchymal and nonparenchymal. The parenchymal involvement encompasses hemispheric, brainstem, spinal, and multifocal presentations. The nonparenchymal CNS involvement (also known as neurovascular BD) includes dural sinus thrombosis, arterial occlusion, and arterial aneurysms. Parenchymal to nonparenchymal involvement ratio is 4.3:1.³ We report a case of a 24 years old young male diagnosed as Behcet's disease complicated with cerebral venous thrombosis, a rare manifestation from our part of the world.

CASE REPORT

A twenty-four years old male presented to the clinic with a history of fever, headache for one month and vomiting for two weeks. He had deterioration of bilateral vision more marked in the left eye. He had history of repeated oral and genital ulcers for one year. He had difficulty in swallowing due to painful mouth ulcers. There was no history of sensitivity to light, hair loss, weight loss, and alcohol abuse. He was admitted with the diagnosis of Behcet's disease. On examination, there was oral thrush and multiple aphthous ulcers also involving tonsillar pillars. On skin multiple 2–3 mm lesions resembling papules and pustules were observed on back, and chest. Genital ulcers with scarring on left side of scrotum were also noticed. On eye examination he had right lateral rectus palsy and left sided vision loss up to 6/24. Fundoscopy revealed bilateral optic disc swelling with established disc oedema on right eye and developing oedema on left eye and macular stippling in left eye. There was no element of anterior or posterior uveitis. At cannulation site, erythematous papule was observed on forearm. Systematic examination was otherwise unremarkable.

Table-1: Laboratory investigations after admission

Haemoglobin (g/dl)	12.3	Chloride (mmol/L)	98
Mean Cell Volume (FL)	73.7	PT (sec)	12
White Blood Cell Count(x10E9/L)	9.76	PT Control (sec)	11
Neutrophil (%)	89	INR	1.0
Lymphocytes (%)	8	APTT (sec)	32
Eosinophils (%)	1	APTT Control (sec)	31
Monocytes (%)	2	Total Bilirubin (mg/dL)	0.4
		SGPT (IU/L)	64
Platelet Count (/uL)	372	SGOT (IU/L)	22
Blood Urea Nitrogen (mg/dl)	35	Albumin(g/dL)	3.6
Creatinine (mg/dl)	0.7	Erythrocytes Sedimentation Rate(mm/hr)	5
Sodium (mmol/L)	135	Urine Complete Examination	Normal
Potassium (mmol/L)	3.7		

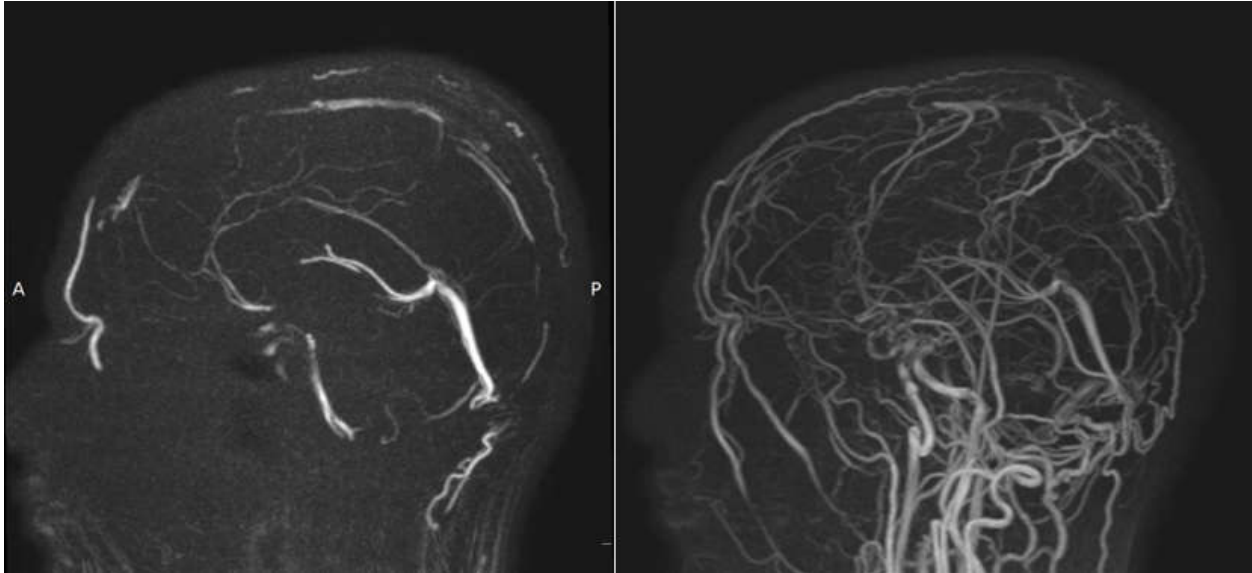


Figure-1: Magnetic resonance venography (MRV) showing superior sagittal and bilateral transverse sinuses thrombosis with only partial flow in sigmoid sinuses.

Laboratory investigations are mentioned in table-1. X-ray chest was unremarkable. Workup for syphilis was also done which was negative. In magnetic resonance imaging (MRI) (pre and post contrast) abnormal T2 W FLAIR hyper intense signals seen in posterior half of superior sagittal sinuses showing diffusion restriction on DWI. Magnetic resonance venography (MRV) reported venous sinus thrombosis involving superior sagittal and bilateral transverse sinuses with only partial flow in sigmoid sinuses. Magnetic resonance arteriography (MRA) images were unremarkable. Coagulation profile was also within normal range. He was managed with intravenous methylprednisolone pulse therapy (1gm/day) for 3 days. He was anti coagulated with low molecular weight heparin. Azathioprine and colchicine was also started. First cycle of Cyclophosphamide (10 mg/Kg) with MESNA (Mercaptoethanesulfonate) was given. On discharge he was started on tablet warfarin with INR monitoring (target 2–3) after neurological consultation.

On subsequent follow up his symptoms improved and skin lesions subsided and no new eruptions were observed. Ophthalmology consultation was sought and improvement in vision was noted.

DISCUSSION

Behçet's disease (BD) could be a rare multisystem disorder. The classic triad of oral and genital ulcerations in conjunction with uveitis was originally delineated by the Turkish specialist Hulusi Behçet in 1937, however involvement of the cardiovascular,

central nervous, pulmonic and gastrointestinal system were conjointly later known.⁴

The diagnosis is clinical as a result of there no specific evidence, pathognomonic symptoms or specific laboratory findings in line with the International Study cluster criteria in our case. The diagnosis of Behçet's disease also needs the presence of repeated oral ulceration together with any 2 conditions: repeated ulcers on genitalia, eye and lesions or a positive pathergy test.⁵ Our patient fulfilled the diagnostic criteria.⁶

Its neurological complications (neuro BD) are comparatively rare. The frequency of neurological manifestations varies, starting from fifth to thirtieth of patients. It will involve each the central and peripheral nervous system. Central nervous system (CNS) complications may be categorized into two main groups: 1) parenchymal involvement, which has brain-stem involvement, neural structure manifestations, spinal cord lesions, and meningoencephalitis presentations, and 2) Nonparenchymal involvement, inflicting dural sinus occlusion, blood vessel occlusion, or aneurysms furthermore. Peripheral neuropathy and myopathy are rare.⁷

Cerebral thrombosis (CVT) frequency in Behçet disease is difficult to determine from literature. Early recognition and treatment can have satisfactory outcomes as compared to arterial strokes. But unfortunately, CVT if unrecognized can lead to serious complications even death.⁸Diagnosis of CVT is ideally supported by imaging studies including Magnetic resonance imaging (MRI) and Magnetic resonance venography (MRV). The manifestations of

CVT chiefly involve sinuses (Superior sagittal, transverse, sigmoid and straight sinuses), inflicting intracranial, cardiovascular disease and continuous headache in majority of the patients. Different potential manifestations are papilledema, cranial nerve palsy, nausea and focal deficits. The onset of CVT in Behcet's disease is usually progressive rather than focal lesions and deficits as seen in other etiologies.⁹

Uptill now, there is no clear recommendation about immunosuppressive agents alone or combined with anticoagulation treatment in BD-associated CVT. Some authors disagree with anticoagulation treatment in Behcet's disease patients, because it can increase the chance of aneurysms rupture, whereas many practitioners in non-endemic countries still start anticoagulation therapy during this indication.¹⁰

In such conditions, corticosteroids is additionally recommended by European Stroke Organization.¹¹

Within the present case, we decide to begin with pulse therapy of corticosteroids together with immunosuppressive therapy colchicine and anticoagulation. Our patient responded well to the given treatment.

CONCLUSION

Behcet's disease (BD) should be thought of in medical diagnosis of patients with neurological symptoms, as cerebral thrombosis in patients with Behcet's disease might end in serious neurological outcomes. Early recognition and treatment might cut back complications. Till now, no definitive recommendation regarding anticoagulation for

Behcet's disease is offered. Additional studies ought to be performed concerning anticoagulation in Behcet's disease.

REFERENCES

1. Ishaq S, Saeed A, Jawad M. Regression of severe Behcet's eye disease with infliximab therapy; first two cases treated in Pakistan. *J Pak Med Assoc* 2012;62(11):1242–4.
2. Salvarani C, Pipitone N, Catanoso MG, Cimino L, Tumiatì B, Macchioni P, *et al.* Epidemiology and clinical course of Behçet's disease in the Reggio Emilia area of Northern Italy: A seventeen-year population-based study. *Arthritis Rheum* 2007;57(1):171–8.
3. Sharma C, Kumawat B, Rana KR, Saini T. Neuro-Behcet's disease: A report of three clinically distinct cases from North-west India. *Indian J Health Sci Biom Res* 2018;11(1):89.
4. Yeo M, Lee HL, Cha M, Kim JS, Han HS, Lee SH, *et al.* Neuro-Behcet disease presenting as a solitary cerebellar hemorrhagic lesion: a case report and review of the literature. *J Med Case Rep* 2016;10(1):360.
5. Sakane T, Takeno M, Suzuki N, Inaba G. Behçet's disease. *N Engl J Med* 1999;341(17):1284–91.
6. Mignogna MD, Fedele S, Lo Russo L. International diagnostic criteria and delay of diagnosis in Behcet's disease. *J Rheumatol* 2000;27(11):2725.
7. Saadoun D, Wechsler B, Resche-Rigon M, Trad S, Le Thi Huong D, Sbai A, *et al.* Cerebral venous thrombosis in Behçet's disease. *Arthritis Rheum* 2009;61(4):518–26.
8. Yazici H, Fresko I, Yurdakul S. Behçet's syndrome: disease manifestations, management, and advances in treatment. *Nat Clin Pract Rheumatol* 2007;3(3):148–55.
9. Bousser MG, Ferro JM. Cerebral venous thrombosis: an update. *Lancet Neurol* 2007;6(2):162–70.
10. Krumb E, Lefebvre C, Peeters A, Hermans C. Cerebral venous thrombosis revealing Behçet's disease in a Moroccan patient: A case report and literature review. *SAGE Open Med Case Rep* 2018;6:2050313X18767053.
11. Ferro JM, Bousser MG, Canhão P, Coutinho JM, Crassard I, Dentali F, *et al.* European Stroke Organization guideline for the diagnosis and treatment of cerebral venous thrombosis—endorsed by the European Academy of Neurology. *Eur Stroke J* 2017;2(3):195–221.

Submitted: November 29, 2018

Revised: --

Accepted: August 30, 2019

Address for Correspondence:

Ushna Naveed, FCPS post graduate trainee Internal Medicine, Shalamar Hospital, Lahore-Pakistan

Email: ushnanaveed04@gmail.com