

## CASE REPORT

## AXILLARY ARTERY INJURY IN BLUNT SHOULDER TRAUMA – AN UNCOMMON ASSOCIATION WITH PROXIMAL HUMERUS FRACTURE

Rashid Usman, Hammad Malik, Rana Dilawaiz Nadeem\*

Department of Surgery, CMH Lahore Medical College and CMH Hospital Lahore, \*Department of Orthopaedics Surgery, King Edward Medical University, Mayo Hospital, Lahore-Pakistan

Axillary artery injury along with proximal humerus fracture as a result of blunt trauma is a rare incidence. We present a 65-year-old male with a pulseless cold hand, who had blunt trauma 3 days ago, leading to fracture of proximal end of humerus along with axillary artery injury. Surgical intervention revealed contusion of axillary artery with intravascular thrombosis causing complete occlusion. Internal fixation of fracture along with excision of contused axillary artery was done followed by interposition venous graft. The diagnostic modalities and treatment options for such a case are discussed.

**Keywords:** Axillary artery; Trauma; Fracture humerus

**Citation:** Usman R, Malik H, Nadeem D. Axillary artery injury in blunt shoulder trauma – an uncommon association with proximal humerus fracture. J Ayub Med Coll Abbottabad 2019;31(4):631–3.

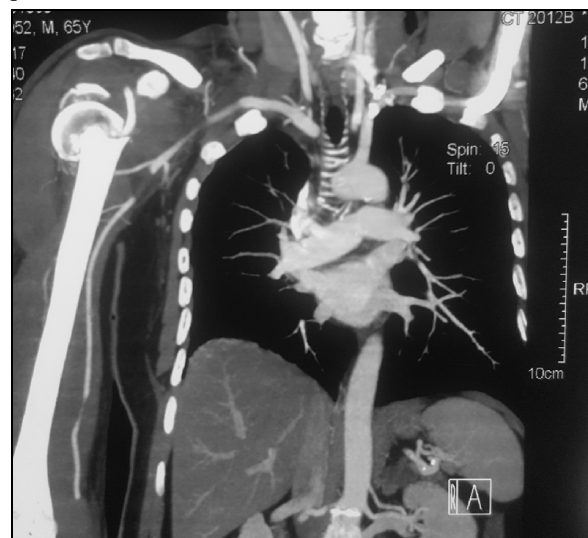## INTRODUCTION

Axillary artery injury following fracture of upper end of humerus is a rare event with few cases reported in literature.<sup>1,2</sup> There is abundance of loose connective tissue and ill developed compartments in axilla when compared to tight facial compartments and less loose tissue in distal arm. This distribution makes the axillary artery less vulnerable to injury even with associated skeletal injuries. When injured, the trauma pattern ranges from contusion with intravascular thrombosis to partial laceration to even complete transection.<sup>3</sup> Due to abundance collateral circulation around humerus, such an injury may not get immediately noticed because it may not present with typical fearful signs of acute limb ischemia and thus can easily get overlooked. If not treated properly it can lead to dreadful complications such as avascular necrosis of humeral head, loss of function of arm or even limb loss.<sup>4</sup> We present an interesting case of 3 days old axillary artery injury associated with fracture neck of humerus. The vascular injury went undetected due to warm hand. The presentation, diagnostic modalities and treatment of such an injury are discussed.

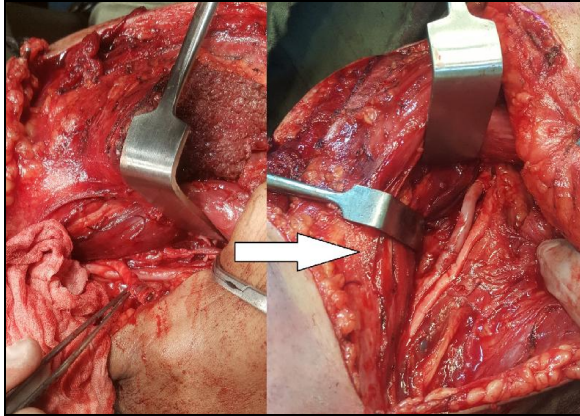
## CASE REPORT

A 65-year-old male was referred to clinic for vascular assessment of his fractured upper limb. He fell from motorbike 3 days ago and fractured his right proximal humerus. The duty doctor in Emergency Room noted fracture but the hand was warm with a palpable pulse. There was no neurological deficit. He was provided with hanging U-slab and referred to consultant orthopaedic surgeon for future follow ups. Two days after the initial insult, patient noted his hand is getting colder, painful and pale although he was able to move it. He had a Doppler Scan done of his right arm which showed absent flow in brachial artery from the fracture hematoma site onwards. His Computerized Tomographic Angiography (CTA) done on third day revealed a filling defect in third part of

axillary artery with distal filling of contrast via collaterals [Figure-1]. A joint decision was made by orthopaedic and vascular team to explore and treat both the fracture and vascular injury at the same time. Firstly, the orthopaedic team fixed the proximal humerus fracture with PHILOS™ Plating System. Following that, the axilla was approached through same incision. There was 3 cm contused segment with intravascular thrombosis and absent flow [Figure-2]. The axillary artery segment was resected and continuity was restored with an interposition reverse saphenous vein graft in end to end configuration [Figure-3]. Patient had distal pulses restored immediately after the anastomosis. Since there was no evidence of compartment syndrome fasciotomy was not done. His post-operative recovery was uneventful and he was discharged on 3rd postoperative day. Two weeks follow up showed satisfactory wound healing and palpable radial pulse with no neurovascular deficit.



**Figure-1:** CTA showing filling defect (complete occlusion) in axillary artery with distal filling of contrast through collaterals.



**Figure-2: Contusion of axillary artery with intravascular thrombosis (left) and restoration after excision and repair with venous interposition graft (right)**

## DISCUSSION

Proximal humerus fracture is common but concomitant axillary artery injury is not. Consideration should always be given to variations in anatomy of the underlying structures that can have an effect on presentation and management. Failure to differentiate a vascular injury from a simple skeletal injury may have grave consequences including neurological deficits, limb loss or even death.<sup>5</sup> Some factors that predispose an individual to axillary artery damage include but are not limited to advancing age, osteoporosis, atherosclerosis and poor diet.<sup>1</sup> Our patient was also 65 year old with underlying atherosclerotic risk factors such as cigarette smoking and hypertension.

Damage to axillary artery may not be noticeable upon initial examination due to presence of rich collateral circulation. Many a times the classical 'Six Ps' of acute limb ischemia are absent and patient may present with palpable distal pulses despite having an underlying vascular injury.<sup>6</sup> In this patient, fracture of the proximal humerus was diagnosed immediately following the trauma. However, the warm limb with palpable pulse at that time did not prompted further investigations and concomitant injury to axillary artery was overlooked.

Plain X-ray is helpful to locate the exact site of humeral fracture/dislocation. Such injury may cause contusion of the nearby axillary artery due to direct pressure or there may be partial laceration to complete transection of axillary artery due to piercing trauma by the fractured bony fragments. In suspected cases a Doppler ultrasound should be performed to assess circulation. For a more accurate diagnosis arteriogram should be

performed to localize site of injury.<sup>7</sup> A delay in diagnosis in the presence of a damaged axillary artery may increase the risk of hematoma formation, which can compress the nearby brachial plexus resulting in neurovascular compromise.<sup>8</sup>

Management should proceed in a systemic fashion: internal fixation should be performed following exposure to help prevent any form of displacement during repair of the damaged vessel, however if the vessel damage is far too great then it should be repaired first.<sup>1</sup> Available options include open repair in which an interposition venous or prosthetic graft can be used.<sup>9</sup>

Recently, endovascular repair using a stent graft is viable option in patients where such an injury is detected in early hours, especially in clinically stable patients with penetrating trauma.<sup>10</sup> Our patient presented 3 days after the initial insult and those golden hours of acute limb ischemia were already missed. Furthermore, we decided to fix the skeletal injury at the same time. Considering these, open repair was a preferred approach in this patient.

## CONCLUSION

Fracture of proximal end of humerus can result in concomitant injury to the axillary artery. Such injury may go unnoticed due to rich collateral circulation keeping the hand warm. High index of suspicion and early Doppler study is very helpful in diagnosing such injuries. To achieve best outcome, we recommend early repair and combined approach with skeletal and vascular fixation done at the same time.

## AUTHORS' CONTRIBUTION

RU: Study concept. HM: Data collection. HM, RU, RDN: Writing, proof reading, analysis. RU, RDN: Interpretation.

## REFERENCES

1. Yagubyan M, Panneton JM. Axillary Artery Injury from Humeral Neck Fracture: A Rare But Disabling Traumatic Event. *Vasc Endovascular Surg* 2004;38(2):175–84.
2. Mathe J, Depuydt P, Parmentier L, Olivie F, Harake R, Janssen A. Injury of the axillary artery after a proximal humeral fracture: a case report and overview of the literature. *Acta Chir Belg* 2008;108(5):625–7.
3. Hofman M, Grommes J, Krombach GA, Schmidt-Rohlfing B. Vascular injury accompanying displaced proximal humeral fractures: two cases and a review of the literature. *Emerg Med Int* 2011;742870.
4. Ng AJ-H, Arora V, Tang HH, Treseder T, Jain A, Wagner T. Axillary Artery Injury Associated with Proximal Humeral Fractures: Review of Long-Term Vascular, Orthopedic, and Neurologic Outcomes. *Ann Vasc Surg* 2016;33:210–9.
5. Donovan DL, Sharp WV. Blunt trauma to the axillary artery. *J Vasc Surg* 1984;1(5):681–3.
6. Hayes JM, Van Winkle GN. Axillary artery injury with minimally displaced fracture of the neck of the humerus. *J*

- Trauma 1983;23(5):431–3.
7. Manak P, Klein J. Axillary artery injury in closed fracture of the humeral neck. Acta Univ Palacki Olomuc Fac Med 1996;140:87–8.
  8. Allie B, Kilroy DA, Riding G, Summers C. Rupture of axillary artery and neuropraxis as complications of recurrent traumatic shoulder dislocation: case report. Eur J Emerg Med 2005;12(3):121–3.
  9. Ender Topal A, Nesimi Eren M. Management of axillo-subclavian arterial injuries and predictors of outcome. Minerva Chir 2011;66(4):307–15.
  10. Testerman GM, Gonzalez GD, Dale E. CT angiogram and endovascular stent graft for an axillary artery gunshot wound. South Med J 2008;101(8):831–3.

*Submitted: 18 April, 2019*

*Revised: --*

*Accepted: 13 August, 2019*

**Address for Correspondence:**

**Rashid Usman**, Assistant Professor, Department of Surgery, CMH Lahore Medical College and CMH Hospital Lahore-Pakistan

**Cell:** +92 333 488 5445

**Email:** drrashidusman@yahoo.com