

CASE REPORT**MUCOEPIDERMOID CARCINOMA – RARE PRESENTATION OF CHILDHOOD CHRONIC RESPIRATORY SYMPTOMS IN 10 YEARS OLD GIRL****Syed Sajid Hussain Shah, Bibi Aalia**

Department of Paediatrics, Ayub Medical College Abbottabad, KMU Institute of Medical Sciences, Kohat-Pakistan

Mucoepidermoid carcinoma is the rarest presentation in children arising from bronchial glands with low potential for malignancy as most of children have history of recurrent chest infections. We present the case of ten years old girl presenting with history of recurrent respiratory infections in past admitted for fever, cough and respiratory distress. HRCT showed soft tissue in lumen of trachea at level of carina extending into right main bronchus along with collapse of apical segment of right upper lobe and right middle and lower lobes collapse consolidation. Surgery was done and histopathology showed low grade mucoepidermoid carcinoma with clear histopathology of regional lymph nodes. Follow up of patient done for two years. Informed consent was taken from patient prior to writing of this case report.

Keywords: Cough; Recurrent chest infection; Carcinoma; Mucoepidermoid Carcinoma

Citation: Shah SSH, Aalia B. Mucoepidermoid carcinoma – Rare presentation of childhood chronic respiratory symptoms in 10 years old girl. J Ayub Med Coll Abbottabad 2020;32(2):274–6.

INTRODUCTION

In children mucoepidermoid carcinoma (MEC) is the rarest presentation, originating from the bronchial gland as so far 55 cases have been reported in the literature among children.¹ Though intra bronchial and intra parenchymal tumours are rare yet they do present in children but mostly overlooked due to nonspecific symptoms and presenting signs.² Mucoepidermoid carcinoma arise from bronchial glands with low potential for malignancy but characterized by intermediate type cells, squamous cells and mucin secreting cells.³ MEC accounts for 0.1–0.2% cases of primary lung cancers.⁴

We are reporting this case who presented with symptoms of respiratory tract disease with ultimate diagnosis of MEC.

CASE REPORT

A 10 years old female presented to private clinic with history of fever, cough and respiratory difficulty for last five days. It was sudden in onset. There is also history of such episodes in past for last four years. Four years back she got with onset of these sign and symptoms and for which she got treatment from local doctor. She got symptoms again and again and was also given anti tuberculous treatment by one of the senior pulmonologists.

On examination there was decrease air entry at right lower zone and dull on percussion. Patient was admitted to child ward with provisional diagnosis of chronic foreign body. Initial CXR showed consolidation at lower lung. HRCT done which showed soft tissue in lumen of trachea at level of carina extending into right main bronchus with

collapse of apical segment of right upper lobe and collapse consolidation of right middle and lower lobes.

Patient was referred to thoracic surgeon and surgical resection of right middle and lower lobe done. Histopathology showed low grade mucoepidermoid carcinoma with clear histopathology of regional lymph nodes. Patient was put on regular follow up. The post-operative course was excellent and no adjuvant treatment was required.

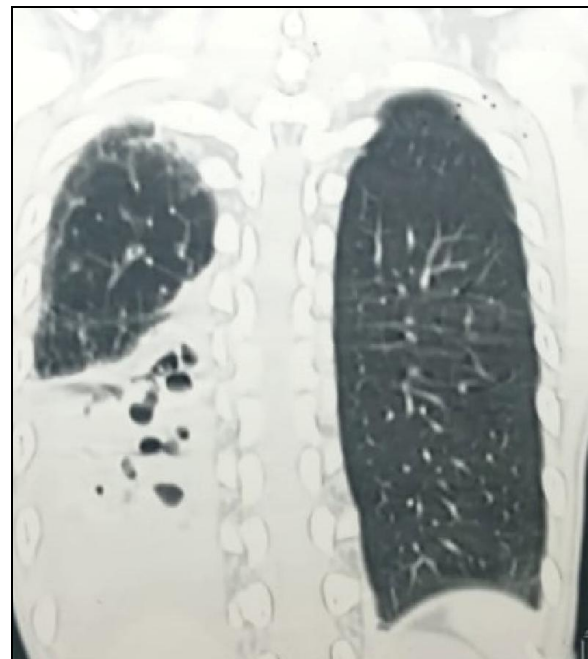


Figure-1: CT scan chest – preoperative

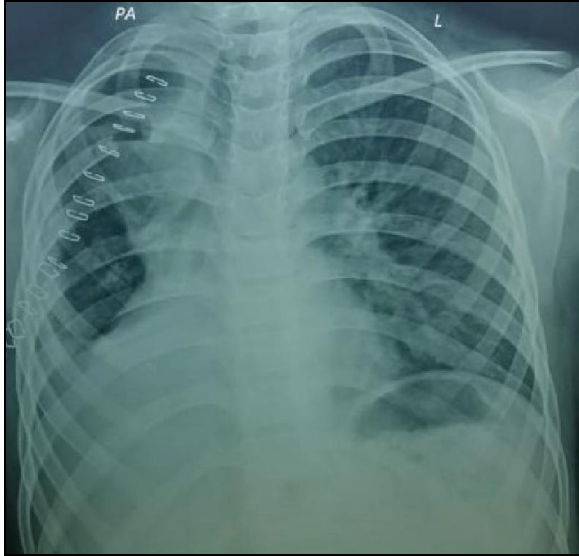


Figure-2: Post-operative Chest X- Ray

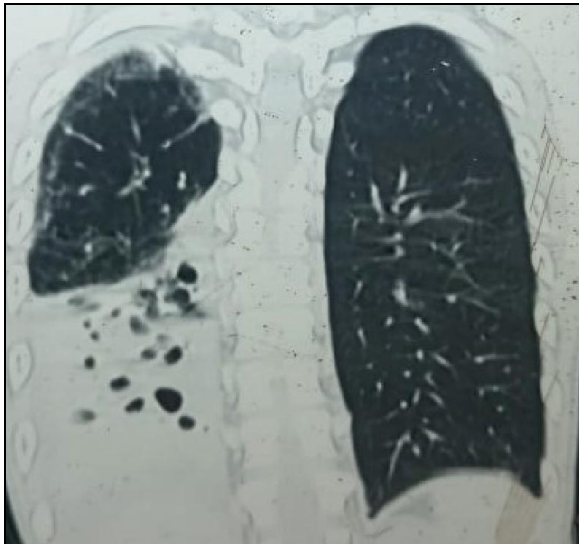


Figure-3: CT scan chest – pre operatively

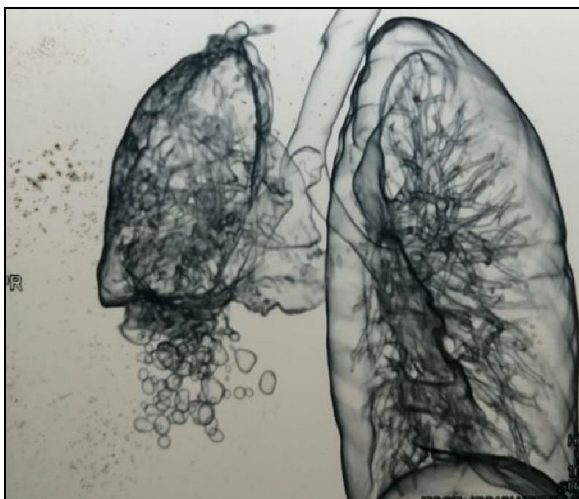

Figure-4: 3D CT scan chest - preoperative

DISCUSSION

In literature the most primary lung tumours are described for the adult patients but these tumours are also present in children as most of intra bronchial tumours in children are malignant.⁵

When children present with respiratory symptoms which are persistent then the differential diagnosis should include intra bronchial tumours as most of the time these are missed.⁴

Mucoepidermoid carcinoma is one of the rarest presentations in paediatric patients with more prevalence in females.⁶

It arises from submucosal bronchial glands in excretory ducts and mostly involves main and lobar bronchus.⁷ Mostly patients present with symptoms of partial or complete air way obstruction like cough, respiratory difficulty and wheeze. Radiological findings on chest X-ray include atelectasis or consolidation.¹ Treatment options in children include surgery provided no metastasis, otherwise radiotherapy.^{8,9}

In children the most common cause of airway obstruction is foreign body. Rarely respiratory tract papillomatosis can also present with airway obstruction symptoms. As primary lung tumours are rare so there is delay in ultimate diagnosis of these patients, like our patient who presented with respiratory symptoms for last 4 years before final diagnosis was made. These children who present with repeated chest symptoms are one of diagnostic challenge for the treating doctor as at initial stage of disease it is difficult to differentiate simple childhood asthma from other diseases. These patients presenting with chronic symptoms need proper history and examination. Afterwards need proper planned diagnostic workup starting from chest X-ray and complete blood count to high resolution computerized tomography (HRCT) and lung function tests. Bronchoscopy is rarely required in these patients and if done then may need tissue biopsy.

ACKNOWLEDGEMENT

Abstract of this case report has been submitted for Ayubian International Conference and Grand Reunion 2019 for poster.

REFERENCES

1. Khalilzadeh S, Boloursaz MR, Karimi S, Hassanzad M, Jand Y, Saghebi SR, *et al*. Mucoepidermoid Carcinoma (MEC): A Rare Cause of Chronic Cough in Children. *J Compr Pediatr* 2013;4(3):151-4.
2. Vageriya NL, Shah RS, Prabhu S, Naphade D, Athawale HR. Intra bronchial mucoepidermoid carcinoma in an 8 year old girl: A case report of rare tumor with review of literature. *J Pediatr Surg* 2016;13:41-4.
3. Shen C, Che G. Clinicopathological analysis of pulmonary mucoepidermoid carcinoma. *World J Surg Oncol* 2014;12:33.

4. Qian X, Sun Z, Pan W, Ye Q, Tang J, Cao Z. Childhood bronchial mucoepidermoid tumors: a case report and literature review. *Oncol Lett* 2013;6(5):1409–12.
5. Roby BB, Drehner D, Sidman JD. Pediatric tracheal and endobronchial tumors an institutional experience. *Arch Otolaryngol Head Neck Surg* 2011;137(9):925–9.
6. Seo IS, Warren J, Mirkin LD, Weisman SJ, Grosfeld JL. Mucoepidermoid carcinoma of the bronchus in a 4-year-old child. A high-grade variant with lymph node metastasis. *Cancer* 1984;53(7):1600–4.
7. Patel RG, Norman JR. Unilateral hyperlucency with left lower lobe mass in a patient with bronchial asthma. *Chest* 1995;107(2):569–70.
8. Jayaprakash K, Kishanprasad HL, Ismail M, Raju M, Dasgupta A. Mucoepidermoid Lung Carcinoma in Child. *Ann Med Health Sci Res* 2014;4(2):276–8.
9. Li X, Xing T, Cui F, He J. Complete thoracoscopic sleeve lobectomy for mucoepidermoid carcinoma in a 5-year-old boy. 2019;11(9):4028–30.

Submitted: December 10, 2019

Revised: February 23, 2020

Accepted: February 27, 2020

Address for Correspondence:

Syed Sajid Hussain Shah, Department of Paediatrics, Ayub Medical College, Abbottabad-Pakistan

Cell: +92

Email: syed_sajid20@yahoo.com