

ORIGINAL ARTICLE

RECONSTRUCTION OF SEGMENTAL MANDIBULAR LOSS WITH VASCULARIZED FREE FIBULA FLAPS

Shahid Hussain Naqvi, Shahid Hameed, Muhammad Rizwan Aslam, Rao Saood Ahmed, Abu ul Ala Nafees, Hafiz Khalid Pervaiz

Department of Plastic Surgery, Combined Military Hospital, Rawalpindi-Pakistan

Background: Various methods for mandibular reconstruction have been demonstrated in literature from autogenous bone graft to free flaps and more recently tissue engineered materials. We share our experience of mandibular reconstruction with free fibular flap and evaluate its efficiency as a viable option for mandibular reconstruction. **Methods:** It was a cross-sectional study, conducted at Plastic surgery department combined military hospital, Rawalpindi. Study was carried out over a period of two years from November 2016 to November 2018. The data of demography, mode of presentation, pattern of reconstruction and procedural complications of the patients who underwent free fibula flap for segmental mandibular loss, were collected and analysed. Patients with segmental loss of mandible ranging from 6 to 15 cm and those who could sustain surgery were included in the study, while the patients with metastatic malignancy and recurrent disease were excluded from the study. Each patient was called for first follow up after 2 weeks then subsequent follow up after 1 month. Descriptive statistics were done with the help of SPSS-20. **Results:** A total of 57 patients with segmental mandibular loss treated with free fibula flap, fulfilling inclusion and exclusion criteria were included in this study. Thirty-eight patients were male while 19 were female with mean age 56 ± 3 years. Cause of mandibular loss was malignancy in 52 (91.2%), trauma in 3 (5.2%), and ameloblastoma in 2 (3.5%) patients. Major complications like flap failure was seen in one (1.75%), bone exposure in 1 (1.75%) and recurrence was observed in 1 (1.75%) patient. Minor complications like hematoma, wound dehiscence and oro-cutaneous fistula were seen in 2, 1 and 3 patients respectively. **Conclusion:** Free fibular flap shows good functional results with a high degree of consistency, and acceptable complications rate, so it should be the first choice for mandibular reconstruction.

Keywords: Mandibular reconstruction; Free fibular flap; Osteo-Cutaneous Flap

Citation: Naqvi SH, Hameed S, Aslam MR, Ahmed RS, Nafees AA, Pervaiz HK. Reconstruction of segmental mandibular loss with vascularized free fibula flaps. J Ayub Med Coll Abbottabad 2020;32(3):390-95.

INTRODUCTION

Mandibular reconstruction is an intricate and taxing procedure posing unique challenges to the operating surgeon. It requires comprehensive evaluation, planning, precise osseo-synthesis, use of high-tech power tools and a lengthy procedure, mostly involving meticulous micro-vascular surgery. Mandible provides several important functions including; speech articulation, stable platform for mastication, provision of dentition for chewing and swallowing.¹ Structurally it defines the lower jaw contour and helps in facial expression. Segmental loss of mandible results in both aesthetic and functional outcomes. These defects can result from benign or malignant tumour resection, post-traumatic, post-radiotherapy, bony infection and drug induced.

The goal of mandibular reconstruction is to return the patient to its previous functional status.² This includes restoration of both morphological and cosmetic functions. Optimal

functional restoration involves mastication, deglutition, management of oral secretion, provision of intraoral and extra oral lining, adequate mouth opening, provision of sensation and functional lower lip. Attaining the continuity of missing bone defect, lower face contour and provision of foundation for dental restoration comes in morphological functions. Therefore, good surgical reconstruction is of critical importance.

Various techniques have been used ranging from autogenous bone grafts³, pedicled and vascularized osseous free flaps⁴, Osteogenic distraction⁵, alloplastic material⁶ and more recently tissue engineered grafts⁷. Non-vascularized bone grafts have limited use; in smaller defects, where radiotherapy is not recommended, those who will not tolerate major surgery and where healthy vascularized soft tissue is available all around. Grafts from calvarium, rib, iliac crest, tibia, fibula and radius have been used. Presently autogenous vascularized free tissue transfer is considered the

modality of choice in mandibular reconstruction.² It gives good long-term aesthetic and functional results. Many flaps are documented with successful outcomes including fibular flap, scapular flap, iliac crest and radial free forearm flap. In cases where free flap reconstructions are contraindicated, the use of regional pedicle flap combined with autologous bone grafts still represents a valid choice. Patients who are not considered suitable for long and challenging surgery can still be treated using alloplastic materials in association with regional pedicle flap or, when adjuvant radiation therapy is needed, by simple loco-regional pedicle flap. Finally, in selected cases, the bone transporting technique should be considered as a valid alternative to the more "traditional" reconstructive methods because of the extraordinary potential and its favourable cost-benefit ratio.

We share here our experience of reconstruction of mandibular defects. The predominant cause of bone loss was due to benign and malignant tumours, few were post traumatic. Reconstruction was done by standard method of vascularized free fibular flap. The benefit of vascularized free fibula was provision of Osseo integrated implants.

Rationale of study is to reinforce this technique as gold standard for mandibular reconstruction.

MATERIAL AND METHODS

This Cross-Sectional study was conducted in department of Plastic Surgery Combined Military Hospital Rawalpindi, Pakistan from November 2016 to November 2018. Hospital ethical committee approval was obtained. A total of 57 mandibular defects were reconstructed with vascularized free fibula during the study period of 2 years.

Inclusion criteria were segmental loss of mandible ranging from 6 cm to 15 cm and patients who could sustain surgery. The patients with metastatic malignancy and recurrent disease were excluded from the study. Non-probability, consecutive sampling technique was adopted. All patients planned for reconstruction underwent detailed history, examination and workup including; baseline investigation, incisional biopsy for diagnosis, evaluation of cardiac and respiratory status, staging and screening CT scan head and neck, chest and ultrasound abdomen. All oncological patients were discussed in multidisciplinary meetings including plastic surgeons, ENT specialist, radiologist, pathologist and oncologist.

All patients were reassessed on OT table (Figure-1), planned for extent of resection, flap

markings and pattern of osteotomies. Patients were placed in supine position and general anaesthesia was given. Tracheostomy was done in all cases by ENT team followed by wide local excision of the tumour and supra-omohyoid /radical neck dissection depending upon the stage of disease. Simultaneously, the flap was planned and marked (Figure-2). Incision was made over the marking, the perforator in lateral inter-muscular septum was identified and preserved for skin paddle. Peroneus longus and brevis were detached from fibula, leaving the periosteum intact (Figure-3). About 0.5 to 1 cm of soleus muscle was taken for perforator safety posteriorly. Distal and proximal osteotomies were done to mobilize the fibula and held with bone clamps for traction. Pedicle was identified distally, ligasure clamps were applied and cut in continuity. The flap was harvested over the peroneal vessels, osteotomies, if required, were done before pedicle division and left in situ till the resection was completed (Figure-4). 5000 IU of heparin was infused one minute before pedicle division with micro-scissors. The flap was anastomosed in neck with one artery and two veins after dissection of recipient vessels.

The neo-mandible fixation was done with miniplates and screws (Figure-5). Flap in-setting was done while maintaining internal oral lining with either buccal mucosa or skin paddle and outer skin coverage. The neck wound was closed in layers after placing redovac drain with vicryl 3/0 and prolene 5/0 respectively (Figure-6). Donor site was closed over redovac drain, after ensuring haemostasis. Split thickness skin grafting was done, if donor site was unable to close and POP back slab applied. Post operatively the patients were managed in ICU with injection clexane 60 mg in divided doses daily. Flap monitoring was done every 2 hours in first 24 hours followed by 4 hours monitoring in next 48 hours. Nasogastric feeding was done for first 5 days followed by oral diet. Drains were removed when discharge was less than 10 ml/day. Patients who underwent smooth recovery were discharged on 14th post-operative day.

After the discharge from the hospital the patients were called for first follow up in OPD after 2 weeks and subsequent follow up after one month. Post-operatively oncological patients received radiotherapy. All the information was collected through a specially designed *Pro forma*.

All the data was entered and analysed through SPSS-20. The qualitative variable like gender, mode of presentation, pattern of reconstruction and complications were presented as frequency and percentage.

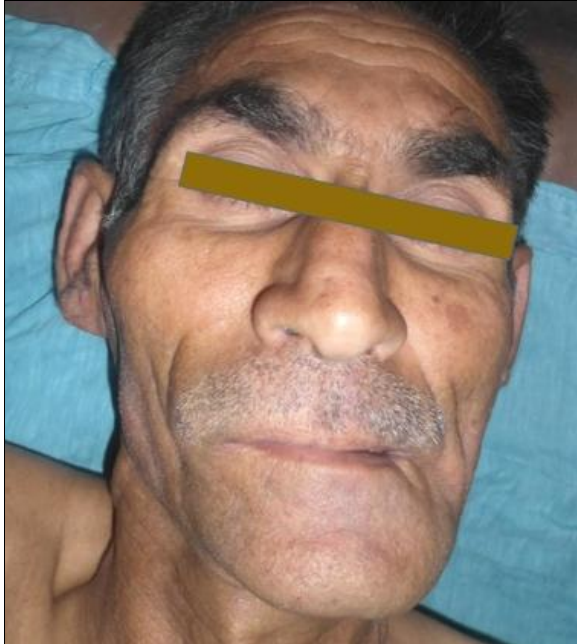

Figure-1: Pre-operative

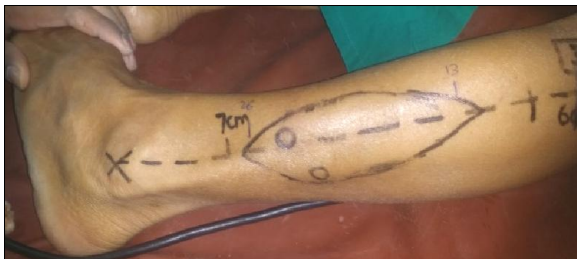

Figure-2: Markings of flap

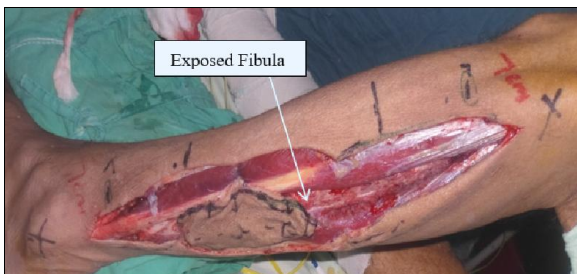

Figure-3: Mobilization of fibular flap

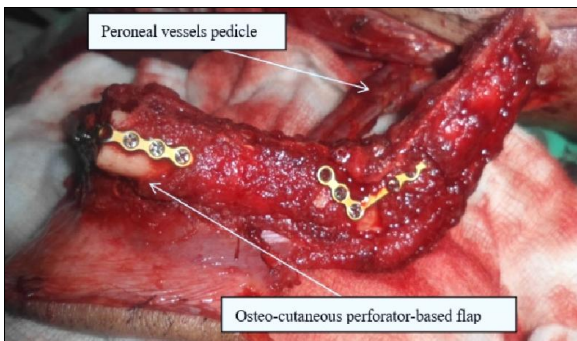


Figure-4: Osteotomies for neo-mandible

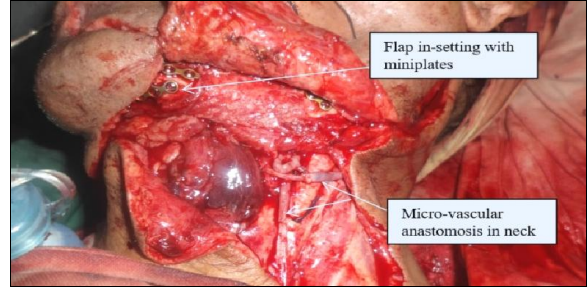


Figure-5: In-setting of neo-mandible with micro-vascular anastomosis

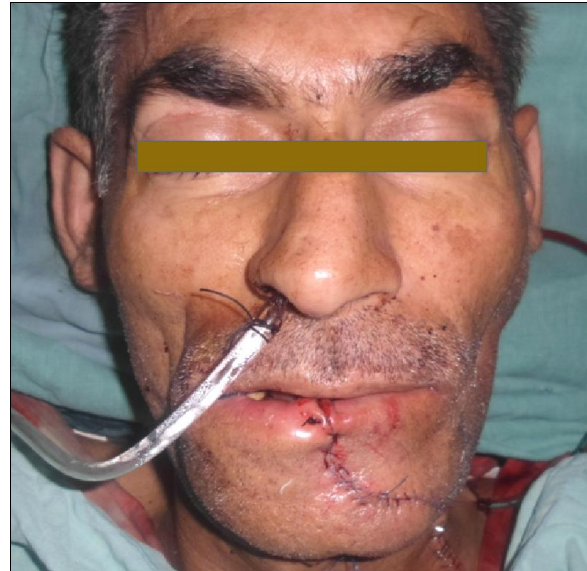

Figure-6: Final closure of wound

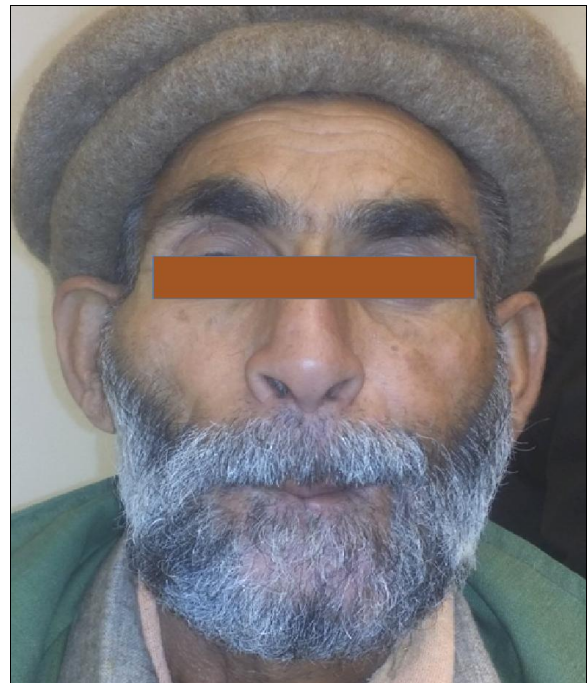

Figure-7: Follow-up at 3 months

RESULTS

Out of 57 cases, 38 (66.6%) were male and 19 (33.4%) were females. Mean age was 56 years with range between 28–70 years. Average operative time inclusive of resection and reconstruction ranged between 8–11 hours as shown in table-1.

Out of total 57 cases, 52 (91.2%) cases were of head & neck malignant tumours, 3 (5.2%) were post traumatic defects, all due to high velocity bullet injuries, 2 (3.5%) cases were of ameloblastoma of the mandible as shown in Figure-1.

Table 1: Demographic statistics

Number of patients	Gender		Mean Age	Average op time
	Male	Female		
57	38 (66.6%)	19 (33.4%)	56±3 Years	8–11 hours

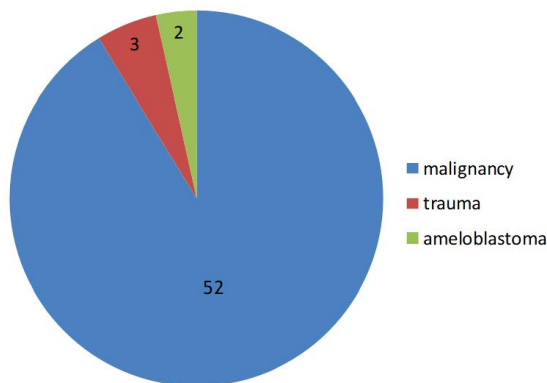


Figure-1: Pattern of segmental loss

Reconstruction was done with Vascularized free fibula in 57 cases. Thirty-one (58%) of 57 free fibula required 2 osteotomies, whereas 26 (42%) needed single osteotomy. 48 (75%) of 57 fibular flaps were osteo-cutaneous with a skin paddle ranging in size from 6×6 cm to 9×15 cm, whereas 9 cases (25%) were only osseous as shown in Figure-2.

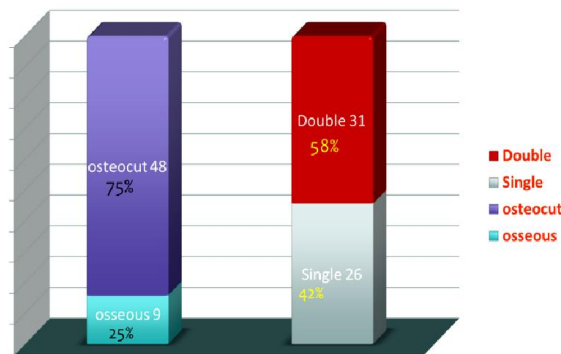


Figure-2: Pattern of Reconstruction

Flap failure was observed in 1 (1.75%) patient, which was detected within first 12 hours after the surgery. Patient was immediately explored. Cause of the failure was vessel wall atherosclerosis. Successful re-anastomosis was fashioned. Recurrence was observed in 1 (1.75%) patient, on first month follow up. It was due to aggressive Squamous cell carcinoma confirmed on histopathology as well. Bone exposure was seen in one 1 (1.75%) patient. it was initially oro-cutaneous fistula which subsequently ended up in bone exposure. Minor complications are shown in Figure-3. There was no major donor site morbidity recorded during hospital stay or in follow up. Overall, the patients were satisfied with the function and aesthetics of the Flap.

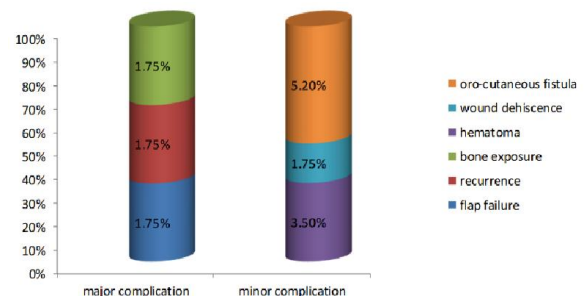


Figure-3: Complications of Surgery

DISCUSSION

Reconstruction of mandibular defect after resection or loss is of major significance as it involves loss of both form and functions. Anatomical, functional and aesthetic functions should be kept in mind while planning for mandibular reconstruction. Facial contours and jaw lines must be maintained. Normal speech, deglutition and movements of the jaw and upper aero-digestive functions have to be ensured. Aesthetic units should be maintained with minimal donor site morbidity. There are many reconstructive options available, from alloplastic bone substitutes to the autogenous bone grafts; the best suited reconstruction option for a particular patient varies depending on patient functional status. In addition to above aspects the ideal reconstruction should be safe, reliable, predictable, single stage procedure with minimal morbidity and no mortality.

Vascularized free fibular flap is widely used in reconstructive maxilla-mandibular surgery because of its advantages compared to others such as length and shape of the bone, good blood supply and low donor site morbidity.^{8,9} Free fibula as an effective reconstructive option for mandible was first described by Hidalgo in 1989.¹⁰ The major

advantage is that it provides a long segment of bone, up to 25 cm in length that can tolerate multiple osteotomies without compromising its blood supply.¹¹ Fibula receives segmental and intra-osseous branches from peroneal (90–95%), post-tibial and tibio-peroneal trunk necessitating provision of skin paddles. Another major advantage of the fibula flap is the ability to use a two-team approach, where the resecting and reconstructive teams are able to work simultaneously, as the fibula is far from the head and neck. Re-innervation of free fibula flaps is possible, using the lateral cutaneous sural nerve as the target for Neurotization.

Literature search for the local studies published from other centres of Pakistan revealed the work of Hyder A *et al*, who published their data of Plastic & Reconstructive Surgery departments of Dow university of Health sciences & Dr Ruth K. M. Pfau Civil Hospital, Karachi. In their total of 15 patients, only 2 had completed while other 2 had partial flap failure. Similar to our study, they also observed 1 wound dehiscence and 1 oro-cutaneous fistula. There was very low donor site morbidity. They concluded in the favour of free fibula flap technique in terms of function, cosmesis and lesser donor site post op complications.¹²

Micha peled *et al* published their series of 13 cases of mandibular reconstruction using free fibula vascularised flaps. Their two flaps were lost while wound dehiscence of donor site was encountered in four cases. In our study, only one flap was failed out of 57 cases, while minor complications of wound dehiscence were observed in only one case.¹³

Guerra MF *et al* published their work of mandibular reconstruction with vascularized free fibula flap. They presented data of 26 cases. Their success and complication rates are almost similar to our study data. There was flap failure in one case and minor complication like partial skin island necrosis in one case. There was no post-operative functional complication in the leg as well.¹⁴

Colletti G *et al* published their experience of 99 cases of free fibula flap for mandibular reconstruction. Like our study, their data also reflects high success rate of this technique. 90% of their flaps were totally successful while 7 flaps were completely failed, while skin paddle necrosis was seen in 3 cases. In our study we had only one flap failure in 57 cases. So, our flap success rate is also more than 90%.¹⁵

Pellini R *et al* presented their data of 41 patients of fibula free flap. Four cases were picked in post-operative period having venous impairment

in the flap requiring re-intervention, while three flaps were completely failed. Rest of the study population had successful recovery similar to our study cohort.¹⁶

In another study published by Bhujju KG *et al*, they reviewed 63 cases of fibular flaps. They had 100% success rate in terms of flap survival almost similar to our study. Moreover, they did not observe any long-term disability over donor site. They concluded this technique to be highly consistent in terms of functional and aesthetic terms.¹⁷

CONCLUSION

Free fibular flap shows good functional results with a high degree of consistency, and acceptable complications rate, so it should be the first choice for mandibular reconstruction.

AUTHORS' CONTRIBUTION

SHN: Conception of main theme, study design and write-up. SH: Overall supervision, analysis and interpretation of data. MRA: Critical revision of important intellectual content. RSA: Data analysis and graphic representation. AAN: Data collection. HKP: Proof reading.

REFERENCES

1. Kubein-Meesenburg D, Nägerl H, Schwestka-Polly R, Thieme KM, Fanghänel J, Mische B. Functional conditions of the mandible: theory and physiology. *Ann Anat* 1999;181(1):27–32.
2. Kokosis G, Schmitz R, Powers DB, Erdmann D. Mandibular reconstruction using the free vascularized fibula graft: an overview of different modifications. *Arch Plast Surg* 2016;43(1):3–9.
3. Ahmed W, Asim MA, Ehsan A, Abbas Q. Non-vascularized autogenous bone grafts for reconstruction of maxillofacial osseous defects. *J Coll Phys Surg Pak* 2018;28(1):17–21.
4. Chen YC, Valerio IL, Chien CY, Jeng SF. Pedicled mandible myo-osseous flaps combined with free skin flaps for reconstruction of complex lateral mandibular defects. *Head Neck* 2012;34(3):384–92.
5. Pingarrón-Martín L, Otero TG, Gallo LA. Experience with mandibular reconstruction using transport-disc-distraction osteogenesis. *Craniofacial Trauma Reconstr* 2015;8(2):117–22.
6. Rachmiel A, Shilo D, Blanc O, Emodi O. Reconstruction of complex mandibular defects using integrated dental custom-made titanium implants. *Br J Oral Maxillofac Surg* 2017;55(4):425–7.
7. Chanchareonsook N, Junker R, Jongpaiboonkit L, Jansen JA. Tissue-engineered mandibular bone reconstruction for continuity defects: a systematic approach to the literature. *Tissue Eng Part B Rev* 2013;20(2):147–62.
8. Disa JJ, Winters RM, Hidalgo DA. Long-term evaluation of bone mass in free fibula flap mandible reconstruction. *Am J Surg* 1997;174:503–6.
9. Goodacre TE, Walker CJ, Jawad AS, Jackson AM, Brough MD. Donor site morbidity following osteocutaneous free fibula transfer. *Br J Plast Surg* 1990;43(4):410–2.

10. Hidalgo DA. Fibula free flap: a new method of mandible reconstruction. *Plast Reconstr Surg* 1989;84(1):71–9.
11. Wei FC, Seah CS, Tsai YC, Liu SJ, Tsai MS. Fibula osteoseptocutaneous flap for reconstruction of composite mandibular defects. *Plast Reconstr Surg* 1994;93:294–304.
12. Hyder A, Sufyan A, Noor ul W, Huzaifa S ul K, Muhammad AG. The Osteomyocutaneous Free Fibula Flap in Mandibular Reconstruction. *Interv Pediatr Dent Open Access J* 2018;1(4):81431075.
13. Peled M, El-Naaj IA, Lipin Y, Ardekian L. The use of free fibular flap for functional mandibular reconstruction. *J Oral Maxillofac Surg* 2005;63(2):220–4.
14. Guerra MFM, Gías LN, Campo FJR, González FJD. Vascularized free fibular flap for mandibular reconstruction: a report of 26 cases. *J Oral Maxillofac Surg* 2001;59(2):140–4.
15. Colletti G, Autelitano L, Rabbiosi D, Biglioli F, Chiapasco M, Mandalà M, *et al.* Technical refinements in mandibular reconstruction with free fibula flaps: outcome-oriented retrospective review of 99 cases. *Acta Otorhinolaryngol Ital* 2014;34(5):342–8.
16. Pellini R, Mercante G, Spriano G. Step-by-step mandibular reconstruction with free fibula flap modelling. *Acta Otorhinolaryngol Ital* 2012;32(6):405–9.
17. Bhujra KG, Xing S, Liu H. Evaluation of mandibular reconstruction with free vascularized fibular flap. *J Nanj Med Univ* 2008;22(1):23–7.

Submitted: December 29, 2019

Revised: February 2, 2020

Accepted: February 23, 2020

Address for Correspondence:

Dr. Shahid Hussain Naqvi, Department of Plastic Surgery, Combined Military Hospital, Quetta-Pakistan

Cell: +92 333 818 1015

Email: shahidhnaqvi@gmail.com