

CASE REPORT

TREATMENT OF VERTICAL FRACTURE OF DISTAL RADIUS USING INTERFRAGMENTARY SCREWS THROUGH DIRECT LATERAL APPROACH TO DISTAL RADIUS

Shah Jehan, Jawad Ahmad

Trauma & Orthopaedic Department, Hull University Teaching Hospital NHS Trust-United Kingdom

Background: Distal radius fractures are very common injuries. Majority of these fractures are transverse or oblique in nature. Isolated vertical fractures of the distal radius in the sagittal plane are rare injuries. The management of these vertical fractures is therefore different from the usual transverse or oblique fractures of the distal radius. We report on a 53-year-old right-handed gentleman who fell from his bicycle and sustained a vertical fracture of the distal radius. His distal radius fracture was fixed surgically using two interfragmentary screws. A direct lateral approach of the distal radius was used to expose the distal radius. The rationale for using direct lateral approach and interfragmentary screws for this type of fracture is discussed.

Keywords: Distal radius; Vertical; Fracture; Treatment; Direct lateral approach

Citation: Jehan S, Ahmad J. Treatment of vertical fracture of distal radius using interfragmentary screws through direct lateral approach to distal radius. J Ayub Med Coll Abbottabad 2021;33(3):535-7.

INTRODUCTION

Distal radius fractures are among the most common fractures seen by the orthopaedic team. They typically occur in the elderly females attributed to postmenopausal osteoporosis. There are multiple classification systems for distal radius fractures. The two most commonly used classification systems are Frykman and Fernandez classifications.^{1,2} The Frykman classification describes the fracture based on the involvement of distal radioulnar joint and ulnar styloid fractures.¹ The Fernandez classification is more useful as it describes the mechanism of the fracture and recommends some guidance on treatment.²

Although the literature describes intraarticular fractures of distal radius in various planes, a vertical fracture in the sagittal plane extending along the shaft of the radius has not been described in any classification. The fracture line splits the distal radius into medial and lateral fragments. The medial half consists of lunate fossa and lateral half consists of scaphoid fossa.

The vertical fracture is an intraarticular fracture and the fracture line is parallel to the force from wrist along the shaft of the radius. There is a risk of further displacement with either of widening of the fracture gap or depression of the lunate fossa fragment or even worse both widening and depression. Therefore, it is thought that the better option is to stabilise these fractures to prevent future development of osteoarthritis.

CASE REPORT

We report on a 53-year-old gentleman who fell from his bike and landed onto his right hand. He presented to the emergency department with pain and swelling of his

right wrist. Initial examination showed tenderness over distal radius with normal neurovascular examination.

Anteroposterior (AP) and lateral radiographs of the distal radius were obtained which showed fracture of the distal radius in sagittal plane (Figure-1). The fracture was extending distally between the lunate and scaphoid fossa. Proximally, the fracture extended as far as the distal 1/3rd of shaft of radius and exited along the medial cortex of radial shaft. The lateral x-ray did not show any anterior or posterior extension of the fracture indicating that the fracture was only in the sagittal plane.

Initially a bellow elbows a back slab was applied and the radiographs in the back slab did not show any improvement in the factual position. A decision was made for internal fixation of the fracture. The patient was taken to theatre the next day. Under general anaesthesia and tourniquet control the distal radius was approached using a direct lateral approach. The superficial radial nerve was identified and retracted posteriorly. The tendons of abductor pollicis longus and extensor pollicis brevis were also retracted posteriorly. A longitudinal split was made in the distal brachioradialis tendon exposing the lateral surface of the distal radius. A 1.6-millimetre Kirschner (K) wire was initially passed parallel to the articular surface to hold the position of the fracture and prevent displacement during insertion of screws. Then two, 3.5-millimetre cannulated screws were used perpendicular to the fracture line and parallel to the articular surface (Figure-2). It was made sure that the heads of these screws were buried in the cortex and not prominent beneath the brachioradialis tendon. A below elbow backslap was applied for two weeks.

The patient was allowed to gently mobilise his wrist at 2 weeks. It was noted at 2 weeks that he had altered sensation over the first dorsal webspace.

When seen at six weeks, the paraesthesia over the superficial radial nerve area had completely resolved. The fracture showed complete healing at that stage.

Patient was followed at one year and then at two years with wrist X-rays (Figure 5 and 6), at that point he was discharged from the fracture clinic. Apart from the initial paraesthesia of superficial radial nerve, no other complication was noted.

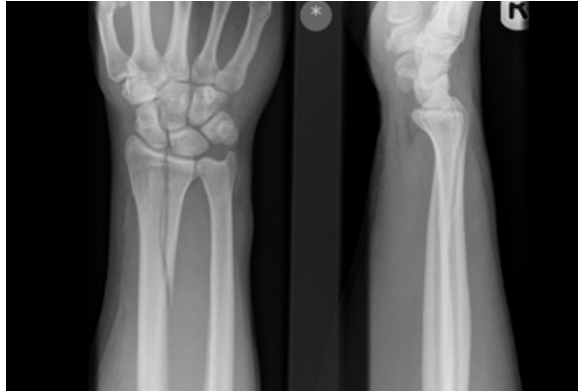

Figure-1: AP and lateral radiographs, showing vertical fracture of distal radius

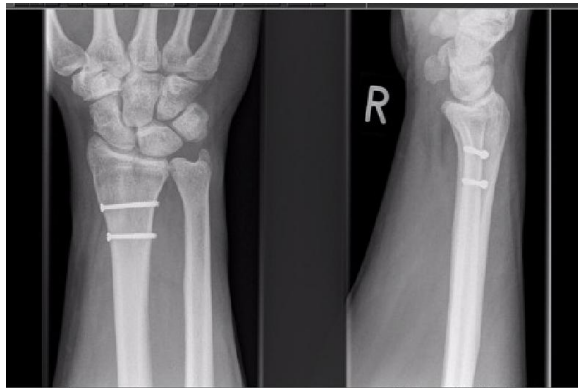

Figure-2: Intraoperative images showing fixation with two partially threaded 3.5 screws. The fracture was initially stabilized with 1.6 mm K-wire to prevent displacement during insertion of screws

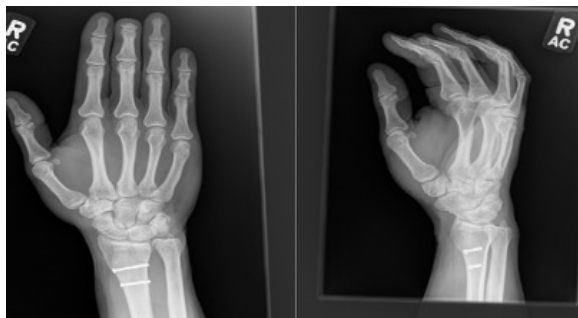


Figure-3: AP and lateral radiographs at 1-year time shows healing of fracture

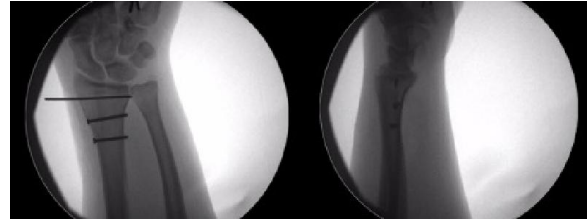


Figure-4: AP and oblique radiographs at 2 year follow up. No arthritic changes seen in wrist joint

DISCUSSION

Most of the distal radius fractures can be treated non-operatively. A recent study showed that in the extraarticular fractures, needing surgical intervention, there was no clinical difference at two years between the plate fixation and manipulation and K-wire fixation.³ However, in fracture types where the fracture line splits the distal radius in sagittal plane as in this case, the plate fixation may not achieve the desired goal. In this case, to achieve the goal of adequate reduction and then holding that reduction till healing could be achieved by interfragmentary screws.

For the insertion of screws in frontal plane, perpendicular to the fracture line, approach to lateral surface of the radius is required. Although approach to the lateral surface is possible through volar incision, it however requires significant soft tissue dissection. A logical option would be direct lateral approach to the distal radius. Through this approach insertion of screws perpendicular to the fracture line is much easier. The lateral approach is not commonly used approach. The incision is made over the midaxial part of distal radius just proximal to the tip of radial styloid. The most important structure in the superficial dissection is the superficial radial nerve. The nerve may be as single branch, but two main branches have been described as well.^{4,5} The nerve needs to be bluntly dissected and retracted either dorsally or volarly. Even if the nerve is identified and dissected away, there is a risk of neurapraxia. In our case the neurapraxia of superficial radial nerve was noted at two weeks. It completely resolved at 6 weeks.

The other structures at risk are extensor pollicis brevis and abductor pollicis longus tendons. These tendons can be mobilised dorsally after releasing the first dorsal compartment. Deeper still is the tendon of brachioradialis inserting to radial styloid. In our case we split the tendon longitudinally to insert the cannulated screws. If the heads of screws are not prominent and buried into the cortex, then risk of tendon irritation is minimum. However, if fixation with plate is needed, then tendon of brachioradialis may need to be detached and repaired again.⁶ Another important point to consider is extent of displacement.

If the vertical fracture is significantly displaced, then direct reduction of fracture may not be easy through the direct lateral approach.

CONCLUSION

In conclusion, the vertical fracture of the distal radius extending along the shaft is uncommon injury. Surgical stabilisation is required to prevent displacement and step formation in the articular surface. We used a simple method of interfragmentary screws through direct lateral approach which resulted in satisfactory outcome.

REFERENCES

1. Frykman GK. Fracture of the distal radius including sequelaed shoulder hand finger syndrome. Disturbance in the distal radioulnar joint and impairment of nerve function. A

- clinical and experimental study. *Acta Orthop Scand* 1967;108:1-155.
2. Fernandez DL. Fractures of the distal radius. Operative treatment. *Instr Course Lect* 1993;42:73-88.
3. Costa ML, Achten J, Parsons NR, Rangan A, Griffin D, Tubeuf S, *et al*. Percutaneous fixation with Kirschner wires versus volar locking plate fixation in adults with dorsally displaced fracture of distal radius: randomised controlled trial. *BMJ* 2014;349:g4807.
4. Samarakoon LB, Lakmal KC, Thillainathan S, Bataduwaarachchi VR, Anthony DJ, Jayasekara RW. Anatomical relations of the superficial sensory branches of the radial nerve: a cadaveric study with clinical implications. *Patient Saf Surg* 2011;5(1):28.
5. Robson AJ, See MS, Ellis H. Applied anatomy of the superficial branch of the radial nerve. *Clin Anat* 2008;21(1):38-45.
6. Pirela-Cruz MA, Scher DL. Exposure of distal radius fractures using a direct radial approach with mobilization of the superficial branch of the radial nerve. *Tech Hand Up Extrem Surg* 2010;14(4):218-21.

Submitted: July 16, 2020

Revised: --

Accepted: December 13, 2020

Address for Correspondence:

Jawad Ahmad, Trauma & Orthopaedic Department, Hull University Trust Teaching Hospital NHS Trust-United Kingdom

Email: doc_jawad101@hotmail.com