

CASE REPORT

BEST VITELLIFORM MACULAR DYSTROPHY IN AFGHAN TWINS

Ayisha Kausar, Nadia Akhtar*

Department of Ophthalmology, Shifa International Hospital, Islamabad, *Shifa College of Medicine, Shifa Tameere Millat University, Islamabad-Pakistan

Best vitelliform macular dystrophy is the second most common type of hereditary fundus dystrophies. Our case report describes twin brothers of Afghan family who developed Best vitelliform macular dystrophy. One of them developed choroidal neovascularization in one eye which was treated with single intravitreal injection of bevacizumab. The patient showed stable vision and did not have any recurrence until 3 years of follow up. Many cases of familial Best vitelliform macular dystrophy have been described in medical literature but our report is unique as it presents twin brothers with Best vitelliform macular dystrophy which has never been described before.

Keywords: Best vitelliform macular dystrophy, choroidal neovascularization, optical coherence tomography

J Ayub Med Coll Abbottabad 2016;28(2):404-6

INTRODUCTION

Best vitelliform macular dystrophy (BVMD) is one of the most frequent forms of autosomal dominant macular dystrophy¹, associated with mutations in the bestrophin 1 gene (*BEST1*). Retinal pigment epithelium (RPE) dysfunction leads to deposition of lipofuscin, between the outer retina and the RPE, thus forming the typical subretinal vitelliform “egg-yolk” lesions.

The diagnosis is based on family history, clinical and electrophysiological findings.² Optical

coherence tomography (OCT) is also used in certain cases to confirm the diagnosis.³

Majority of patients have bilateral typical macular lesions, but in rare cases it can be unilateral. BVMD causes a slowly progressive mild to moderate central visual impairment. Choroidal neovascular membrane (CNVM) secondary to BVMD is rare but it is the most significant potential complication which can cause rapid, significant visual loss.

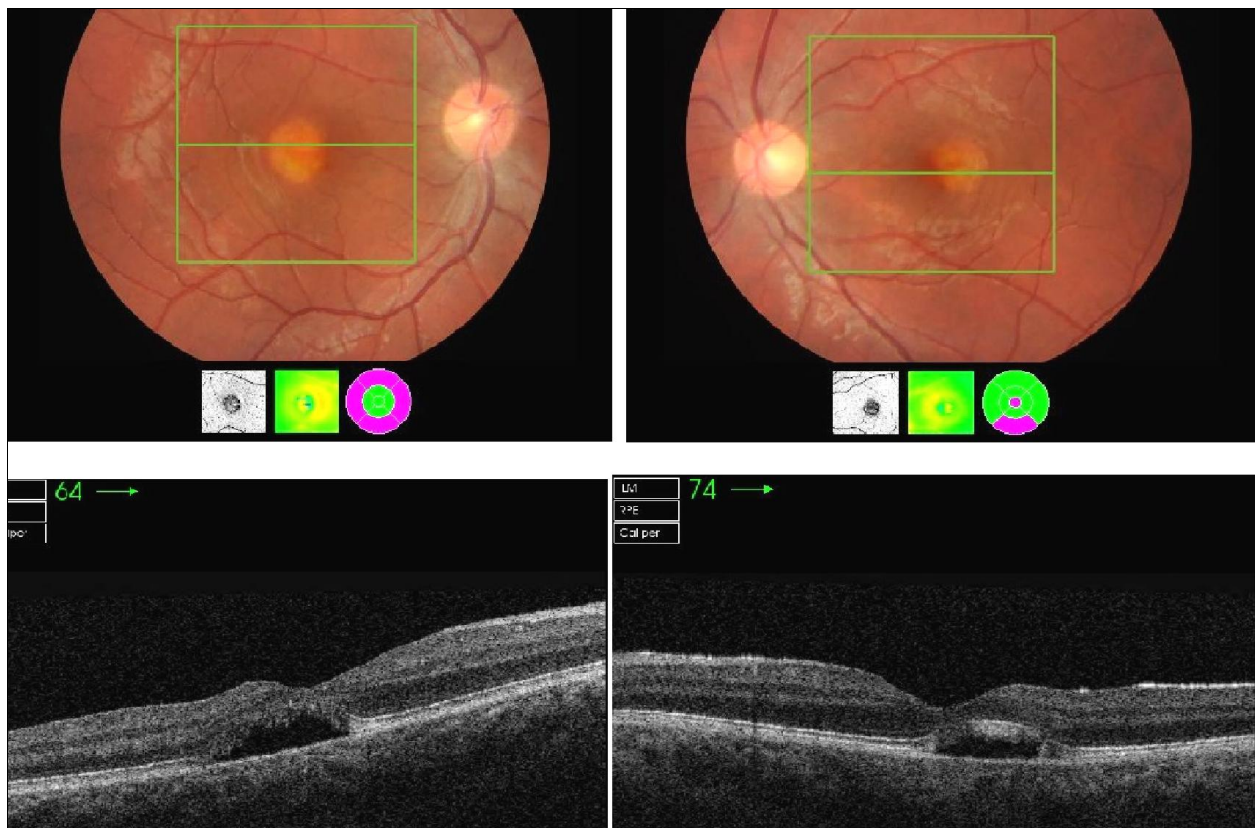


Figure-1

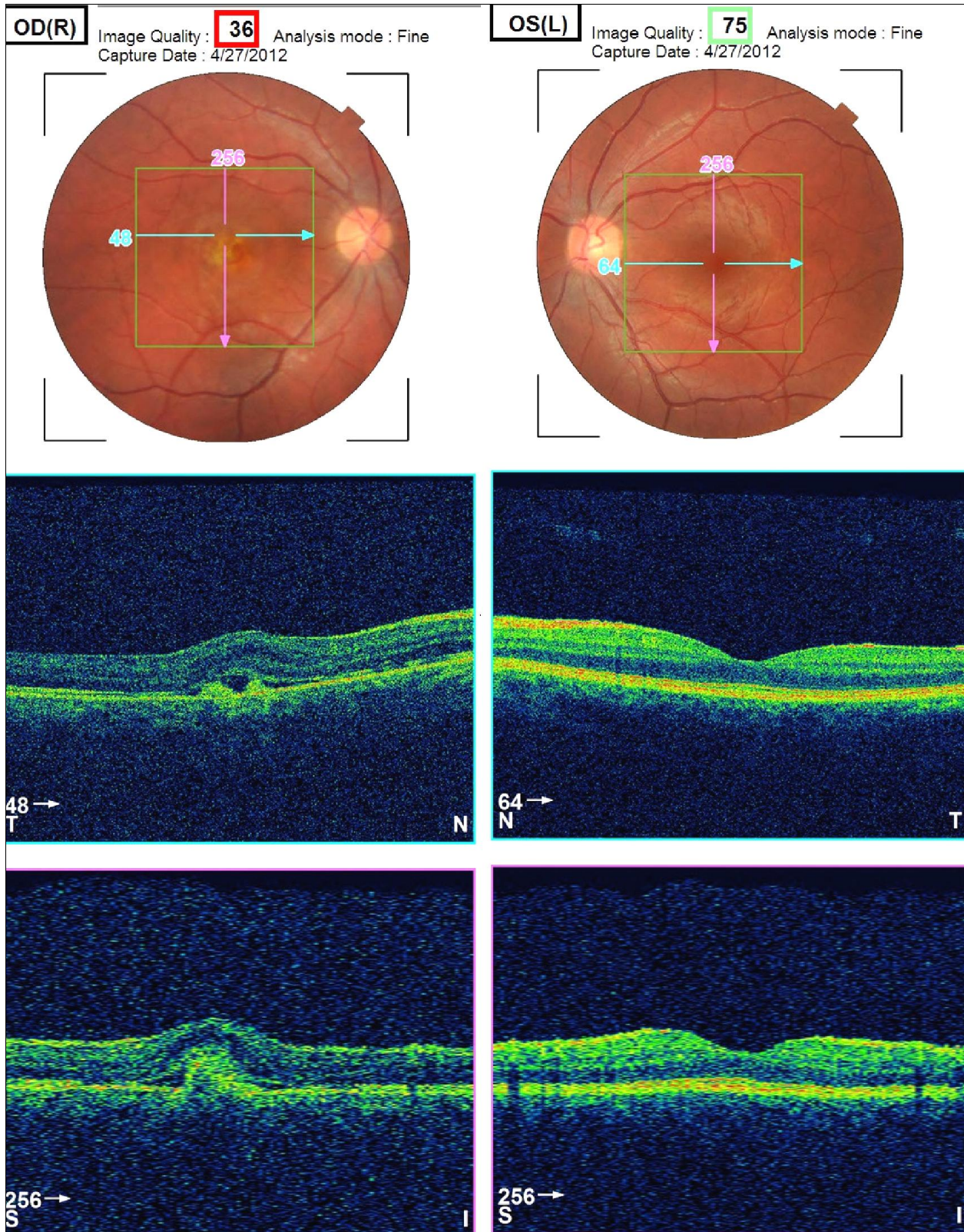


Figure-2

CASE REPORT

Twin brothers 24 years of age presented to eye OPD of Shifa falah community health centre with visual complaints for last six months. Parents were first cousins. Family history was not significant for any eye diseases

CASE-1

The patient had best corrected visual acuity (BCVA) 6/12 in both eyes. Typical round egg-yolk like lesion involving the fovea were seen in both eyes. OCT showed typical hyporeflective material in the subretinal space characteristic of vitelliform lesions of BVMD (Figure-1).

CASE-2

The second patient had BCVA 6/36 in right eye and 6/6 in left eye. Fundoscopy and OCT showed choroidal neovascular membrane (CNVM) in right eye and thickening of bruch's membrane in left eye (Figure-2).

Patient was given intravitreal bevacizumab (1.25mg in 0.05 ml) in right eye. CNVM regressed and vision improved to 6/18. Patient retained stable vision after two years follow up.

DISCUSSION

BVMD is a progressive disease of the macular area, associated with long-term loss of vision. Onset of the disease is predominantly early in life, often occurring by 10 years of age.¹ The disease typically presents in children.⁴ Our patients presented at the age of 24 years, which is unusual age of presentation for this disease. Relatively few cases have been reported for onset in the second decade of life.⁵ Adult onset vitelliform macular dystrophy however present at a later age (late middle or old age¹).

Familial cases of BVMD have been described amongst the Spanish, Danish, Italian,

French, American, Chinese and Malay families.⁶ Based on a Pub Med literature search; this is the first report of BVMD in individuals of Afghan decent. To author's best knowledge there is no case report of twins who presented with BVMD in local or international literature. So our case report is unique as we present twin brothers with this disease.

CNVM in our patient responded well to the single dose of intravitreal bevacizumab. These results are consistent with an observation by Ruiz-Moreno *et al*⁷, showing excellent outcome in with a single injection of intravitreal ranibizumab for CNVM secondary to BVMD.

This is the first documented case of BVMD in twins and first one of Afghan descent. CNVM secondary to BVMD is effectively managed with a single dose of intravitreal bevacizumab.

REFERENCES

1. Kanski JJ. Hereditary fundus dystrophies. In: Bowling B, editor. Kanski's clinical ophthalmology: a systematic approach. 8th ed. s.l.: Elsevier; 2016. p.660.
2. Budiene B, Liutkeviciene R, Zaliuniene D. Best vitelliform macular dystrophy: literature review. Open Med 2014;9(6):784–95.
3. Huang S, Wu L, Wen F, Luo G, Jiang F. Follow-up of a case of vitelliform macular dystrophy over an 8-year period. Eye Sci 2014;29(3):165–9.
4. Griffith JF, Hess DJ, Berrocal AM. Best's vitelliform macular dystrophy in 10- and 31-month-old siblings. J Pediatr Ophthalmol Strabismus 2014;4:51.
5. Renner AB, Tillack H, Kraus H, Krämer F, Mohr N, Weber BH, *et al*. Late Onset is Common in Best Macular Dystrophy Associated with VMD2 Gene Mutations. Ophthalmology 2005;112(4):586–92.
6. Alisa-Victoria K, Jin-Poi T, Shatriah I, Zunaina E, Ngah NF. Choroidal neovascularization secondary to Best's vitelliform macular dystrophy in two siblings of a Malay family. Clin Ophthalmol 2014;8:537–42.
7. Ruiz-Moreno O, Calvo P, Ferrández B, Torró C. Long-term outcomes of intravitreal ranibizumab for choroidal neovascularization secondary to Best's disease: 3-year follow-up. Acta Ophthalmol 2012;90(7):574–5.

Address for Correspondence:

Dr Ayisha Kausar, Ophthalmology Department, Shifa College of Medicine, H 8/4, Pitrus Bukhari Road, Islamabad-Pakistan

Cell: +92 300 526 6525

Email: drayisha_79@hotmail.com