

## QUIZ

## IDIOPATHIC FASCICULAR LEFT VENTRICULAR TACHYCARDIA: A DIAGNOSTIC CHALLENGE

Chee Yik Chang

Medical Department, Kapit Hospital, Jalan Mamora, 96800 Kapit, Sarawak-Malaysia

A 28-year-old female, with no prior medical illness presented with intermittent palpitation for 1 week duration. She denied dyspnoea, chest pain, syncope or symptoms of hyperthyroidism. She reported no family history of heart disease or sudden cardiac death. Upon presentation, her blood pressure was 100/69 mmHg and heart rate was 137 beats per minute. Clinically, there were no signs of anaemia, heart failure or valvular abnormality. The blood investigations including serum electrolytes and thyroid function test were within the normal limits and transthoracic echocardiography revealed a structurally normal heart. The ECG showed narrow complex ventricular tachycardia with atrioventricular dissociation, left axis deviation (LAD) and right bundle branch block (RBBB) (Figure-1a). However, it was initially misinterpreted as atrial fibrillation with rapid ventricular response. As a result, beta-blocker, digoxin, and amiodarone were given sequentially as an attempt to terminate the arrhythmia, but to no avail. Finally, the diagnosis was revised to idiopathic fascicular left

ventricular tachycardia (IFLVT) in view of the ECG findings. Intravenous verapamil was administered and the arrhythmia was successfully terminated with verapamil 7.5 mg (Figure-1b).

She was started on maintenance oral verapamil while waiting for catheter ablation at a later date. Idiopathic fascicular left ventricular tachycardia is a rare, well-known form of ventricular tachycardia which typically affects young adults (15–40 years) without structural heart disease. The most frequent clinical presentation is paroxysmal episodes of palpitations, dizziness and, less frequently, syncope.<sup>1</sup> IFLVT is a ventricular tachycardia (VT) characterized by RBBB and LAD on ECG. It may be confused with either typical VT or supraventricular tachycardia, causing difficulty or delay in diagnosis.<sup>2</sup> Intravenous verapamil is effective in terminating the tachycardia. Catheter ablation is the preferred choice of therapy in cases of IFLVT with high success rate of more than 80%, and associated complications are infrequent.<sup>3</sup>

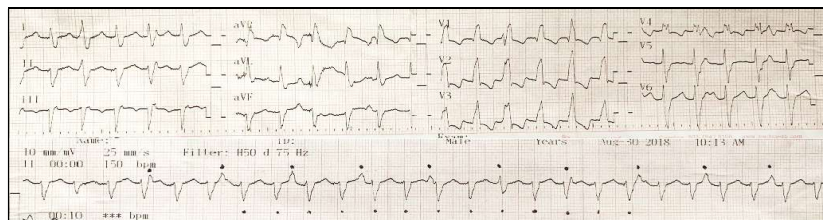


Figure 1a ECG shows narrow complex ventricular tachycardia with atrioventricular dissociation, left axis deviation and right bundle branch block.

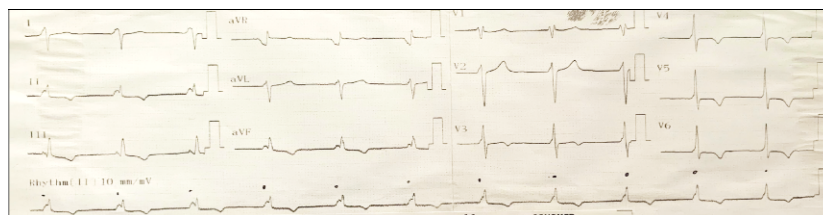


Figure-1b: Restoration of normal sinus rhythm post-administration of verapamil

### REFERENCES

1. Reviriego S. Idiopathic fascicular left ventricular tachycardia. E-J ESC Counc Cardiol Pract 2010;9:13.
2. Alahmad Y, Asaad N, Arafa S, Ahmad Khan S, Mahmoud A. Idiopathic fascicular left ventricular tachycardia. Heart Views 2017;18(3):83–7.
3. Ramprakash B, Jaishankar S, Rao HB, Narasimhan C. Catheter Ablation of Fascicular Ventricular Tachycardia. Indian Pacing Electrophysiol J 2008;8(3):193.

Citation: Chang CY. Idiopathic fascicular left ventricular tachycardia. J Ayub Med Coll Abbottabad 2021;33(4):702.

### Address for Correspondence:

Chee Yik Chang, Medical Department, Kapit Hospital, Jalan Mamora, 96800 Kapit, Sarawak-Malaysia

Email: ccyik28@gmail.com