

## ORIGINAL ARTICLE

## SUCCESS RATE OF OVERFILLED ROOT CANAL TREATMENT

Waqas Yousuf, Moiz Khan\*, Abubakar Sheikh\*\*

Department Oral Surgery, Department of Oral Pathology\*, Department of Endodontics\*\*, Fatima Jinnah Dental Hospital, Karachi-Pakistan

**Background:** Traditionally, poor obturation has been considered the primary cause of root canal treatment failures. The purpose of this study was to assess the success rate of overfilled root canal treatment cases in order to decide whether a definitive restoration can be placed immediately following treatment in an overfilled case or whether the patient needs to be kept on a follow up prior to the placement of a definitive restoration. **Methods:** A total of 1242 patient's periapical radiographs (1748 teeth) were assessed, out of which 397 teeth (in 285 patients) were found to be overfilled. Out of these 285 patients, 111 (128 cases) agreed to participate in this cross sectional study and were recalled for clinical and radiographic examination. Success was evaluated clinically by absence of symptoms (pain, swelling, tenderness to percussion and sinus tract) and radiographically by the decrease in size of periapical lesion or no change in size. Increase in size of periapical lesion was deemed to be a failure. **Results:** Our findings revealed that despite overfill, the treatment was successful in 115 cases and failure was noted in 13 cases showing an overall success rate of 89.8% and failure rate of 10.2%. Out of 13 cases of failure, all 13 showed an increase in periapical lesion size, out of which 10 were accompanied with pain. **Conclusion:** We have determined that there is no need to delay placement of a permanent restoration on overfilled teeth (ruling out the presence of other procedural errors) nor is there any need to pursue any further surgical or non-surgical endodontic treatment. However we would suggest that patients should be kept on follow-up after placement of permanent restoration.

**Keywords:** Overfill, root canal treatment, definitive restoration, success rate

J Ayub Med Coll Abbottabad 2015;27(4):780-3

## INTRODUCTION

Traditionally, poor obturation has been considered the primary cause of root canal treatment failures. An early study by Ingle and Colleagues<sup>1</sup> cited inadequate obturation to be the most common cause of endodontic treatment failure (58% of treatment failures).

Evaluation of obturation is challenging as the only means of immediate assessment is through a radiograph. Orstavik and Associates<sup>2</sup> suggested the use of periapical index (PAI) as a viable method for radiographic assessment of an endodontic treatment outcome. The evaluation criteria as determined by studying the obturation radiographs are as follows<sup>3</sup>; 1. No voids 2. Uniform density from coronal to apical aspect 3. The material should extend to the prepared length 4. The obturation should reflect the taper created during canal preparation.

Historically, the apical extent of root filling material has remained controversial amongst the endodontic academia. Many studies have shown that size and location of the foramen relative to the apex can be quite unpredictable due to a high degree of variability. However, anatomic studies indicate that the point of termination should be 1mm from the radiographic apex.<sup>4,5</sup>

Extrusion of obturating material beyond the apex is termed as overfill or over obturation. Over instrumentation and inability to provide a proper taper usually leads to overfill.<sup>3</sup> Overfills are undesirable as the relationship of failures with time increases when the obturating material extrudes beyond the apex as the extruded material negatively affects the regeneration of periapical tissues.<sup>6-8</sup>

The response of the peri-radicular tissues to the canal obturating material determines the prognosis of an endodontic treatment. A small amount of endodontic material beyond the apex could be considered admissible only if does not constitute an insult to vitally important structures in close proximity to the roots (such as inferior alveolar nerve canal in mandibular teeth).<sup>9</sup> Another study suggested that extruded obturation material does not influence the endodontic outcome in well treated teeth.<sup>10</sup>

The purpose of our study was to assess the success rate of overfilled root canal treatment cases in order to decide whether a definitive restoration can be placed immediately following treatment in an overfilled case or whether the patient needs to be kept on a follow up prior to the placement of a definitive restoration.

## MATERIAL AND METHODS

This cross sectional study was conducted at Fatima Jinnah Dental College. A total of 1242 patient's periapical radiographs (1748 teeth) were assessed, out of which 397 teeth (in 285 patients) were found to be overfilled. Out of these 285 patients, 111 (128 cases) agreed to participate in this study and were recalled for clinical and radiographic examination. All teeth which were included in the study had been prepared using conventional stainless steel hand files with a crown down technique. Gates Glidden burs (no. 2 and 3) were used for coronal flaring prior to cleaning and shaping. Starting with #55 k files, canals were shaped sequentially using #50 k, #45 k, #40 k and #35 k files respectively. The #30 k file was taken as master apical file. Sodium hypochloride (5%) solution was used for irrigation in between filing. Obturation was done using lateral condensation technique. Periapical radiograph of each endodontically treated tooth was taken immediately after obturation and was stored using DIGORA® Optime.

All permanent root canal treated teeth in which gutta percha had extruded beyond the radiographic apex in at least one root were included in the study. Male and female patients aged between 12 to 70 years who had received root canal treatment at least six months prior to their recall were evaluated. Only teeth retaining permanent restoration and no more than grade 1 mobility at the time of evaluation were included in the sample. All teeth with vertical root fracture, any other procedural errors (such as separated instrument, underfilled canal, perforations, ledge formation, apical transportation etc.) and teeth in which retreatment was performed were not included in the study. Patients with debilitating medical conditions were also excluded. All cases in which gutta percha was seen to extrude beyond the radiographic apex were considered overfilled. Before selecting the overfilled cases for inclusion in this study a radiographic evaluation was done for assessing the quality of obturation. Only those cases with a uniform taper and homogenous density were recruited in this study. All the patients who fulfilled the inclusion criteria were recalled after approval from the Institutional Ethical Review Committee. After establishing informed consent with each individual patient, a periapical radiograph was obtained using a paralleling technique for each overfilled tooth and a clinical examination was performed. Evaluation was done based on the following criteria:

**Clinically:** Presence or absence of symptoms (pain, swelling, tenderness to percussion and sinus tract) were established.

**Radiographically:** The follow-up radiograph was compared with the initial post treatment radiograph and any changes in the periapical status in regards to the presence or absence and size of the periapical lesion was noted. Treatment was considered as an 'endodontic success' when clinically the patient remained asymptomatic and radiographically there was no development of a new periapical lesion nor an increase in size of a previous lesion. Treatment was considered as an 'endodontic failure' when clinically patient showed any of the previously mentioned symptoms and radiographic development of a new periapical lesion or increase in size of a previous lesion was observed. Radiographs were assessed by two assistant professors and in case of difference of opinion the relevant x-ray was shown to the professor of the department and his opinion was taken as final. SPSS-21 was used for data analysis

## RESULTS

A total of 1748 non-surgical root canal treated teeth in 1242 patients were examined, out of which 397 teeth (in 285 patients) were found to be overfilled. Females accounted for 230 cases (58.2%) and males 165 cases (41.8%). However, this female predominance was not statistically significant ( $p=0.072$ ).

Overfill was most common in molars (62.5%), followed by premolars (20.4%), incisors (14.4%) and canines were the least affected group (2.8%) See figure-1. Molars accounting for the most number of overfill cases was statistically significant ( $p<0.05$ ) Amongst molars permanent right mandibular first molar was shown to present with the most number of overfill cases (19.6%), followed by permanent left mandibular first molar (14.9%), permanent right maxillary first molar (10.1%) and permanent left maxillary first molar (8.8%). Mandibular right canine, mandibular right lateral incisor and mandibular left lateral incisors proved to be the least affected teeth (0.3% each). See figure 2

Out of the 13 cases of failure, the vast majority (10 cases) were noted in molars, 1 in premolars and 2 in anterior teeth (incisors and canines). In particular, 30.8% of failures (4 cases) were noted in permanent right mandibular first molar and 23.1% (3 cases) in permanent left mandibular first molar. However, no significant relationship could be ascertain between molars and failures ( $p=0.38$ )

Interestingly, 10 cases of failure were noted in females compared with only 3 in males. However, this did not prove to be statistically significant ( $p=0.08$ ).

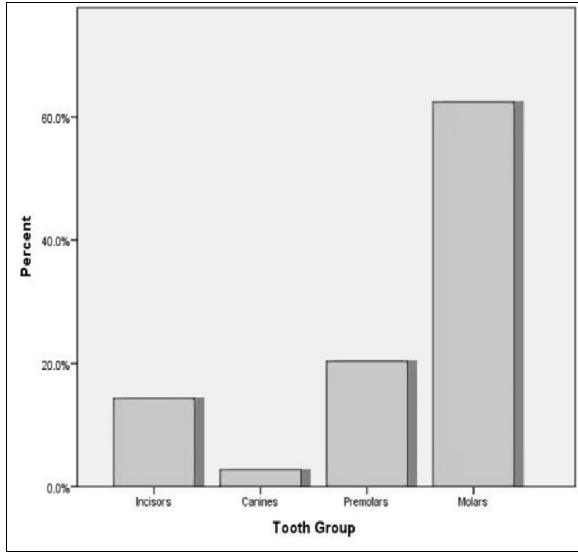


Figure-1: Overfill distribution in different tooth groups

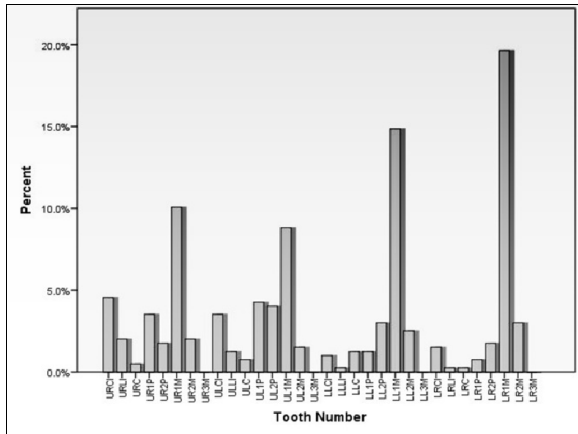


Figure-2: Overfill distribution in individual teeth

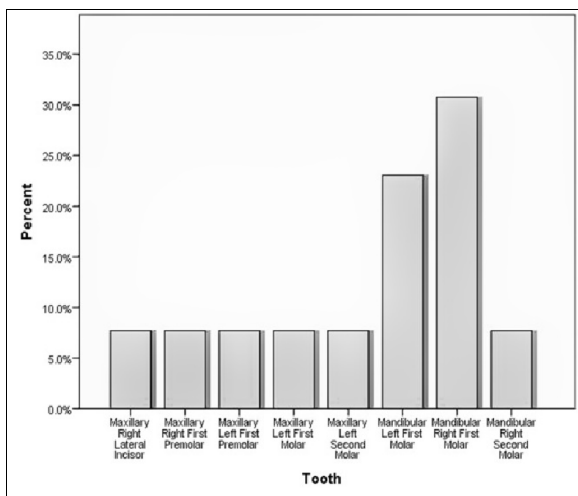


Figure-3: Distribution of failure rate of overfill cases in individual teeth

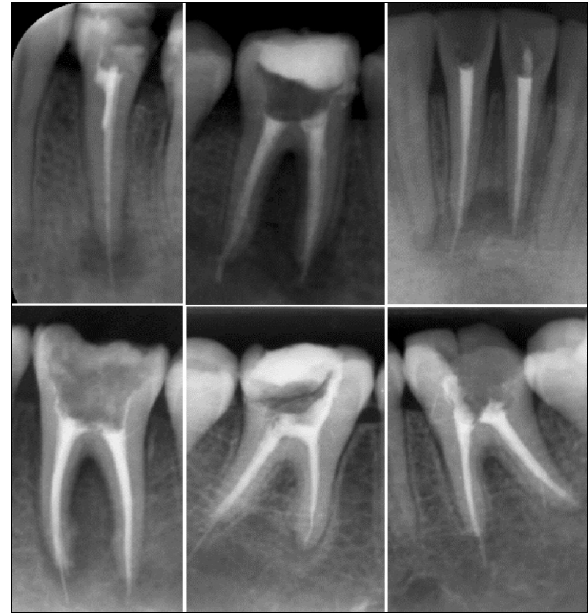

Figure-4: Extrusion of gutta percha beyond the apex

Table-1: Success rate of overfilled root canal treatment

	Frequency	Percent
Success	115	89.8
Failure	13	10.2

Table-2: Periapical lesion size at follow-up

Periapical lesion at recall	Frequency	Percent
Increase	13	10.2
Decrease	45	35.1
Same	70	54.7

DISCUSSION

Gutta percha is one of the most commonly used obturating materials and it is the standard to which other obturating materials are compared. Gutta percha has many advantages over other obturating materials, the most important being that it is nearly inert<sup>11</sup> over time when in contact with the periapical tissues.

However, despite this gutta percha should not extend into the peri-apical tissues as studies have shown that the point of termination of the root filling material should be 0–2 mm from the radiographic apex.<sup>12</sup> Various studies conducted on the outcome of initial non-surgical endodontic treatment (within 2 mm of the radiographic apex) shows a success rate of about 94%.<sup>13,14</sup>

Overfills are undesirable as they have been shown to reduce the regenerative potential of the periapical tissues<sup>6–8</sup> and can cause complications such as pain, persistent pus discharge and headache. Therefore, overfills are often cited as endodontic failure. Fortunately, other studies have shown most overfill cases do not fail and prove to have a long term success, indicating that elimination of

microorganisms from the root canal system is of greater significance for endodontic outcome than the length of obturation. This was well demonstrated by Louie *et al*<sup>11</sup> in which no correlation was observed between endodontic outcome and overfill.

In our study, the vast majority of overfilled cases showed endodontic success (89.8%) despite the extrusion of gutta percha. However, a small but significant percentage of overfilled cases (10.2%) were associated with an increase in size of periapical lesion or development of a new lesion, surrounding the gutta percha.

Resorption of gutta percha was observed in the majority of cases indicating a positive trend of resorption of gutta percha in the peri-apical tissues. Our results showed that extrusion of gutta percha beyond the radiographic apex is not a significant factor on which endodontic success or failure depends, provided the root canal system has been adequately cleaned, is devoid of microorganisms and an adequate apical and coronal seal has been obtained.

In certain cases when gutta percha has extruded beyond the apex and prognosis is doubtful due to any other mitigating circumstances (e.g. ledge formation, instrument separation, etc.), such cases may be kept on follow-up prior to placement of a definitive restoration until the patient is completely symptom free. In our study, as well as in other studies, it has been proved that extruded gutta percha does not usually cause any symptoms therefore it is not justified to withhold a definitive restoration in these cases. Lack of a permanent restoration may compromise structural integrity and coronal seal of the tooth, which may ultimately result in treatment failure. Therefore we would recommend that a definitive restoration should be placed immediately following obturation in overfilled cases if no other mitigating conditions exist.

## CONCLUSION

Based on the results obtained in our study, we have determined that there is no need to delay placement of a permanent restoration on overfilled teeth (ruling out the presence of any other procedural errors) nor is there any need to pursue any further surgical or non-surgical endodontic treatment. However we would suggest that patients should be kept on follow-up

after placement of a permanent restoration.

## ACKNOWLEDGEMENTS

The authors would like to thank all the participants for their time and cooperation. The authors deny any conflicts of interest.

## AUTHOR'S CONTRIBUTION

WY: Contributed to the design, conception, data collection, writes up and gave the final approval. MK: Contributed to the design, conception, data collection, writes up and gave the final approval. AS: design, conception and gave the final approval.

## REFERENCES

1. Ingle JI, Bakland LK, Baumgartner J (Eds). Ingle's endodontics (6th ed). Hamilton, Ontario: BC Decker, Inc 2008:1400–25.
2. Ørstavik D, Kerekes K, Eriksen HM. The periapical index: A scoring system for radiographic assessment of apical periodontitis. *Endod Dent Traumatol* 1986;2(1):20–34.
3. Walton RE, Torabinejad M. Principles and practice of endodontics. 3<sup>rd</sup> ed. Philadelphia: W.B. Saunders Company, 2002;262–3.
4. Chapman CE. A microscopic study of the apical region of human anterior teeth. *J Br Endod Soc* 1969;3(4):52–8.
5. Dummer PM, McGinn JH, Rees DG. The position and topography of the apical canal constriction and apical foramen. *Int Endod J* 1984;17(4):192–8.
6. Sjögren U, Hagglund B, Sundqvist G, Wing K: Factors affecting the long-term results of endodontic treatment. *J Endod* 1990;16(10):498–504.
7. Friedman S, Löst C, Zarrabian M, Trope M. Evaluation of success and failure after endodontic therapy using a glass ionomer cement sealer. *J Endod* 1995;21(7):384–90.
8. Smith CS, Setchell DJ, Hartly FJ. Factors influencing the success of conventional root canal therapy- a five-year retrospective study. *Int Endod J* 1993;26(6):321–33.
9. Hargreaves KM, Cohen S. Pathways of pulp. 10<sup>th</sup> ed. St. Louis: Mosby Elsevier; 2011. p.425.
10. Lin LM, Skribner JE, Gaengler P. Factors associated with endodontic treatment failures. *J Endod* 1992;18(12):625–62.
11. Wolfson EM, Seltzer S. Reaction of rat connective tissue to some gutta-percha formulations. *J Endod* 1975;1(12):395–402.
12. Unal GC, Kececi AD, Kaya BU, Taca AG. Quality of root canal fillings performed by undergraduate dental students. *Eur J Dent* 2011;5(3):324–30.
13. Imura N, Pinheiro ET, Gomes BP, Zaia AA, Ferraz CC, Souza-Filho FJ. The outcome of endodontic treatment: A retrospective study of 2000 cases performed by a specialist. *J Endod* 2007;33(11):1278–82.
14. Lazarski MP, Walker WA 3rd, Flores CM, Schindler WG, Hargreaves KM. Epidemiological evaluation of the outcomes of non-surgical root canal treatment in a large cohort of insured dental patients. *J Endod* 2001;27(12):791–6.

## Address for Correspondence:

Dr. Waqas Yousuf, Fatima Jinnah Dental Hospital, Building No. 1, Street No.1, Azam Town, Opp: D.H.A. Phase-1, Karachi-75460-Pakistan

Cell: +92 323 229 6229

Email: waqas.yousuf@hotmail.com