

ORIGINAL ARTICLE

SAVING THE UTERUS; OUR EXPERIENCE IN UTERINE ARTERY EMBOLIZATION FOR ACQUIRED UTERINE VASCULAR ABNORMALITIES

Laiba Masood, Zahid Amin Khan, Muhammad Shozab Ahmad, Atif Iqbal Rana, Haider Ali

Shifa International Hospital, Islamabad-Pakistan

Background: Acquired uterine vascular abnormalities are a rare cause of potentially life-threatening bleeding. These include uterine artery pseudoaneurysms (UAP) and acquired arteriovenous malformations. The objective of this study was to describe our experience with the diagnosis of acquired uterine vascular abnormalities and its treatment with uterine preservation. It was a retrospective cohort study. **Methods:** Eight patients were enrolled from the hospital database who presented to our Interventional Radiology department from April 2017 to March 2021 for uterine artery embolisation (UAE) with a history of iatrogenic/acquired uterine vascular abnormalities confirmed on imaging. These included two patients with uterine artery pseudoaneurysm (PA) concurrently with arteriovenous malformation (AVM), one with uterine artery PA and five having uterine AVMS. Embolisation agents used were histoacryl glue, lipiodol, PVA particles, and gelfoam slurry. Medical records, imaging studies, and telephonic contact with patients were assessed for patient presentation, intraprocedural details, and follow up to record treatment success. Statistical analysis was performed using descriptive statistics. **Results:** Bilateral UAE was performed in six patients, while two patients underwent unilateral UAE. Three of the patients presented with life-threatening bleeds requiring multiple transfusions. Clinical as well as angiographic success was achieved in all patients with immediate control of haemorrhage. No complications were observed during follow-up. Two of the patients were able to conceive normally within one year, though it resulted in a miscarriage. **Conclusion:** Acquired/iatrogenic uterine vascular abnormalities are a rare but important cause of life-threatening haemorrhage that can be expertly managed and successfully treated using UAE, which is rapid, safe, and minimally invasive, with the added advantage fertility preservation.

Keywords: Arteriovenous malformation; Uterine artery embolization; Intervention

Citation: Masood L, Khan ZA, Ahmad MS, Rana AI, Ali H. Saving the uterus; our experience in uterine artery embolization for acquired uterine vascular abnormalities. J Ayub Med Coll Abbottabad 2022;34(4 Suppl 1):913-8.

DOI: 10.55519/JAMC-04-S4-9665

INTRODUCTION

Acquired uterine vascular abnormalities are a rare cause of potentially life-threatening bleeding. These include uterine artery pseudoaneurysms (UAP) and acquired arteriovenous malformations (AVM).¹ Although, a differential diagnosis of retained products of conception (RPOCs) or gestational trophoblastic disease (GTP) is customarily given precedence in a patient who presents with post-partum/post-abortive vaginal bleeding, at the same time, acquired uterine arterial lesions necessitate deliberation and a high index of suspicion to alleviate the patient's symptoms. The iatrogenic injury from either caesarean section, dilatation and curettage for either termination of pregnancy or removal of retained products of the placenta can rarely result in the abnormal formation of these blood vessels. Damage to the arterial wall can lead to focal destruction of the intimal layer, blood leakage, and expansion of the adventitia that communicates with the artery lumen, leading to the formation of

pseudoaneurysm sacs.² Acquired uterine AVM develops by communication between the uterus's intramural arterial branches and the venous plexus that supplies the myometrium in either the myometrium or endometrium, as opposed to true capillary nidus found with congenital AVMS that can form anywhere. The gestational trophoblastic disease is another well-known culprit for the formation of uterine AVFs.^{3,4}

Typical manifestations are prolonged post-partum bleeding, uterine dysfunction and dysmenorrhea/pelvic pain. Since these cases often go misdiagnosed, iron deficiency anaemia is also a common feature.²

Among young patients who wish to preserve fertility, uterine artery embolisation (UAE) is the most favoured treatment of choice and supersedes conventional hysterectomy.^{1,4,5} It is a minimally invasive, effective, and clinically successful option in controlling bleeding and symptoms. Acquired uterine vascular abnormalities are a significant cause of

prolonged post-partum bleeding in young females. Historically, this condition has been under-reported and undiagnosed due to the nonavailability of high-quality cross-sectional imaging and therefore increased awareness is needed to diagnose and appropriately manage this cohort of young women. This study highlights the importance of uterine artery embolisation in these patients, especially those who do not wish or need to undergo hysterectomy, as a treatment option that also preserves fertility, as described in our results. Since interventional radiology has begun to set its foot in Pakistan, we are entering a new era, and our clinicians must be well-versed in the process that has been in practice in the west for decades.

Our article describes the latest techniques employed in embolisation with potential pitfalls and guides for other aspiring interventional radiologists or centres who wish to entertain and cater to interventional radiology services.

MATERIAL AND METHODS

After approval from the hospital review board, a total of eight patients were enrolled from the hospital database from April 2017 to March 2021 who presented to our Interventional Radiology department at Shifa International Hospital, Islamabad for UAE, with a history of iatrogenic/, acquired uterine vascular abnormalities, confirmed on imaging (Doppler ultrasound, Computed Tomography (CT) or Magnetic Resonance Imaging (MRI). Radiology Database and patient medical records were searched for patients' demographic details, patient presentation, transfusion requirement, and intraprocedural details (including angiographic details, embolisation agent used, and laterality of bleeding), etc. Imaging studies and telephonic contact with patients were assessed for the follow-up to record treatment success.

Technical success was defined as embolisation of the uterine arteries and/or ovarian artery that supplied the uterine vascular abnormality. We labelled clinical success as any of the following: the resolution of abnormal per vaginal bleeding, thrombosis of the uterine vascular abnormalities on follow-up imaging studies and prevention of hysterectomy. Images from these patients' CT angiography and/or MRI, conventional angiography, were collected from the Picture Archiving and Communication System (PACS). We performed statistical analysis using descriptive statistics.

The patients included two with uterine PAs and AVMs, one patient with PA and five with uterine AVMs. UAE was performed in a dedicated interventional radiology angiography suite by qualified interventional radiologists under local anaesthesia (Table-1). We obtained right groin access and then placed a 5F sheath and 5 Fr Uterine artery catheter

(UAC, 5F by Merit medical) as a primary catheter to reach the anterior division of the internal iliac artery. Subsequently, different microcatheters were used for embolisation purposes. In four cases, histoacryl glue and lipiodol were used for embolisation, while PVA particles (500–700 µm) with gel foam slurry were used to achieve the hemostasis in two patients along with a combination of PVA particles with micro-coils in another patient. We also used just PVA particles (350–500 µm) to treat AVM in one of the cases.

RESULTS

The median age of the patient cohort was 31 years (range 28–42 years). The average parity was 1.5. Risk factors for acquired uterine vascular abnormalities were recorded (Table-1). Out of eight, five patients had a recent history of lower section cesarean sections (LSCS), and all patients in our cohort had undergone dilatation and curettage (DNC). Three patients had a history of molar pregnancy requiring therapeutic abortions.

Abnormal vaginal bleeding and lower abdominal pain was the leading complaint, and three patients required transfusion of blood products immediately upon presentation. One patient required transfusion of four units of red cell concentrate (RCC)s with four units of fresh frozen plasma (FFP)s, others had four, and three units of RCCs transfused, respectively. Three of our patients had also been transfused at an outside facility before presenting to us. The haemoglobin levels of these patients ranged between 6–11.7 g/dl (Table-1).

The average duration of days from the intervention date to the patient presentation was 32.8 days (range 14–60).

CT angiography (CTA) was used to diagnose these vascular abnormalities in three patients who were unstable at presentation (Figure. 1A and B), while in the rest, post-contrast MRI was done (Figure. 2A and B). One patient underwent pre-procedure USG followed by dynamic MRI for diagnosis (Table-1).

Five patients had AVMs, while two had a combination of PAs with AVMs and another patient presented with PA. During angiography, one of the patients was diagnosed with 2 cm PA of the left ovarian artery in addition to AVM, which was not demonstrated on MRI imaging (Figure. 3A and B). The size of AVMs ranged between 3.8 to 5.7 cm in the greatest dimensions.

A total of six patients who met the inclusion criteria had undergone bilateral UAEs. One of them underwent bilateral UAE with ovarian artery embolisation as well. Two of the patients underwent unilateral UAE with complete recovery of symptoms. In one of the patients, unilateral UAE was attempted initially, but due to continuous per vaginal bleeding,

bilateral UAE was performed the next day to secure hemostasis and achieve clinical success (Table-1).

Clinical success, defined as resolution of symptoms, was achieved in all patients with immediate control of haemorrhage. Patients were discharged the following day with instructions for follow-up and reappearance of symptoms. No complications were observed during follow-up. Following successful embolisation, the normal menstrual cycle was restored

within an average duration of three months. Due to successful embolisation, not a single patient had to undergo a hysterectomy.

When available, the postprocedural imaging, which included ultrasound (Figure-4) and MRI, did not demonstrate any residual abnormality. Two patients could normally conceive within one year, though it resulted in miscarriage, one at eight weeks of gestation while the other at six weeks.

Table- 1: Obstetric history, imaging findings and uterine artery embolisation details of the patients in the study cohort.

Patient	Obstetric history	Parity	Hemoglobin mg/dl/ transfusion	Imaging for diagnosis	Diagnosis	Uterine artery embolisation		
						Laterality of UAE	Embolisation Agent	Technical/ Clinical success
Patient 1	2 LSCS 1 DNC 1 Molar pregnancy	P2+1	6.5 4 RCCs	CTA	AVM+ PA	Bilateral	PVA + micro-coils	Achieved
Patient 2	2 DNCs 1 Molar pregnancy	P3+2	11.5	CTA	AVM	Bilateral	Histoacryl glue + lipiodol	Achieved
Patient 3	1 DNC	P0+1	11.7	USG+MRI	AVM	Bilateral	Histoacryl glue + lipiodol	Achieved
Patient 4	2 LSCS 2 DNCs for Molar pregnancy	P2+2	6 4 RCCs 4 FFPs	MRI	AVM+ PA	Bilateral + left OA	PVA+ Gelfoam	Achieved
Patient 5	1 DNC	P1+1	10.3 (transfused outside)	CTA	AVM	Unilateral followed by bilateral	PVA	Achieved after bilateral procedure
Patient 6	1 LSCS 1 DNC	P2+1	8.6 (transfused outside)	MRI	PA	Bilateral	PVA+ Gelfoam	Achieved
Patient 7	1 LSCS 1 DNC	P1+1	7 3 RCCs	MRI	AVM	Unilateral	Histoacryl glue + lipiodol	Achieved
Patient 8	1 LSCS 2 DNCs	P2+2	8.8 (transfused outside)	MRI	AVM	Unilateral	Histoacryl glue + lipiodol	Achieved

LSCS- lower segment cesarian section, RCC- red cell concentrate, FFPs- fresh frozen plasma, DNC- Dilatation and curettage, MRI- magnetic resonance imaging, CTA- CT angiography, USG- Ultrasound, AVM- arteriovenous malformation, PA- pseudoaneurysm, OA- ovarian artery, UAE- uterine artery embolisation.

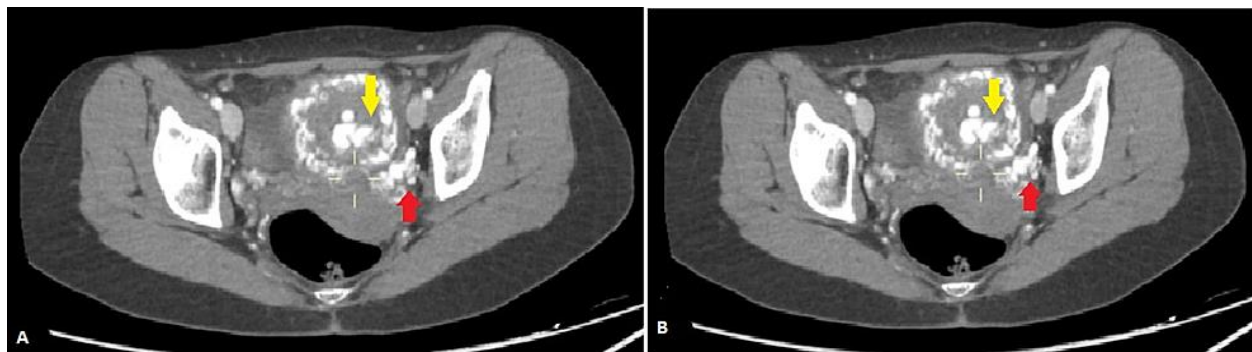


Figure-1: (A and B) CT Vascular angiography, arterial phase image of a 28-year-old female, showing large tuft of vessels within the posterior aspect of the endometrial cavity (red arrow), with extensive collateral in the myometrium, suggesting AVM/AVF with nidus (yellow arrow).

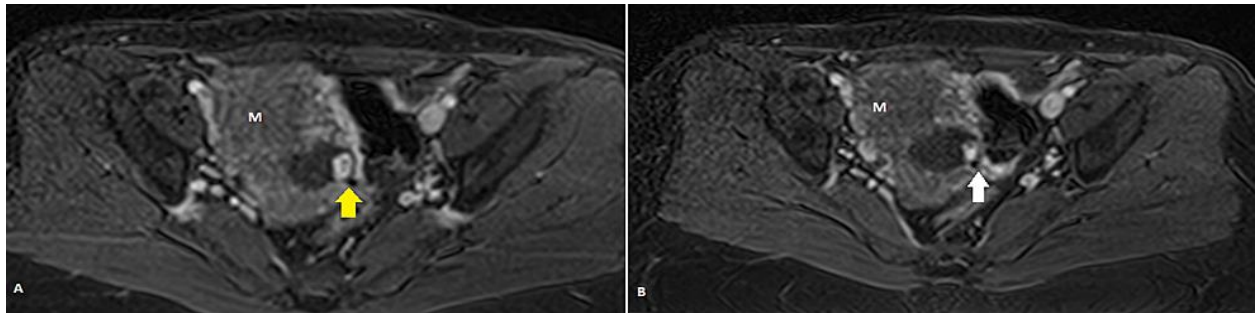


Figure-2: (A and B) Dynamic T1 post-contrast MRI image of a 32-year-old female showing heterogenous uterine parenchyma (M) with abnormal signal in the lower uterine segment (yellow arrow), large vessel (white arrow) reaching up to it with adjacent multiple tortuous uterine vessels.

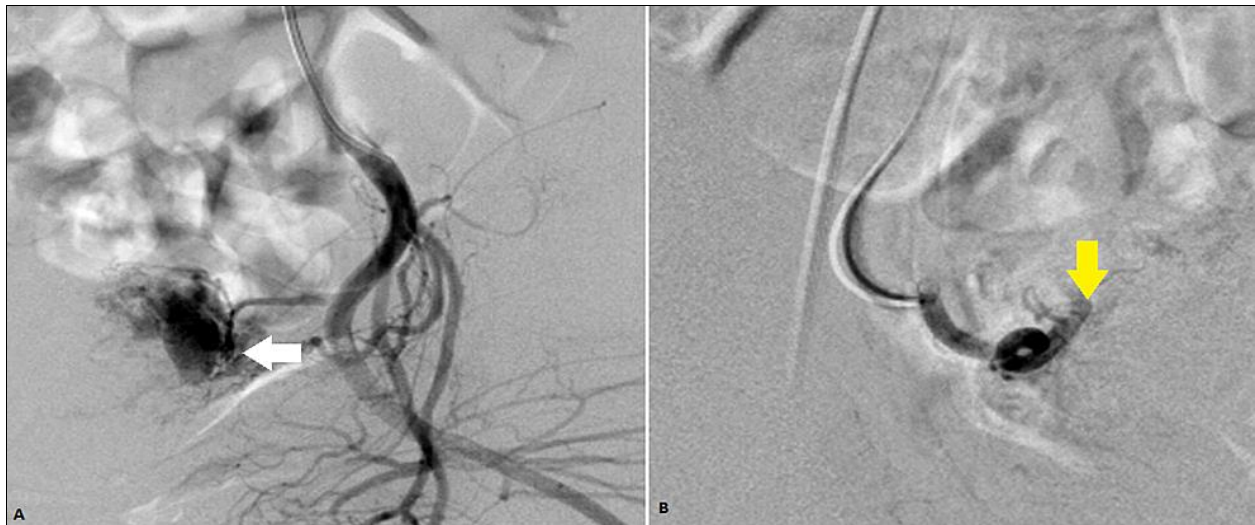


Figure-3: Angiogram of a 32-year-old female showing (A) AVM in the lower uterus with a 2 cm pseudoaneurysm (white arrow) supplied by left OA and bilateral UAs. (B) Successful PVA embolisation of AVM (yellow arrow), with flow stasis in the arterial supply. OA-ovarian artery, UA-uterine artery.

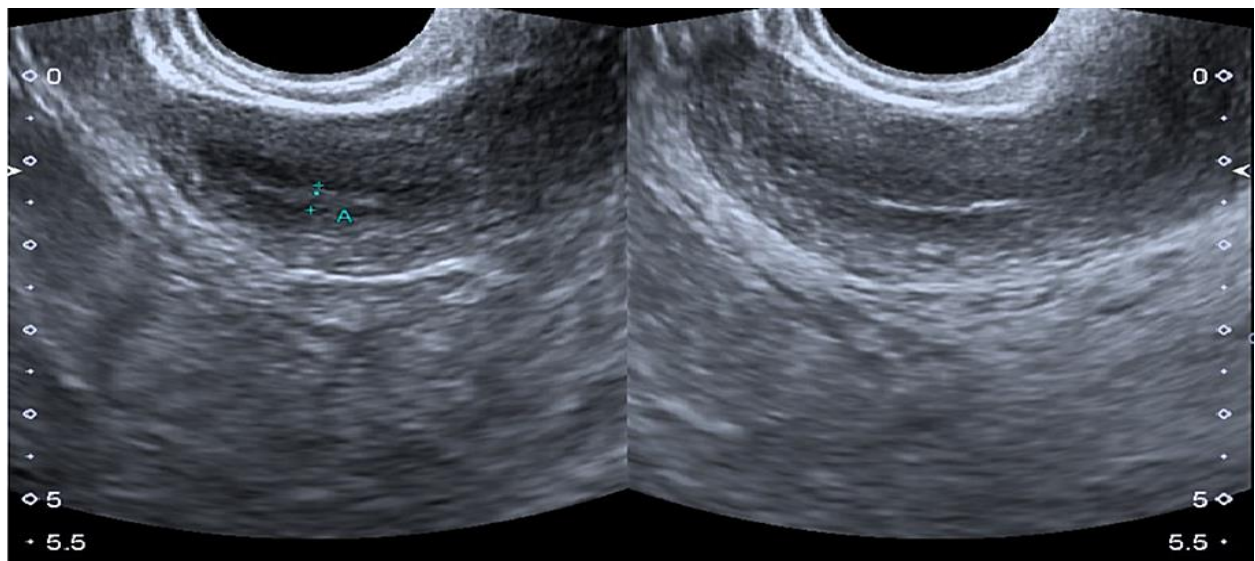


Figure-4: Follow-up USG of the same patient as Figure-1 at two months interval, showing complete resolution of uterine AVM and smooth endometrium of normal thickness.

DISCUSSION

It is not common to see uterine vascular anomalies in clinical practice; once acquired, it is further difficult to determine how it will behave clinically.^{5,6} In our experience, patients presented within few weeks to several months' duration following the intervention. These anomalies can cause potentially life-threatening haemorrhages and are most frequently found in females of childbearing age.^{6,7} Uterine AVMs are typically acquired, usually iatrogenic or post-traumatically, such as arteriovenous fistulae, which develop secondary to trauma, such as dilatation and curettage. These appear on imaging as a tortuous bunch of vessels having an abnormal communication of artery and vein, showing early venous filling.^{4,5} In contrast, uterine artery pseudoaneurysms occur because of focal injury to the muscular layer of the vessel wall, sparing the adventitia resulting in extravasation of blood and pooling, making an outpouching called the pseudoaneurysm sac contained by a thin, fragile layer of cells.^{1,8}

Acquired uterine vascular abnormalities can be attributed to various factors, including the previous history of caesarean section, dilatation and curettage, gestational trophoblastic disease, pelvic malignancies, and infection. In our patient cohort, all cases had a history of recent dilatation and curettage. Molar pregnancy was among the etiological factors in three out of our eight patients (Table-1). The most frequent methods for diagnosing these entities are CT (Figure.1) and MRI (Figure.2), which might be used to identify these lesions; however, sonographic examination with Doppler can also be used as an initial modality of choice.⁹ It is an inexpensive, easily accessible, and non-invasive procedure that saves time in case of emergency. On greyscale ultrasound, heterogenous uterine myometrium, bulky due to post-partum state and distended endometrium may be seen with fluid or blood products.¹⁰ Uterine AVMs and AVFs appear as focal or large anechoic serpiginous structures which show extensive vascularity with Colour doppler. A high-velocity low resistance waveform with arterialised blood flow is seen with turbulence indicated by colour aliasing in AVMs.^{10,11} Typically, the ying yang sign with the mixing of arterial and venous waveforms are reported in pseudoaneurysms.¹² CT angiography is generally preferred to rule out active haemorrhage, especially in the emergency presentation of these patients with massive blood loss.⁴ CT angiography also provides efficient details of vascular anatomy where time is of essence and swift decision-making regarding patient management is required. Nevertheless, MRI provides an excellent field of view and delineates the anatomy of local pelvic structures with far better resolution and is invaluable in detecting concurrent pathologies.⁸ The use of dynamic MRI with angiography also provides the road map for interventional

radiologists for devising the course of action required to achieve the embolisation procedure.⁹

RPOCs and GTP is usually the more prevalent etiological cause behind vaginal bleeding especially in the post-partum state; imaging features do not have any distinctive characteristics to differentiate them from uterine AVMs.^{13,14} However, negative serum B hCG levels combined with imaging findings can confidently exclude RPOCs and GTP from the differential list.⁴

Although digital subtraction arteriography is the gold standard for diagnosing these vascular malformations, it is not used merely for diagnostic purposes; it is also considered if curative intervention is required.¹⁴⁻¹⁶ The first case report addressing molar pregnancy-related uterine arteriovenous fistula with therapeutic UAE was published in 1985;¹³ since then, several successful bilateral uterine artery embolisation for uterine AVMs have been described, and therapeutic embolisation is the norm now. UAE is preferred over open surgical repair because it is less invasive, can be performed in local anaesthesia, and results in less frequent blood loss.^{10,11} Although these can be followed once diagnosed, embolisation is generally performed to preserve fertility, as these occur in childbearing age.¹²

Our review showed that UAE is most often selective and targets the arterial feeding supply, including one or both uterine arteries and/or ovarian arteries (Figure-3A and B). Because there is always a risk of recurrence with unilateral embolisation, and as we have reported in our article, a bilateral procedure seems advisable. However, adequate haemostasis may also be achieved with the help of a super-selective unilateral UAE procedure. Also, with particulate matter, it is possible to occlude any additional small collateral vessels feeding into the AVM simultaneously. Nevertheless, the contralateral side must always be checked by internal iliac arteriography to ensure technical success and avoid any perfusion to the vascular abnormality which was missed previously.¹⁷ These vascular injuries need special attention to the patient history so management can be permuted on a case-to-case basis for all purposes. Among the various embolic agents described in the literature, no specific agent has been advocated to treat these acquired uterine vascular abnormalities. In the literature review, Matsubara *et al.*² and Khan S *et al.*⁴ reported the use of gelfoam, Chen Li *et al.*³ used histoacryl glue, and Boi *et al.*⁷ described a combination of PVA and micro-coils in their patient. Ghai S *et al.*⁵ describe glue as the most effective agent for permanent embolisation and reserve the use of gelfoam for temporary control of haemorrhage. They suggest PVA particles for cases where a specific feeder to AVM cannot be identified and the whole vessel must be embolised, while micro-coils to employed where distal vessel protection is the objective. In our recent three cases, we also used a combination of histoacryl glue with lipiodol to achieve embolisation, Figure-3B. Following

UAE within one year, two of our patients conceived naturally; however, these conceptions could not follow through and resulted in miscarriages. In the post-AVM embolisation period, spontaneous abortion and growth retardation is seen due to embolisation of the normal uterine myometrial vessels resulting in abnormal placental development feto-maternal exchanges.^{1,18} Experts generally agree that the embolisation should be as hyper-selective as possible to barricade the feeding AVM while preserving normal vasculature to maintain the obstetric outlook, hence conserving fertility.^{7,8,19} In theory, one can develop secondary amenorrhea due to embolisation of the ovarian arteries, though it has not been reported.^{12,20} None of the patients in our cohort developed amenorrhea in their follow-up.

In our experience, UAE is a safe answer to treating acquired vascular abnormalities with a minimally invasive approach, reduced hospital stays, and almost zero to none post-procedural complications.

CONCLUSION

Acquired/iatrogenic uterine vascular abnormalities are a rare but important cause of life-threatening haemorrhage. Given the uncommon occurrence of these vascular pathologies, a high index of suspicion is required for diagnosis. However, these uterine vascular abnormalities can be expertly managed and successfully treated using UAE, a rapid, safe, and minimally invasive treatment option with the added advantage of fertility preservation.

Conflict of interest: Authors declare no conflict of interest.

Disclosure: Authors declare no disclosures.

Disclaimer: The abstract of this paper has been presented as an oral presentation in ECR 2021, Vienna.

AUTHORS' CONTRIBUTION

LM conceived the study design, drafted the manuscript and compiled the cases. ZAK participated in drafting, critical revision of manuscript and case collection. MSA drafted the manuscript. AIR conceived the study idea, participated in its design /coordination and case collection as well as critical revision of manuscript. HA helped in case compilation. All authors have read and approved the final version of the manuscript.

REFERENCES

1. Koethe Y, Boone C, Lehrman ED, Kolli KP, Kumar V, Kohi MP. Uterine artery embolisation as a uterine-sparing solution for post-partum pseudoaneurysms. *J Gynecol Surg* 2019;35(3):136-9.
2. Matsubara S, Takahashi Y, Kawai A. Uterine artery pseudoaneurysm manifesting at the time of evacuation for abortion:

- pseudoaneurysm without preceding events. *Acta Obstet Gynecol Scand* 2014;93(7):723-4.
3. Chen LK, Yang BL, Chen KC, Tsai YL. Successful transarterial embolisation of uterine arteriovenous malformation: report of three cases. *Iran J Radiol* 2016;13(1):e15358.
4. Khan S, Saud S, Khan I, Achakzai B. Acquired Uterine Arteriovenous Malformation Following Dilatation and Curettage Treated with Bilateral Uterine Artery Embolization: A Case Report. *Cureus* 2019;11(3):e4250.
5. Ghai S, Rajan DK, Asch MR, Muradali D, Simons ME, TerBrugge KG. Efficacy of embolisation in traumatic uterine vascular malformations. *J Vasc Interv Radiol* 2003;14(11):1401-8.
6. Wang Z, Chen J, Shi H, Zhou K, Sun H, Li X, *et al.* Efficacy and safety of embolisation in iatrogenic traumatic uterine vascular malformations. *Clin Radiol* 2012;67(6):541-5.
7. Boi L, Savastano S, Beghetto M, Dall'Acqua J, Montenegro GM. Embolization of iatrogenic uterine pseudoaneurysm. *Gynecol Minim Invasive Ther* 2017;6(2):85-8.
8. Nanjundan P, Rohilla M, Raveendran A, Jain V, Khandelwal N. Pseudoaneurysm of uterine artery: a rare cause of secondary post-partum hemorrhage, managed with uterine artery embolisation. *J Clin Imaging Sci* 2011;1:14.
9. Chen C, Lee SM, Kim JW, Shin JH. Recent update of embolisation of post-partum hemorrhage. *Korean J Radiol* 2018;19(4):585-96.
10. Kelly SM, Belli AM, Campbell S. Arteriovenous malformation of the uterus associated with secondary post-partum hemorrhage. *Ultrasound Obstet Gynecol* 2003;21(6):602-5.
11. Comette J, van der Wilk E, Janssen NM, van der Weiden RM, Jenninkens SF, Pattynama P, *et al.* Uterine artery pseudoaneurysm requiring embolisation during pregnancy. *Obstet Gynecol* 2014;123(2):453-6.
12. Müngen E, Yergök YZ, Ertekin AA, Ergür AR, Uçmaklı E, Aytacılar S. Color Doppler sonographic features of uterine arteriovenous malformations: report of two cases. *Ultrasound Obstet Gynecol* 1997;10(3):215-9.
13. Chapman DR, Lutz MH. Report of a successful delivery after nonsurgical management of a choriocarcinoma-related pelvic arteriovenous fistula. *Am J Obstet Gynecol* 1985;153(2):155-7.
14. Beller U, Rosen RJ, Beckman EM, Markoff G, Berenstein A. Congenital arteriovenous malformation of the female pelvis: a gynecologic perspective. *Am J Obstet Gynecol* 1988;159(5):1153-60.
15. Delotte J, Chevallier P, Benoit B, Castillon JM, Bongain A. Pregnancy after embolisation therapy for uterine arteriovenous malformation. *Fertil Steril* 2006;85(1):228.
16. Bradley EA, Reidy JF, Forman RG, Jarosz J, Braude PR. Transcatheter uterine artery embolisation to treat large uterine fibroids. *Br J Obstet Gynaecol* 1998;105(2):235-40.
17. Farias MS, Santi CC, Lima AA, Teixeira SM, Biase TC. Radiological findings of uterine arteriovenous malformation: a case report of an unusual and life-threatening cause of abnormal vaginal bleeding. *Radiol Bras* 2014;47(2):122-4.
18. Kim T, Shin JH, Kim J, Yoon HK, Ko GY, Gwon DI, *et al.* Management of bleeding uterine arteriovenous malformation with bilateral uterine artery embolisation. *Yonsei Med J* 2014;1;55(2):367-73.
19. Khan AN, Gul N, Umer US, Alam S, Ghaus SG, Sohail Z, *et al.* Embolisation of uterine arteriovenous malformation with successful post procedure pregnancy. *Pak J Radiol* 2019;25;29(2):137-41.
20. Cura M, Martinez N, Cura A, Dalsaso TJ, Elmerhi F. Arteriovenous malformations of the uterus. *Acta Radiol* 2009;50(7):823-9.

Submitted: May 31, 2021

Revised: September 21, 2021

Accepted: October 31, 2021

Address for Correspondence:

Dr. Laiba Masood, Pitras Bukhari Rd, H-8, Islamabad-Pakistan.

Email: laibamasood66@gmail.com