

## ORIGINAL ARTICLE

## MODIFIED TREATMENT OF SHALLOW FORNIX FOR BETTER RETENTION OF OCULAR PROSTHESIS

Zeeshan Kamil, Qirat Qurban, Muhammad Tanweer Hassan Khan

Khalid Eye Hospital, Karachi-Pakistan

**Background:** The purpose of this study is to share the experience of a modified surgical technique for treating shallow inferior fornix to enhance the retention of cosmetic ocular prosthesis in a tertiary care hospital. It was a Quasi experimental study, carried out at Khalid Eye Hospital, Karachi, Pakistan from January to December 2018. **Methods:** This study included twenty-five patients between the ages of 20–40 years belonging to either gender having an anophthalmic socket with shallow inferior fornices unable to retain cosmetic ocular prosthesis. Three pieces of Silicone tube were placed deep within the inferior fornix with the help of 2–0 Vicryl suture, taking bite of the inferior orbital rim periosteum. Main outcome measure was deepening of the inferior fornix with better retention of the ocular prosthesis. All the patients were followed up for a period of one year after the surgery. Study dynamics were briefed to all the patients and study approval obtained from the hospital ethical review committee. **Results:** This study included a total of twenty-five patients of both genders. Mean age was  $29.6 \pm 6.53$  years. By the end of the follow up period, twenty-four (96%) out of the twenty-five patients were satisfied with a proper retention of ocular prosthesis within the fornix along with complete lid closure. One (4%) patient required revision surgery because of extrusion of the silicone tube piece after one month. Mean follow up period was  $358.5 \pm 16.76$  days. **Conclusion:** This modified technique does not require expensive consumables and proved to be effective in terms of cosmetic and functional outcome.

**Keywords:** Ocular prosthesis; Shallow fornix; Enucleation; Evisceration.

**Citation:** Kamil Z, Qurban Q, Khan MTH. Modified Treatment of shallow fornix for better retention of ocular prosthesis. J Ayub Med Coll Abbottabad 2022;34(3 Suppl. 1):682–5.

DOI: 10.55519/JAMC-03-S1-9934

## INTRODUCTION

An adequate fornical depth is essential for the placement of an ocular prosthesis in an anophthalmic socket for the maintenance of an aesthetically appealing facial appearance since the face and especially the eyes hold great significance when communicating nonverbally and while expressing oneself. A number of studies have focused on the psychosocial impact of losing an eye or an improper fitting of an ocular prosthesis.<sup>1–3</sup> Eyes may be lost either due to trauma, infections, iatrogenic or congenital reasons. An ocular prosthesis is then applied as a replacement in an anophthalmic socket. Wearing an ocular prosthesis is associated with the nuisance of altered visual sensitivity as well as mucoid discharge.<sup>4</sup>

In 1973, Vistnes and Iverson, described that a large defect and volume loss accompanies evisceration or enucleation followed by a contracted socket weeks to years after the surgical procedures.<sup>5</sup> Healing takes place by the commencement of an individual's innate immunity characterized by an acute phase inflammation with subsequent formation of intermediate phase granulation tissue and then scar tissue formation in the long run owing

to the release of certain growth factors (chemokines, cytokines and mediators).<sup>6</sup> Later on conjunctival healing results in scarring within an anophthalmic socket leading to relentless impairment of anatomical, functional and cosmetic outcome with consequent inadequate fornical depth making it inept of retaining an ocular prosthesis. Sufficiently deep inferior fornix together with an ample length and depth of conjunctiva is required in order to grasp the ocular prosthesis in place within an anophthalmic socket.<sup>7</sup> Such an adequate fornical depth can be attained by an increment of the surface area with the utilization of grafts such as amniotic membrane, buccal mucosa, conjunctival or tarsal grafts whereas shallow fornix in an anophthalmic socket can be made deep with the help of separation of bands followed by placing deepening sutures or fascia lata strips within the fornices.<sup>8–10</sup>

This present study shares a modified surgical technique for deepening the shallow inferior fornix with a better retention of the ocular prosthesis in anophthalmic contracted sockets.

## MATERIAL AND METHODS

This study was carried out in the ophthalmology department at Khalid Eye Hospital, Karachi, Pakistan

from January to December 2018. This study included twenty-five patients between the ages of 20–40 years of either gender having anophthalmic sockets with shallow inferior fornices following previous evisceration and enucleation surgical procedures and unable to retain cosmetic ocular prosthesis. Patients less than 20 years or more than 40 years, previous surgical correction for shallow inferior fornix and those having prior history of bleeding diathesis were excluded from the study. Study dynamics were briefed to all the patients and informed consent obtained. Study approval was taken from the hospital ethical review committee. Main outcome measure was deepening of the inferior fornix with better retention of the ocular prosthesis. Pre and post forniceal depth measurements in the centre were taken in both eyes under topical anaesthesia, using a thin dimensioned noninvasive, round edged fine plastic ruler having millimeter markings and each patient was followed for a duration of 12 months after the operation to observe for the cosmetic appearance, maintenance of forniceal depth and retention of ocular prosthesis.

Data was analyzed using SPSS statistical program version 25. Frequencies of age, gender and laterality were calculated.

All the procedures were performed under general anaesthesia by a single oculoplastic surgeon (ZK). The subconjunctival fibrous scar tissue was incised using No. 11 blade and dissected using Wescott scissors to separate the bands and liberate the forniceal adhesions. Fornix deepening incision was made along the entire length of the lower lid and deepened down to the periosteum. The required fornix depth was calculated and compared with the normal fellow eye in all the patients.

Three 2-0 Vicryl sutures were passed at medial, centre and lateral part of the lower lid from within the inferior fornix taking bite of the inferior orbital rim periosteum and coming out from the skin and then again going back from the skin, taking a bite of the inferior orbital rim periosteum and coming out from within the inferior fornix followed by introduction of three pieces of Silicone tubes into each suture which were placed deep within the inferior fornix with the help of 2-0 Vicryl suture and tied creating a deep lower lid pocket. (Figure-1) This was followed by the placement of adequately sized ocular prosthesis within the fornices to prevent any post surgical scarring and fibrosis among all the patients. (Figure-2,3,4) The post surgical treatment comprised of oral antibiotics and analgesics for 7 days along with antibiotic steroid eye drops. The total follow up period for this study was twelve months during which the patients were observed for the maintenance of a

deep fornix and presence of any complications. The surgical success was taken as reconstruction of an anatomically deep fornix with cosmetically appealing retention of the ocular prosthesis. Failure was defined as recurrence or inability to retain the ocular prosthesis.

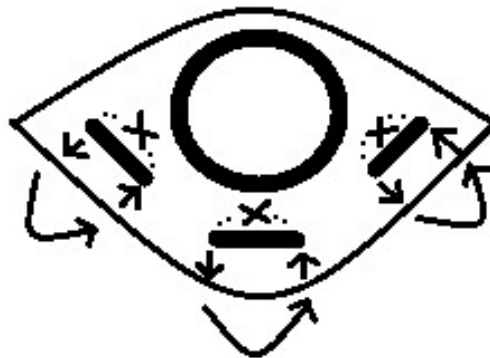


Figure-1: Drawing of the suture paths and silicone tubes placement

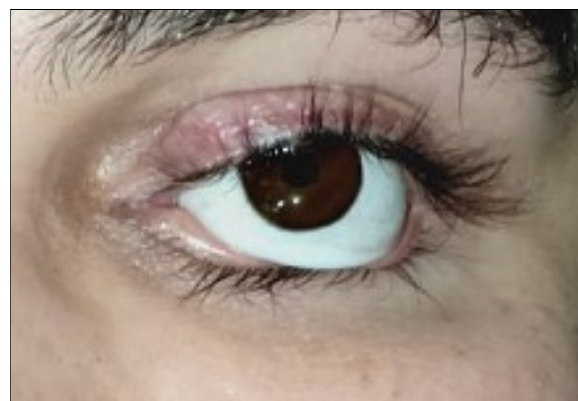

Figure-2: Improperly fitted ocular prosthesis

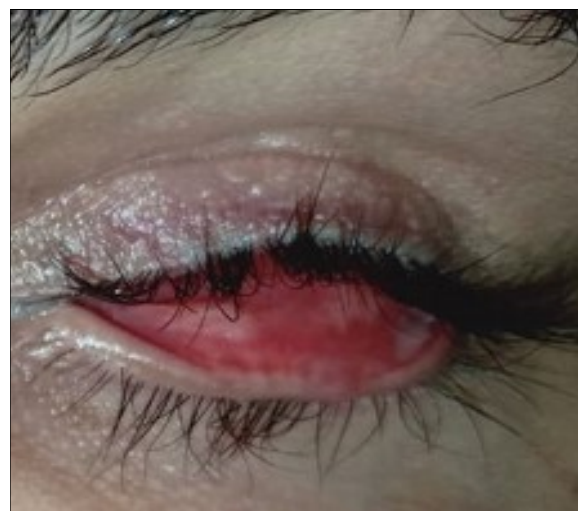
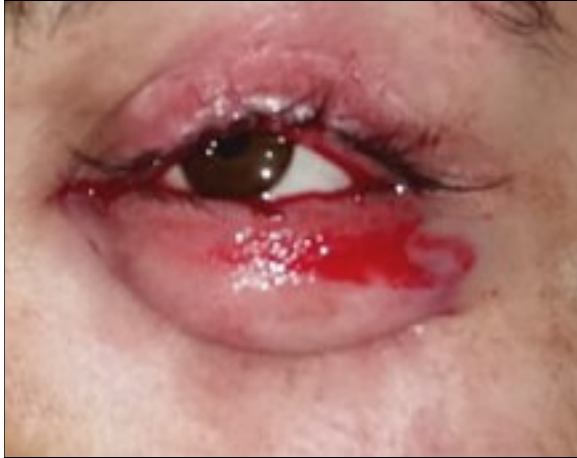
Figure -3: Contracted anophthalmic socket with shallow fornix



**Figure-4: Silicone bolsters within the inferior fornix with formation of the lower lid sulcus and ocular prosthesis in place**

## RESULT

This study included a total of twenty-five patients of both genders. Out of the twenty-five patients, nine (36%) were females and sixteen (64%) were males. Mean age was  $29.6 \pm 6.53$  years. Right socket was involved in sixteen (64%) cases whereas left socket was involved in nine (36%) cases. Seventeen (68%) patients had a history of previous evisceration whereas eight (32%) patients had undergone enucleation many years ago. By the end of the follow up period, twenty-four (96%) out of the twenty-five patients were satisfied with a proper retention of ocular prosthesis within the fornix along with complete lid closure. One (4%) patient required revision surgery because of extrusion of the silicone tube piece after one month. This patient had previously undergone enucleation. Only two (8%) patients developed cutaneous granuloma within two months, which was excised. None of the patients complained of heaviness or foreign body sensation. Chi squared test was applied on success rate and previous procedure ( $p$ -value = 0.32). Mean follow up period was  $358.5 \pm 16.76$  days.

## DISCUSSION

The pocket within the eyelids is called a fornix and ocular prosthesis is placed within this pocket following evisceration or enucleation surgical procedure. A contracted shallow fornix in an anophthalmic socket may cause the ocular prosthesis to pop out resulting in inconvenience for the patient as well as considerable social embarrassment. The treatment for shallow fornix depends upon the basic cause. An anophthalmic socket is deprived of a globe leading to obliteration of the inferior fornix owing to the

migration of the orbital fat tissue anteriorly together with a higher level of inferior rectus muscle, lower lid retractors and the forniceal conjunctiva causing prolapse and anterior displacement of the inferior part of the ocular prosthesis.<sup>11</sup> Literature describes various strategies of deepening and reconstructing the inferior fornix in anophthalmic sockets. In order to sustain and deepen the inferior fornix, deepening sutures can be applied.<sup>12</sup> Conjunctival, auricular cartilage, scleral, oral or nasal mucosal grafts have also been used as a substitute for the reconstruction and maintenance of inferior fornix.<sup>9,11,13,14</sup> Nasal mucosal grafts have an added benefit of having goblet cells but may contract in the long run.<sup>9</sup> Oral mucosal grafts may result in fetid smelling discharge and contraction over time.<sup>15</sup> Amniotic membrane grafts are another way of reconstructing the inferior fornix in order to retain the ocular prosthesis but due to restricted accessibility and longer surgery time makes it unfeasible.<sup>8,16</sup> Fascia lata strips have also been used to deepen the shallow inferior fornix in anophthalmic sockets but necessitates a donor site and has risk of complications.<sup>10</sup> The eventual aim of management is to allow the ocular prosthesis to stay in place and resemble the fellow eye as much as possible as an improper fitting prosthesis can be psychologically disturbing for an individual.<sup>3</sup>

A modified surgical technique was performed in the present study by applying 3 sutures from within the fornix centrally, medially and laterally, full thickness through the lower eyelid taking the inferior orbital rim periosteum in the suture bite together with closure of the fornix sutures with silicone tube bolsters. The depth of the silicone tube bolsters and the sutures was determined by the degree of shallowness and contraction of the lower lid keeping in mind the comparison with fellow eye to create a similar inferior lid sulcus on both sides in order to retain the ocular prosthesis as well as aesthetic purposes. The advantage of this modified technique is that the silicone tubes are inert; cause no reaction or contraction over time. Also, the sutures used were absorbable Vicryl 2-0. No expensive consumables were required for this procedure and required less surgical time along with absence of an additional donor site since silicone tubes are widely available. This modified technique had a 96% success rate with minimal risk of complication; whereas other studies reported a 93.3% success rate with fascia lata strips<sup>10</sup>, 83.33% success rate with amniotic membrane grafts<sup>8</sup> and 77.3% with oral mucosal grafts<sup>9</sup>. Since, the silicone bolsters are placed within the fornix, they are cosmetically acceptable for the patient as well.

## CONCLUSION

This modified surgical technique for the formation and maintenance of inferior fornix in anophthalmic sockets does not require expensive consumables and proved to be a safe and effective alternative in terms of establishing the functional as well as cosmetic outcome.

## AUTHORS' CONTRIBUTION

ZK: Primary surgeon, manuscript writing.  
 QQ: Manuscript writing, data acquisition and analysis.  
 MTHK: Data analysis, post intervention management.

## REFERENCES

1. McBain HB, Ezra DG, Rose GE, Newman SP. The psychosocial impact of living with an ocular prosthesis. *Orbit* 2014;33(1):39–44.
2. James H, Jenkinson E, Harrad R, Ezra DG, Newman S. Appearance concerns in ophthalmic patients. *Eye (Lond)* 2011;25(8):1039–44.
3. Clarke A, Rumsey N, Collin JR, Wyn-Williams M. Psychosocial distress associated with disfiguring eye conditions. *Eye (Lond)* 2003;17(1):35–40.
4. Pine KR, Sloan BH, Jacobs RJ. *Clinical Ocular Prosthetics*. New York: Springer. 2015.
5. Iverson RE, Vistnes LM, Siegel RJ. Correction of enophthalmos in the anophthalmic orbit. *Plast Reconstr Surg* 1973;51(5):545–54.
6. Tseng S, Espana E, Kawakita T. How does amniotic membrane work? *Ocul Surf* 2004;2(3):177–87.
7. Neuhaus R, Hawes M. Inadequate inferior cul-de-sac in the anophthalmic socket. *Ophthalmology* 1992;99(1):153–7.
8. Thatte S, Jain J. Fornix reconstruction with amniotic membrane transplantation: A cosmetic remedy for blind patients. *J Ophthalmic Vis Res* 2016;11(2):193–7.
9. Mai C, Bertelmann E. Oral Mucosal Grafts: Old Technique in New Light. *Ophthalmic Res* 2013;50(2):91–8.
10. Ibrahim MF, Abdelaziz ST. Shallow Inferior Conjunctival Fornix in Contracted Socket and Anophthalmic Socket Syndrome: A Novel Technique to Deepen the Fornix Using Fascia Lata Strips. *J Ophthalmol* 2016;2016:3857579.
11. Collin JR. *A Manual of Systematic Eyelid Surgery*, Elsevier, Philadelphia, Pa, USA, 3rd ed. 2006.
12. Heinz GW, Nunery WR. Anophthalmic socket: evaluation and management. In: McCord CD, Tanenbaum M, editors. *Oculoplastic surgery*. 3rd ed. New York: Raven Press, 1995; p.609–37.
13. Tawfik HA, Raslan AO, Talib N. Surgical management of acquired socket contracture. *Curr Opin Ophthalmol* 2009;20(5):406–11.
14. Smith RJ, Malet T. Auricular cartilage grafting to correct lower conjunctival fornix retraction and eyelid malposition in anophthalmic patients. *Ophthalmic Plast Reconstr Surg* 2008;24(1):13–8.
15. Wojno T, Tenzel RR. Dermis grafts in socket reconstruction. *Ophthalmic Plast Reconstr Surg* 1986;2(1):7–14.
16. Pooyathalang A, Preechawat P, Pomsathit J, Mahaisaviriya P. Reconstruction of contracted eye socket with amniotic membrane graft. *Ophthalmic Plast Reconstr Surg* 2005;21(5):359–62.

*Submitted: August 3, 2021*

*Revised: September 1, 2021*

*Accepted: October 31, 2021*

## Address for Correspondence:

**Zeeshan Kamil**, Khalid Eye Hospital, Nazimabad No. 4, Karachi-Pakistan

**Cell:** +92 334 303 8028

**Email:** dr.zeeshankamil@yahoo.com