

CASE REPORT

VON HIPPEL LINDAU SYNDROME AND SURVEILLANCE: A FIVE YEAR FOLLOW UP CASE REPORT

Muhammad Junaid, Mamoon Ur Rashid, Afeera Afsheen, Ayesha Tahir, Mamoon Ahmad, Anisa Kalsoom

Combined Military Hospital, Peshawar, Khyber Teaching Hospital, Peshawar, Army Medical College, Rawalpindi, Fauji Foundation Hospital Rawalpindi-Pakistan

Von Hippel Lindau disease is a rare genetic autosomal dominant disorder, characterized by formation of tumors and fluid-filled cysts (sacs) in multiple organs of the body, which also carry a potential for malignancy. We are reporting a case of a young 20 years old female who presented to our department with von Hippel Lindau disease.

Keywords: VHL syndrome, Cerebello-Retinal angiomatosis, Hemangioblastoma

J Ayub Med Coll Abbottabad 2015;27(4):930-2

INTRODUCTION

Von Hippel Lindau disease, also known as Von Hippel Lindau Syndrome is a rare genetic autosomal dominant disorder, characterized by formation of tumours and fluid-filled cysts (sacs) in multiple organs of the body, which also carry a potential for malignancy. It occurs due to mutation in VHL gene on chromosome 3p25.

Tumours involving other organs and the CNS (brain, spinal cord) are present in 25% of patients with VHL disease.¹ One of the characteristic tumours which appears in young adulthood in this disease is hemangioblastoma. These are non-cancerous and consist of newly formed blood vessels. Hemangioblastomas may cause cord compression which can manifest as sensory and motor loss. Hemangioblastomas can occur in the retina and here are known as retinal angiomas which may lead to vision loss.² In addition, patients with retinal angiomas have a 25% risk of developing CNS hemangioblastomas, primarily in the cerebellum.³

CASE REPORT

A 20 years old female presented with complaints of difficulty walking, uncoordinated movements, decreasing consciousness and headache for two months. Family history revealed that her father was suffering from VHL disease. After complete assessment and neurological examination an impression of compressive myelopathy was made. Magnetic Resonance Imaging (MRI) of spine and brain was done which revealed mass in the cerebellar region (figure-1) with prominent cystic component along with a peripheral nodule which showed significant contrast enhancement and peritumoral oedema. MRI abdomen was also done to detect any cysts or tumours but none of them were found. Fundoscopic examination was done which was negative for retinal angiomas however bilateral papilloedema was seen. Complete surgical resection

of the tumour was done. Post-operatively patient symptoms improved.

She was advised to have regular follow up (Figure-3). MRI brain, spinal cord and abdomen were carried yearly. During the 5th year of her follow up, the existence of another metachronous tumour (Figure-4) in the cervical part of spinal cord was seen. She is now complaining of numbness in both hands at present time but she has not yet consented for the cervical cord tumour removal. She is closely followed for the tumours that may arise and are associated with VHL syndrome.

The patient was placed in semi-prone Park Bench position on right side with the head maximally flexed. After positioning and induction of general anaesthesia the patients' skull was fixated in place. A midline Suboccipital Craniectomy was performed, and the posterior fossa opened with a Y-shaped incision. The arachnoid was opened and retracted to the edges.

Using an operating microscope the tumour and associated vessels were identified. After defining the tumour surface and adjacent cerebellar tissue, the hemangioblastoma was resected carefully and meticulously by dissection at the tumour-cerebellar tissue interface. All the vessels in the area were carefully coagulated to keep better visualization and prevent excessive bleeding.

After resection of the tumor, the cyst wall was inspected entirely for any additional cysts or lesions but no additional peritumoral cysts or lesions found. The resection of the hemangioblastoma was completed. Perioperatively dexamethasone wash was done to prevent chemical meningitis. The meninges were sutured closed and cranial cavity was closed in layers. Post operatively patient symptoms improved.

Postoperative period was uneventful and no neurological symptoms or signs developed. Postoperative CT scan (Figure-2) showed no lesions or haemorrhage in the cerebellar region. No event of

meningitis or hydrocephalus was recorded in 5 year follow up. Histopathology confirmed the diagnosis, cerebellar Hemangioblastoma.

Follow up surveillance with MRI brain, spinal cord and abdomen was done, no recurrence of tumour was noted in cerebellum however another metachronous tumour (Figure-4) was seen in the cervical cord during five year follow up. For the first year postoperatively, surveillance was done at 6 monthly interval and then yearly for recurrence and metachronous tumours. Histopathology revealed cerebellar hemangioblastoma.

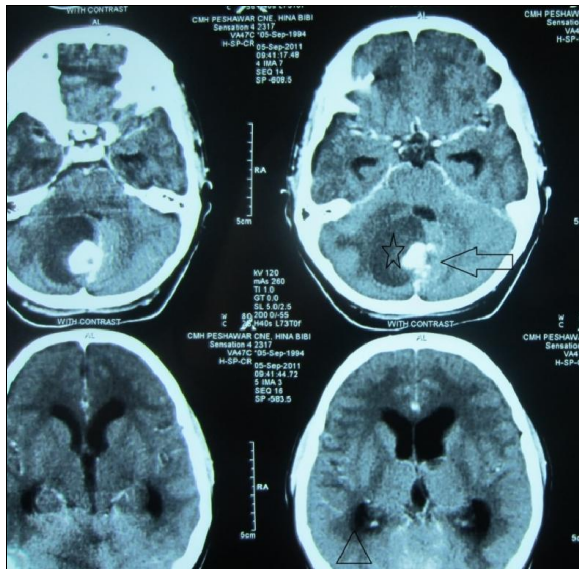


Figure-1: Pre-op CT scan with contrast shows mural nodule (arrow) with contrast enhancement and cystic component (asterisk). Dilated bilateral temporal horns (arrow head) are visible due to 4th ventricle obstruction

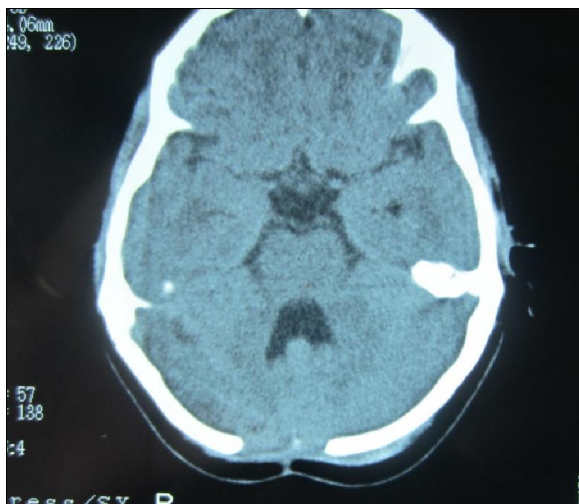

Figure-2: Immediate Post-operative CT scan. Cranial defect (arrow) can be seen with no evidence of tumour and normal location of 4th ventricle after tumour resection

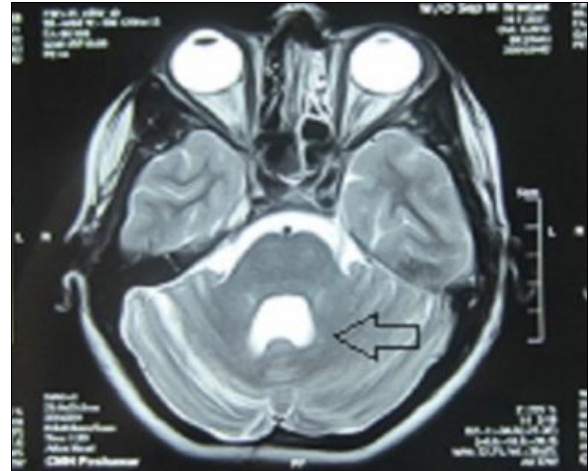


Figure-3: Follow up surveillance MRI at 12 months from tumour resection . No evidence of recurrence or metachronous tumour can be seen. 4th ventricle (arrow) is in normal anatomical position

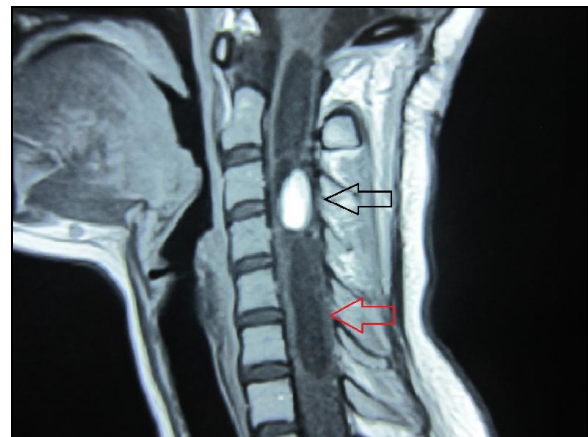


Figure-4: Metachronous tumour in the cervical spine, on follow up surveillance MRI, after 5 years of cerebellar hemangioblastoma resection. Mural nodule with contrast enhancement (black arrow) and cystic component (red arrow) are clearly visible.

DISCUSSION

In Von Hippel Lindau Syndrome, retinal and CNS tumours are the most frequent manifestations occurring in 70% and 84% respectively by the age of 60.⁴ The characteristic hemangioblastomas appearing in young adulthood are primarily non-cancerous growths, made up of newly formed blood vessels. These hemangiomas when becomes symptomatic leads to clinical presentation of patients complaining of loss of coordination, difficulty in movements, headache and vomiting. Hemangioblastomas compressing the cord may lead to sensory or motor loss and those occurring in retina causes vision loss.⁵ As Von Hippel Lindau is a multiorgan disease varying in its clinical presentation, Melmon and Rosen in 1964 [6] proposed criteria for the diagnosis of the disease; 1). More than 1

hemangioblastoma in the CNS or retina, 2). A single hemangioblastoma in the CNS or retina along with a visceral manifestation, 3). Positive family history along with any of the above manifestations, 4). Proof of a deleterious mutation in the VHL gene. Based on genotype-phenotype, VHL is divided into two types. VHL type-1, which involves deletion or truncation mutations, is characterized by retinal and CNS hemangioblastomas and renal cell carcinoma.⁷ VHL type 2 usually involves a missense mutation which encodes a protein with limited activity and may also involve pheochromocytoma. The mutations are highly penetrating, as almost all individuals have the mutations, express the associated symptoms by age of 65.⁸

As was in our patient, CNS hemangioblastomas are commonly present accounting for 84% of the cases⁹ occurs in cerebellum, midbrain and spinal cord. These tumours arising from mesodermal hemangioblast consist of polygonal stromal cells enmeshed in capillary network and stromal cells. They are usually benign but tend to enlarge over time but the growth rate is hugely variable and hence asymptomatic static tumours are usually not removed.⁵ On histological¹⁰ and radiological¹¹ basis the cerebellar hemangioblastomas are classified into four types; Type-1 is a simple cyst without any macroscopic nodule (5%). Type-2 is a cyst with a mural nodule (60%). Type-3 are solid tumours (26%). While type-4 are solid tumours with small internal cysts (9%). Retinal hemangioblastomas (RHb) is seen in 45–59% of patients with VHL¹² and are the most commonly presenting feature of the disease. Most angiomas are treated with laser photocoagulation and cryotherapy but optic disc angiomas are not treated till there is evidence of progression, because the treatment may affect optic nerve.⁸ Renal cysts are present in 59–63% of individuals with VHL. Renal cell carcinoma (RCC) develops in 24–45% of VHL patients.¹² The renal involvement in VHL is multicentric and bilateral in atleast 75% of cases.¹³ Most commonly, the death of VHL disease patients is related to complications of cerebellar hemangioma and metastatic renal cell carcinoma. Individuals in families at risk for VHL should be informed and educated that genetic testing for VHL is available. American Society of Clinical Oncology (ASCO) recommends that genetic testing¹⁴ to be offered when 1). The individual has personal or family history features suggestive of a genetic cancer susceptibility condition, 2). The test can be adequately interpreted, and 3). The results will aid in diagnosis or influence the medical or surgical management of the patient or family members at

hereditary risk of cancer. These individuals should be motivated for early genetic screening to exclude the diagnosis and thus eliminate unnecessary clinical testing among those family members who are not carriers of the pathogenic gene variant.

CONCLUSION

Von hippel lindau disease is an autosomal dominant disorder due to chromosomal mutation on chromosome 3p25. It is inherited familial cancer syndrome predisposing to a variety of malignant and benign tumors. Once diagnosed proper follow up should be done. The various presentations of tumours and cyst should be explained to the patients and family. Being an autosomal dominant disorder there is 50% chance for every newborn child to have the disease as was proved in our case in which the daughter presented with the symptoms.

REFERENCES

- Huson SM, Harper PS, Hourihan MD, Cole G, Weeks RD, Compston DA. Cerebellar haemangioblastoma and von Hippel-Lindau disease. *Brain* 1986;109(Pt 6):1297–310.
- Gass JD, Braunstein R. Sessile and exophytic capillary angiomas of the juxtacapillary retina and optic nerve head. *Arch Ophthalmol* 1980;98(10):1790–7.
- Pavesi G, Feletti A, Berlucchi S, Opocher G, Martella M, Murgia A, *et al.* Neurosurgical treatment of von Hippel-Lindau-associated hemangioblastomas: benefits, risks and outcome. *J Neurosurg Sci* 2008;52(2):29–36.
- Maher ER, Webster AR, Moore AT. Clinical features and molecular genetic aspects of von Hippel Lindau disease. *Ophthalmic Genet* 1995;16(3):79–84.
- Von Hippel-Lindau Disease. Information about VHL Disease; Patient [Internet] [cited 2015 May 23]. Available from: <http://patient.info/doctor/von-hippel-lindau-disease>
- Melmon KL, Rosen SW. Lindau's disease. Review of the literature and study of a large kindred. *Am J Med* 1964;36:595–617.
- Frantzen C, Links T, Giles R. Von Hippel-Lindau Syndrome - GeneReviews® - NCBI Bookshelf [Internet] [cited 2015 May 23]. Available from: <http://www.ncbi.nlm.nih.gov/books/NBK1463/>
- Maher E, Neumann HP, Richard S. von Hippel-Lindau disease: A clinical and scientific review. *Eur J Hum Genet* 2011;19(6):617–23.
- Frantzen, Carljijn, Thera P. Links, Rachel H. Giles. "von Hippel-Lindau disease." 2012.
- Richard S, Campello C, Taillandier L, Parker F, Resche F. Haemangioblastoma of the central nervous system in von Hippel-Lindau disease. French VHL study group. *J Int Med* 1998;243(6):547–53.
- Lee SR, Sanches J, Mark AS, Dillon WP, Norman D, Newton TH. Posterior fossa hemangioblastomas: MR imaging. *Radiology* 1989;171(2):463–8.
- Maher ER, Yates JRW, Harries R, Benjamin C, Harris R, Moore AT, *et al.* Temporal Sequence. *QJ Med* 1990;77:51–63.
- Quadery FA, Okamoto K. Diffusion-weighted MRI of haemangioblastomas and other cerebellar tumours. *Neuroradiology* 2003;45(4):212–9.
- Pithukpakorn M, Glenn GM. "von Hippel-Lindau syndrome." *Community Oncology* 2004;1(4):232–3.

Address for Correspondence:

Dr. Mamoon ur Rashid, Khyber Teaching Hospital, Peshawar-Pakistan

Email: jkneuro@hotmail.com, mamoon3344@gmail.com