

ORIGINAL ARTICLE

RELIABILITY OF ORTHOPANTOMOGRAM IN COMPARISON TO LATERAL CEPHALOGRAM FOR LINEAR MANDIBULAR MEASUREMENTS

Asma Faryal, Attiya Shaikh

Liaquat College of Medicine and Dentistry, Karachi-Pakistan

Background: Mandibular asymmetries are commonly seen as asymmetric traits among orthodontic and orthognathic patients which require bilateral mandibular assessment for diagnosis and treatment. An orthopantomogram can be used to measure and compare right and left sides of mandible. The objective of this study was to investigate the reliability of left and right sides of orthopantomogram for determining the linear mandibular measurements and to check whether these values are identical with the values of linear mandibular measurements determined from lateral cephalogram. **Methods:** Orthopantomogram and lateral cephalogram were taken from 118 patients of age group 12–35 years from Orthodontic department, Liaquat College of Medicine & Dentistry and Darul Sehat Hospital, Karachi, Pakistan. Linear mandibular measurements were detected and compared between orthopantomograms and lateral cephalograms. Right and the left sides of orthopantomograms were compared for all of the linear mandibular parameters by using paired t-test. Independent sample t-test was performed for the comparison between orthopantomogram and lateral cephalogram using SPSS version 26.0. **Results:** Statistically significant differences were observed when orthopantomograms were compared with lateral cephalograms for mandibular body length ($p=0.000$) and total mandibular length ($p=0.000$). No statistically significant difference was found between orthopantomograms and lateral cephalograms for ramus height ($p=0.226$, $p=0.177$). Neither any significant difference was observed between right and left sides of an orthopantomogram. **Conclusion:** An orthopantomogram can be used to evaluate vertical mandibular measurements as reliably as a lateral cephalogram. However, it is required for clinicians to be vigilant when determining horizontal mandibular measurements from orthopantomograms as they are unpredictable.

Keywords: Orthopantomogram; OPG; Lateral cephalogram; Linear mandibular measurements; Mandibular asymmetry

Citation: Faryal A, Shaikh A. Reliability of orthopantomogram in comparison to lateral cephalogram for linear mandibular measurements. J Ayub Med Coll Abbottabad 2022;34(4 Suppl 1):957–63.

DOI: 10.55519/JAMC-04-S4-10338

INTRODUCTION

A lateral cephalogram shows various oral and craniofacial structures from lateral aspect. Cephalometrics was introduced by Van Loon, for the first time in orthodontics but it came to full function when B. Holly Broadbent described different procedures in the Angle Orthodontist to achieve standardized head radiographs.¹ By assessing craniofacial and dental relationships, lateral cephalogram helps in diagnosis, monitoring and treatment of various dentofacial deformities and growth abnormalities. However, lateral cephalogram fails to compare the right and left sides of the orofacial structures due to overlapping of the structures of both sides and superimposed images.²

At the present time, the most important goal of orthognathic surgical procedures and orthodontic treatment is to create a symmetrical and harmonious facial appearance. Craniofacial growth and development being in disarray mostly leads to facial

asymmetries that can eventually affect a person's social life as well as his functional well-being. Among orthodontic patients, mandibular asymmetries are the most commonly seen asymmetric traits which have been reported as dimensional variations in form, size, shape and volume of both sides of the mandible.³ Mandibular asymmetry cases include hemifacial microsomia, Treacher Collins syndrome, Parry-Romberg syndrome, Nager acrofacial dysostosis syndrome, branchio-oto-renal syndrome, Miller syndrome, unilateral condylar hyperplasia etc.⁴ These cases require precise linear mandibular measurements on each side of the mandible to diagnose, monitor and plan any type of treatment including orthognathic surgery or distraction osteogenesis.⁴ For this purpose, lateral cephalogram cannot be used due to overlapping of right and left sides of craniofacial and oral structures. Although postero-anterior (PA) cephalogram can be used in detecting craniofacial asymmetries but according to some studies including

Damstra *et al* study,⁵ it is found to be unreliable in detection of some of the mandibular body length asymmetries. However, CBCT can be used to determine mandibular asymmetry particularly when chin deviation is also present but the effective dose of CBCT is several times higher when compared with that of conventional set of orthodontic radiographs (i.e., conventional lateral cephalograms and orthopantomograms).⁶

The advent of orthopantomogram by Paatero, in 1952, allowed the clinicians to easily identify, locate and measure different structures of maxillary and mandibular region with significantly decreased radiation exposure.² On an orthopantomogram, right and left side landmarks and structures can be better identified, located and visualized than on a lateral cephalogram because of no overlapping. However, some of the orthopantomogram's measurements have been found to be unpredictable because of the variations in magnification factor and methodological errors.⁷ According to Larheim and Svanaes, vertical measurements on orthopantomograms are predictable and accurate but they did not compare these measurements with cephalograms.⁸ Moreover, Ongkosuwito EM *et al.* in 2009 investigated the reliability of linear mandibular measurements by comparing OPGs and lateral cephalograms of human dried skull and found that an orthopantomogram is as accurate as a lateral cephalogram for all of the linear (vertical and horizontal) mandibular measurements.⁹ However, Kumar S.S *et al.* in 2017 found that orthopantomograms can be used to determine only angular and vertical measurements of the mandible as accurately as lateral cephalograms.²

As an orthopantomogram provides a bilateral view of maxillomandibular structures; hence, it would be prudent to detect if the visualization of both the sides of mandible is accurate and predictable. Therefore, the primary aim of the present study was to investigate the reliability of linear mandibular measurements yielded from right and left hemispheres of orthopantomograms and compare them to the values obtained from lateral cephalograms. The purpose of conducting this study was to determine if orthopantomograms can be routinely used for early diagnosis of mandibular asymmetries in orthodontic patients by measuring ramus height and mandibular length in routine clinical practice so that, further radiographic investigations can be performed. This would be helpful to the growing orthodontic patients, in whom progressive craniofacial asymmetries can be prevented and intercepted from further deterioration by timely diagnosis. As early detection and monitoring of mandibular asymmetries provide an

opportunity to achieve maximum benefit from orthopedic interventions, orthodontic camouflage procedures or distraction osteogenesis techniques, in growing stage, that can prevent the patient from multiple aggressive orthognathic surgical procedures in adult life. Early non-surgical or surgical interventions, to correct these asymmetries, improve the long-term functional and esthetic treatment outcomes and patient satisfaction.

MATERIAL AND METHODS

The present cross-sectional study was conducted at the department of Orthodontics from July to October 2021. The current study was approved by the ethical committee of the institute (Ref. No. IRB/D-000016/21). The orthodontic records of 118 patients, in the form of pretreatment orthopantomogram and lateral cephalogram, were selected. The sample size was calculated using OpenEpi Software with the findings of Kumar SS *et al.*² which reported mean ramus height to be 57.27 ± 6.54 mm on lateral cephalogram and 60.63 ± 6.47 mm on orthopantomogram. A total sample size of 118 patients, having 95% confidence interval and 80% power, were selected using non-probability consecutive sampling technique. Before the initiation of the study, each participant was well informed about the study and even a written consent was obtained from them. A serial number was given to all subjects to protect their confidentiality.

Patients, between ages of 12–35 years, with high quality pre-treatment lateral cephalograms and orthopantomograms taken by the same X-ray machine in the Natural Head Position with standard exposure conditions and with clearly visible craniofacial structures on both radiographs (OPG and lateral cephalogram) were included in the study. Patients with previous history of orthodontic treatment, orthognathic surgery, orofacial trauma, facial asymmetries, craniofacial anomalies and syndromes were excluded from the study.

All of the lateral cephalograms and orthopantomograms were obtained from the same X-ray machine (KODAK 9000C) machine under standard exposure factors, as recommended by the manufacturer. All radiographs were standardized and taken by the same operator. All orthopantomograms and lateral cephalograms were traced on acetate matte tracing papers (0.003 inches thick, 8×10 inches) by using a 2H pencil under optical illumination. Landmarks were located, lines were drawn and the required variables were measured by using a ruler. [Figures 1 and 2]. A single investigator assessed all of the linear mandibular measurements on orthopantomograms and lateral cephalograms. To

counter any missed measurement, all the parameters were rechecked.

The linear dimensions shown in [Figures 1 and 2] were measured as: Mandibular ramus height (Co-Go): the linear distance from condylion (Co) to gonion (Go) in millimeters, on both orthopantomogram and lateral cephalogram.⁹ Mandibular body length (Go-Me): the linear distance from gonion (Go) to menton (Me) in millimeters, on both orthopantomogram and lateral cephalogram.⁹ Total mandibular length (Co-Me): the linear distance from condylion (Co) to menton (Me) in millimeters, on both orthopantomogram and lateral cephalogram.⁹

To determine the reliability of the results, lateral cephalograms and orthopantomograms of 25 patients were retraced and remeasured by the same investigator after an interval of 4 weeks. A paired t-test was used to compare the two measurements. No significant difference was found between the measurements ($p>0.05$). The magnitude of the method error was calculated using the formula of Dahlberg. The method errors for the linear mandibular measurements ranged from 0.11 to 0.30 mm.

The statistical analysis of the data was carried out by using SPSS software for windows (IBM; SPSS, version 26.0) with probability level of $p\leq 0.05$ considered statistically significant. From orthopantomograms and lateral cephalograms, mean and standard deviation of ramus height (Co-Go), mandibular body length (Go-Me) and total mandibular length (Co-Me) were calculated. A paired t-test was performed to compare these linear mandibular measurements between right and left sides of orthopantomogram and an independent t-test was performed for comparison of these measurements between orthopantomogram and lateral cephalogram.

RESULTS

Mean values and standard deviation of right and left sides of orthopantomogram were determined for linear mandibular measurements (ramus height, mandibular body length and total mandibular length). Paired t-test was performed to compare the mean values of right and left sides of orthopantomogram. For all of the parameters, no statistically significant differences were detected between right and left sides of orthopantomogram ($p=0.397$ for ramus height, $p=0.266$ for mandibular body length and $p=0.095$ for total mandibular length) [Table-1].

For ramus height (Co-Go), mean and standard deviation values were determined from orthopantomograms (right and left sides) and lateral cephalograms. Mean values of the ramus height were 66.19 ± 6.26 mm, 67.19 ± 6.37 mm and 67.28 ± 6.14 mm measured using lateral cephalograms, right side of

orthopantomograms and left side of orthopantomograms, respectively. Mean value of the ramus height of the right side of the orthopantomogram was then compared with the lateral cephalogram and the same was done for the left side of the orthopantomogram. p value was determined, by performing independent sample t-test, for ramus height (Co-Go) between right side of orthopantomogram and lateral cephalogram ($p=0.226$) as well as between left side of orthopantomogram and lateral cephalogram ($p=0.177$). No statistically significant difference was found between orthopantomograms and lateral cephalograms for ramus height (as $p>0.05$).

For mandibular body length (Go-Me), mean and standard deviation were determined from orthopantomograms (right and left sides) and lateral cephalograms. [Table-3]. Mean values of the mandibular body length were 71.91 ± 7.54 mm, 105.85 ± 10.63 mm and 106.01 ± 10.83 mm measured using lateral cephalograms, right side of orthopantomograms and left side of orthopantomograms, respectively. Mean value of the mandibular body length of right side of the orthopantomogram was then compared with the lateral cephalogram and the same was done for the left side of the orthopantomogram. p value was detected, by performing independent sample t-test, for mandibular body length (Go-Me) between right side of orthopantomogram and lateral cephalogram ($p=0.000$) as well as between left side of orthopantomogram and lateral cephalogram ($p=0.000$). A statistically significant difference was found between orthopantomograms and lateral cephalograms for mandibular body length (as $p\leq 0.05$).

For total mandibular length (Co-Me), mean and standard deviation were determined for from orthopantomograms (right and left sides) and lateral cephalograms [Table-4]. Mean value of the total mandibular length was 114.95 ± 9.16 mm, 144.63 ± 11.44 mm and 144.88 ± 11.53 mm measured using lateral cephalograms, right side of orthopantomograms and left side of orthopantomograms, respectively. Mean value of the total mandibular length of right side of the orthopantomogram was then compared with the lateral cephalogram and the same was done for the left side of the orthopantomogram. p value was detected, by performing the independent sample t-test, for total mandibular length (Co-Me) between right side of orthopantomogram and lateral cephalogram ($p=0.000$) as well as between left side of orthopantomogram and lateral cephalogram ($p=0.000$). A statistically significant difference was found between orthopantomograms and lateral cephalograms for total mandibular length ($p\leq 0.05$).

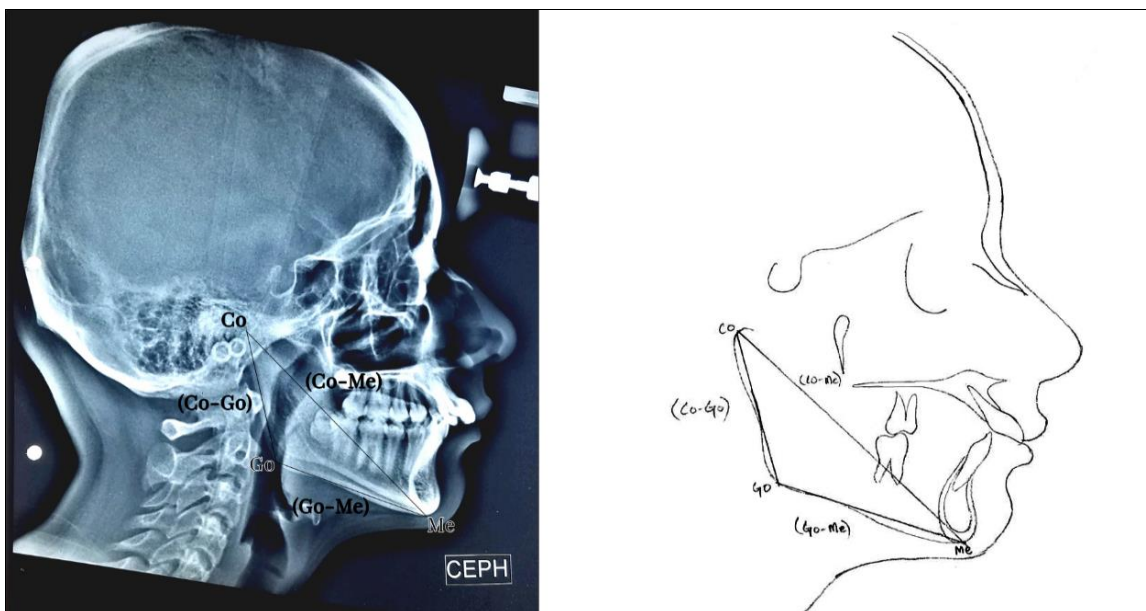


Figure-1: Diagrammatic representation of lateral cephalogram displaying ramus height (Co-Go), mandibular body length (Go-Me) and total mandibular length (Co-Me)

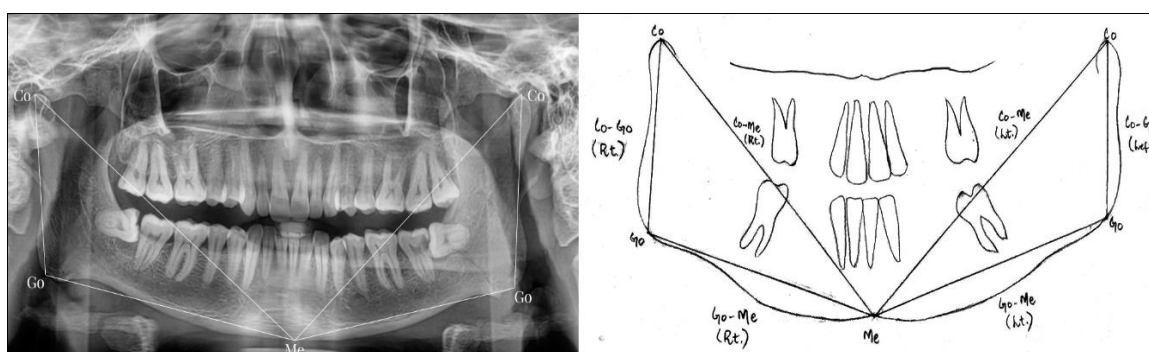


Figure-2: Diagrammatic representation of orthopantomogram displaying ramus height (Co-Go), mandibular body length (Go-Me) and total mandibular length (Co-Me) on both sides.

Table-1: Comparison of mean and standard deviation of linear mandibular measurements between right and left sides of orthopantomogram by using paired t-test

Linear Mandibular Measurements	Orthopantomogram (Right side)	Orthopantomogram (left side)	t-value	p value
Ramus height (mm)	67.19±6.37	67.28±6.14	0.850	0.397
Mandibular Body length (mm)	105.85±10.63	106.01±10.83	1.119	0.266
Total mandibular length (mm)	144.63±11.44	144.88±11.53	0.168	0.095

p is related to the comparison of left and right sides in orthopantomogram for all of the linear mandibular measurements.

Table-2: Comparison of mean and standard deviation of ramus height (Co-Go) between orthopantomogram (right and left sides) and lateral cephalogram by using independent t-test

Orthopantomogram (in mm)	Lateral Cephalogram (in mm)	t-value	p value
67.19±6.37 (Right)	66.19±6.26	1.215	0.226
67.28±6.14 (Left)	66.19±6.26	1.353	0.177

p is related to the comparison of ramus height (Co-Go) in orthopantomogram and lateral cephalogram.

Table-3: Comparison of mean and standard deviation of mandibular body length (Go-Me) between orthopantomogram (right and left sides) and lateral cephalogram by using independent t-test

Orthopantomogram (mm)	Lateral Cephalogram (mm)	t-value	p value
105.85±10.63 (Right)	71.91±7.54	28.268	<i>p</i> =0.000*
106.01±10.83 (Left)	71.91±7.54	28.061	<i>p</i> =0.000*

p is related to the comparison of mandibular body length (Go-Me) in orthopantomogram and lateral cephalogram.

**p*≤0.05 is considered to be statistically significant difference.

Table-4: Comparison of mean and standard deviation of total mandibular length (Co-Me) between orthopantomogram (right and left sides) and lateral cephalogram by using independent t-test

Orthopantomogram (mm)	Lateral Cephalogram (mm)	t-value	p-value
144.63±11.44 (Right)	114.95±9.16	21.993	p=0.000*
144.88±11.53 (Left)	114.95±9.16	22.069	p=0.000*

p is related to the comparison of total mandibular length (Co-Me) in orthopantomogram and lateral cephalogram.

* $p \leq 0.05$ is considered to be statistically significant difference.

DISCUSSION

This study was conducted to investigate the reliability and possible applicability of orthopantomograms for determining the linear mandibular measurements by comparing with lateral cephalograms. The purpose of the present study was to determine if orthopantomograms can be used as a reliable screening tool for bilateral mandibular assessment of orthodontic patients for early diagnosis of mandibular asymmetries in routine clinical practice. The comparison of gonial angle measurements between orthopantomogram and lateral cephalogram has been focused by almost all of the previous studies¹⁰⁻¹³ but only a few studies were reported to compare linear mandibular measurements. However, the reliability of the vertical and horizontal measurements obtained from orthopantomograms has always been debated upon in literature.

In the present study, the mean values of the ramus height, mandibular body length and total mandibular length on the right side of the orthopantomogram was compared with the lateral cephalogram and the same was done for the left side of the orthopantomogram. There was no statistically significant difference between orthopantomograms and lateral cephalograms for vertical parameter of mandible such as ramus height (Co-Go) ($p=0.226$, $p=0.177$). However, significant differences were found when orthopantomograms were compared with lateral cephalograms for horizontal mandibular measurements such as mandibular body length (Go-Me) ($p=0.000$) and total mandibular length (Co-Me) ($p=0.000$). The mean values of the right and the left sides of orthopantomogram were also compared for all the parameters but they also did not show any statistically significant difference. The findings of this study are in agreement with those of Kumar SS *et al.*,² who compared only two linear mandibular measurements (ramus height and body length) between orthopantomogram and lateral cephalogram and reported no statistically significant differences for the ramus height ($p=0.756$, $p=0.839$). They concluded that an orthopantomogram can be used to determine the vertical mandibular measurement (ramus height) as accurately as a lateral cephalogram but it is advised to be more cautious when determining the horizontal mandibular measurement (mandibular body length) from orthopantomograms ($p=0.021$, $p=0.012$).

Fatahi and Babouei¹⁴ also assessed the precision of orthopantomograms and compared the mandibular dimensions obtained from dry skulls, orthopantomograms and lateral cephalograms. They concluded that orthopantomograms and lateral cephalograms correlated highly significantly for ramus height, whereas the least correlation was found for mandibular body length. In the study performed by Juma A *et al.*,¹⁵ it is concluded that a detailed and accurate information for sagittal analysis ($p=0.201$) and vertical analysis ($p=0.194$) of the facial skeletal patterns can be obtained by orthopantomograms which can be considered a frequently used screening tool in clinical practice for diagnosis of facial skeleton. Moreover, Tronje *et al.*¹⁶ evaluated the reliability of linear measurements on orthopantomogram and found that vertical measurements on orthopantomograms are relatively more predictable and accurate as compared to the horizontal measurements and may be used if the patient's head is in proper position. Kurt *et al.*,¹⁷ evaluated the mandibular asymmetry in molar Class II subdivision malocclusion subjects (by detecting condylar, ramal and condylar-plus-ramal asymmetry index values) on orthopantomograms and concluded that sufficiently accurate results can be attained with orthopantomograms. However, according to Akcam *et al.*,¹⁸ with the help of orthopantomograms, acceptably accurate results can be attained for vertical craniofacial dimensions but they are not reliable enough to provide trusted information as compared to lateral cephalograms because their predictability percentages have been found to be very low. Kambylafkas *et al.*,¹⁹ in his study, also suggested that vertical posterior mandibular asymmetry can be assessed by orthopantomograms by determining the total ramal height, but the risk of underdiagnosis can still be present. In studies conducted by Habets *et al.*,^{20,21} vertical mandibular symmetry was evaluated by measuring condylar and ramus height on orthopantomograms and it is found that vertical mandibular parameters can be assessed by orthopantomograms as they provide bilateral assessment of mandible.

However, Ongkosuwito EM *et al.*,⁹ investigated the accuracy of linear mandibular measurements by comparing orthopantomograms and lateral cephalograms of human dried skull and found that an orthopantomogram is as accurate as a lateral

cephalogram for all of the vertical and horizontal mandibular measurements. In another study conducted by Nohadani and Ruf,²² it is concluded that orthopantomograms cannot be used as a reliable assessment tool for evaluating vertical facial and dentoalveolar parameters even though they produced an adequate approximation to the situation portrayed on lateral cephalograms, which is contrary to the findings of the present study.

The results of our study showed that orthopantomogram can not be reliably used for horizontal mandibular measurements as statistically significant differences were found for mandibular body length ($p=0.000$) and total mandibular length ($p=0.000$) between orthopantomogram and lateral cephalogram. These results are in accordance with the findings of Larheim *et al.*⁸ who concluded that horizontal measurements on orthopantomograms are found to be imprecise and unpredictable because of the variations in magnification factor. Moreover, Mawani *et al.*²³, while evaluating the condylar shape on digital orthopantomograms of dry skull, also found greater variations in the magnification in horizontal measurements than in vertical measurements. In another study, Abdinian *et al.*²⁴ revealed that the vertical measurements on orthopantomograms are found to be more accurate than the horizontal ones. He reported that the difference in magnification factor can be seen between vertical and horizontal dimensions on orthopantomograms in various regions of the jaws. Arora H *et al.*²⁵ stated that vertical, anterior horizontal and anterior oblique measurements are reliable on orthopantomograms because of the minimum magnification. However, Posterior horizontal and horizontal measurements crossing the midline are highly inaccurate because they showed increased magnification. He concluded that magnification factor value given by the manufacturers varies in different anatomical locations and in similar location with different position and hence should not be relied upon. Gomez *et al.*²⁶ also found in his study that the vertical magnification variations are less than those of horizontal magnifications.

The findings of the current study confirm the improvement in clinical versatility of orthopantomograms. As orthopantomogram is a routine radiographic record for all orthodontic patients, it can also be used as a preliminary screening tool for early detection of vertical mandibular asymmetries and to determine the need for further detailed radiographic investigations. Prompt diagnosis of mandibular asymmetry, by orthopantomogram analysis, offers an opportunity to prevent the progressive craniofacial asymmetries from further deterioration and to provide timely intervention which results in improved functional and esthetic treatment

outcomes. In the present study, linear mandibular measurements of orthopantomograms were compared to the values obtained from lateral cephalograms. However, limitations of this study include errors in identification of landmarks and tracing of structures on lateral cephalogram. In future studies, the reliability of conventional orthopantomograms can be verified by comparing them with cone beam computed tomography (CBCT) three-dimensional data which is the current gold standard for the accurate diagnosis. If found accurate, orthodontists can be assured that they can use the conventional orthopantomograms as a preliminary assessing tool for mandibular asymmetries.

CONCLUSION

An orthopantomogram is as reliable as a lateral cephalogram only for vertical mandibular measurements while horizontal mandibular measurements on orthopantomograms are significantly different when compared with lateral cephalograms. Orthopantomogram being an easier screening tool for bilateral mandibular assessment of orthodontic patients, it can be a better choice for measuring and comparing vertical mandibular measurements especially for early detection of mandibular asymmetries. However, vigilance is advised to the clinicians when predicting horizontal measurements from orthopantomograms as these measurements are found to be unreliable and unpredictable because of the nonlinear variations in the magnification at different object depths on orthopantomograms.

AUTHORS' CONTRIBUTION

AF: Literature search, conceptualization of study design, methodology, data collection, data analysis, data interpretation, resources and write-up. AS: Supervision, write-up, review, editing, validation, proof reading and project administration.

REFERENCES

1. Pattanaik S. Evolution of Cephalometric Analysis of Orthodontic Diagnosis. *Indian J Med Forensic Med Toxicol* 2019;13(4):1830-4.
2. Kumar SS, Thailavathy V, Srinivasan D, Loganathan D, Yamini J. Comparison of Orthopantomogram and Lateral Cephalogram for Mandibular Measurements. *J Pharm Bioallied Sci* 2017;9(Suppl 1):S92-5.
3. Ramirez-Yañez GO, Stewart A, Franken E, Campos K. Prevalence of mandibular asymmetries in growing patients. *Eur J Orthod* 2011;33(3):236-42.
4. Nik TH, Gorjizadeh F. Differential Diagnosis and Treatment Approaches of Hemifacial Microsomia: A Review. *Iran J Orthod* 2015;10(1):e4994.
5. Damstra J, Fourie Z, Ren Y. Evaluation and comparison of postero-anterior cephalograms and cone-beam computed tomography images for the detection of mandibular asymmetry. *Eur J Orthod* 2013;35(1):45-50.

6. Signorelli L, Patcas R, Peltomäki T, Schätzle M. Radiation dose of cone-beam computed tomography compared to conventional radiographs in orthodontics. *J Orofac Orthop* 2016;77(1):9–15.
7. Hirpara N, Jain S, Hirpara V, Punyani P. Comparative assessment of vertical facial asymmetry using posteroanterior cephalogram and orthopantomogram. *J Biomed Sci* 2017;6(1):1–7.
8. Larheim T, Svanaes D. Reproducibility of rotational panoramic radiography: mandibular linear dimensions and angles. *Am J Orthod Dentofacial Orthop* 1986;90(1):45–51.
9. Ongkosuwito EM, Dieleman MM, Kuijpers-Jagtman AM, Mulder PG, van Neck JW. Linear mandibular measurements: comparison between orthopantomograms and lateral cephalograms. *Cleft Palate Craniofac J* 2009;46(2):147–53.
10. Baig MN. Reliability of panoramic radiography in assessing gonial angle compared to lateral cephalogram. *Pak Oral Dent J* 2018;38(3):320–3.
11. Memon S. Comparison Between Three Methods of Gonial Angle Formation on Lateral Cephalogram and Orthopantomogram. *J Pak Dent Assoc* 2018;27(2):58.
12. Radhakrishnan PD, Sapna Varma NK, Ajith VV. Dilemma of gonial angle measurement: Panoramic radiograph or lateral cephalogram. *Imaging Sci Dent* 2017;47(2):93–7.
13. Araki M, Kiyosaki T, Sato M, Kohinata K, Matsumoto K, Honda K. Comparative analysis of the gonial angle on lateral cephalometric radiographs and panoramic radiographs. *J Oral Sci* 2015;57(4):373–8.
14. Fattahi H, Babouee A. Evaluation of the precision of panoramic radiography in dimensional measurements and mandibular steepness in relation to lateral cephalometry. *J Mashhad Dent Sch* 2007;31(3):223–30.
15. Juma A, Tattan M, Duarte C. The alternative use of a nonconventional orthopantomograms analysis technique for facial skeletal assessment. *Int J Oral Maxillofac Surg* 2018;3(2):26.
16. Tronje G, Welander U, McDavid WD, Morris CR. Image Distortion in Rotational Panoramic Radiography: VI. Distortion Effects in Sliding Systems. *Acta Radiol Diagn (Stockh)* 1982;23(2):153–60.
17. Kurt G, Uysal T, Sisman Y, Ramoglu SI. Mandibular asymmetry in Class II subdivision malocclusion. *Angle Orthod* 2008;78(1):32–7.
18. Akcam MO, Altioek T, Ozdiler E. Panoramic radiographs: a tool for investigating skeletal pattern. *Am J Orthod Dentofacial Orthop* 2003;123(2):175–81.
19. Kambylafkas P, Kyrkanides S, Tallents RH. Mandibular asymmetry in adult patients with unilateral degenerative joint disease. *Angle Orthod* 2005;75(3):305–10.
20. Habets L, Bezuur J, Van Ooij C, Hansson T. The orthopantomogram, an aid in diagnosis of temporomandibular joint problems. I. The factor of vertical magnification. *J Oral Rehabil* 1987;14(5):475–80.
21. Habets L, Bezuur J, Naeiji M, Hansson T. The Orthopantomogram®, an aid in diagnosis of temporomandibular joint problems. II. The vertical symmetry. *J Oral Rehabil* 1988;15(5):465–71.
22. Nohadani N, Ruf S. Assessment of vertical facial and dentoalveolar changes using panoramic radiography. *Eur J Orthod* 2008;30(3):262–8.
23. Mawani FA. The anatomic accuracy of lateral temporomandibular joint images from axially corrected multidirectional tomography and three panoramic radiography units: A comparative dry skull study. 2004.
24. Abdinian M, Soheilipour F, Nazeri R, Ghorbanizadeh S. Investigation of the magnification of digital panoramic radiographs in different regions of the jaws. *SRM J Res Dent Sci* 2016;7(1):10.
25. Arora H, Jain V, Pai KM, Kamboj R. Precision of dimensional measurements of mandible in different positions on orthopantomogram. *Indian J Dent Res* 2013;24(1):48.
26. Gomez-Roman G, Lukas D, Beniashvili R, Schulte W. Area-dependent enlargement ratios of panoramic tomography on orthograde patient positioning and its significance for implant dentistry. *Int J Oral Maxillofac Implants* 1999;14(2):248–57.

Submitted: November 1, 2021

Revised: May 31, 2022

Accepted: June 6, 2022

Address for Correspondence:

Prof. Dr. Attiya Shaikh, Head of Department of Orthodontics, Liaquat College of Medicine and Dentistry, Karachi-Pakistan

Cell: +92 307 222 4463

Email: dr.attiyashaikh@gmail.com