

## ORIGINAL ARTICLE

## EFFECT OF INTRAVITREAL PERFLUORO PROPANE (C3F8) IN THE MANAGEMENT OF SYMPTOMATIC VITREOMACULAR TRACTION

Syeda Minahil Gardezi, Khujasta Gul, Misbah Batool, Ali Afzal Bodla<sup>✉</sup>

MMDC-Multan &amp; Bodla Eye Care, Multan-Pakistan

**Background:** To study the efficacy of a single 0.3ml of C3F8 injection for the treatment of symptomatic VMT. **Methods:** In this retrospective interventional study a total of nine patients were recruited. The mean age was 67 years. Patients had a follow-up at one week and four weeks post injections. VMT status was confirmed on repeat Oct scan. **Results:** There was a complete release of VMT In 4 patients after one week and further release of VMT was observed in two more patients after four weeks. Hence six out of nine patients had complete resolution of pathology following C3F8 injection. **Conclusion:** Intravitreal C3F8 is a cheaper and safer option for the treatment of vitreomacular traction as compared to pars plana vitrectomy or Ocriplasmin.

**Keywords:** Hexafluoropropylene (C3F8); Sulphur hexafluoride (SF6); Vitreomacular traction; Vitrectomy

**Citation:** Gardezi SM, Gul K, Batool M, Bodla AA. Effect of intravitreal perfluoro propane (C3F8) in the management of symptomatic vitreomacular traction. J Ayub Med Coll Abbottabad 2023;35(3):367–70.

**DOI:** 10.55519/JAMC-03-11555

## INTRODUCTION

Vitreomacular traction is a disorder which is characterized by an incomplete posterior vitreous detachment at macula with a posterior hyaloid face still adherent to the fovea. This results in a foveal pull causing neurosensory retinal distortion and detachment from the retinal pigment epithelium. This syndrome was first reported by Reese *et al* in 1970 and confirmed based on histological studies of the macula.<sup>1</sup> This disease is more prevalent in females as compared to males.<sup>2</sup> The age at the time of presentation ranges from 43–85.<sup>3</sup> Jackson TL *et al* reported the prevalence of VMT without macular hole to be estimated at around 22.5 cases per 100,000 of the normal population.<sup>4</sup> VMT can present with low visual acuity along with an epiretinal membrane. If left untreated it can cause a permanent visual loss. The other devastating complication can be the development of full thickness macular hole which requires a pars plana vitrectomy with ILM peeling. Less common consequences are the development of metamorphopsia, cystoid macular oedema and a central scotoma. The gold standard investigation for the diagnosis of VMT IS OCT. It shows a distorted fovea along with foveal detachment, foveal thickening and rarely a formation of a lamellar hole.<sup>5,6</sup> In about 10% of the cases there is spontaneous resolution within 8–15 months, however, refractory cases may require a pars plana vitrectomy which is an invasive and expensive treatment. In a study conducted by Wendel *et al* it was estimated that around 73% of the patients achieved successful macular attachment.<sup>7</sup> Although it carries complications such as endophthalmitis, cataract formation, iatrogenic retinal breaks and retinal detachment.<sup>8</sup> Ocriplasmin has been widely described as a chemical vitreolytic agent used for the treatment of VMT.

It is less expensive and carries a significantly lower success rate as compared to vitrectomy. Some of the adverse effects associated with the use of ocriplasmin include lens subluxation, retinal breaks, dyschromatopsia and decreased visual acuity.<sup>9,10</sup> Another approach to treat VMT is the use of gases like SF6 and C3F8. SF6 is relatively shorter acting as compared to C3F8 and has also a lower success rate.<sup>11,12</sup> Day and Shelly *Et al* reported a release of VMT in 55.6 percent of their patients 4 weeks post intervention with SF6.<sup>13</sup>

## MATERIAL AND METHODS

This retrospective, interventional, non-randomized study comprising a total of 9 patients was undertaken at Bodla Eye Care, a tertiary eye center in southern Punjab. Patients recruited in the study were examined and treated from August 2019 to September 2021. Diagnosis of VMT was based upon the OCT criteria which was defined by the International Vitreomacular Traction Study group. As per the defined criteria, the patients involved had a perifoveal vitreous detachment, vitreous strands attached within a 3 mm radius of the fovea causing an obvious anatomical pull and vitreous detachment causing the structural changes in the fovea as confirmed on OCT scan. All patients underwent baseline best-corrected visual acuity, tonometry, complete slit lamp examination and OCT at the time of presentation, and informed consent was obtained from all the recruited patients. Phakic patients were informed of the possibility of secondary cataract formation post C3F8 injection. The Procedure was performed in the operating theatre under sterile conditions, prior to the procedure alcaine (Alcon) eye drops were instilled to ensure adequate topical anaesthesia. Topical drops of 5% povidone-iodine and

0.5% tropicamide were used to achieve appropriate sterility and mydriasis. An anterior chamber paracentesis was performed using a 27-gauge needle removing 0.3ml of aqueous prior to gas injection. A 30-gauge needle was inserted via Pars plana to inject 0.3ml of 100% C3F8. Gas was injected with a needle tip being directly visualized through a microscope. It was ensured that an adequate size single large bubble of C3F8 is achieved and visualized at the end of the procedure. The patients were reviewed the next day following gas injection on which a complete slit lamp examination with intraocular pressure measurement, at one week and then a month later. Patients were advised to achieve an adequate posture for a minimum of one week post gas injection and they have been advised a prone position as much as their physical mobility allows along with repeated sideways gaze.

Following the data collection IBM SPSS 25 was used for data analysis, paired sample test was used to compare pre and post injection Best Corrected Visual Acuity (BCVA). The frequency table is used to gather the

quantitative analysis of age, lens status, central retinal thickness, BCVA and release of VMT.

**RESULTS**

There was a total of 9 eyes for 9 patients. Six were females and four were males. The age of the patients was between 54–73 with the mean age being 67 years. Two of the patients (22.2%) had an epiretinal membrane and four (44.4%) had diabetic retinopathy at the time of presentation. Six out of nine eyes (66.6%) were pseudo phakic. The results of pre and post injection of C3F8 are shown in the table below. Four patients received C3F8 injection in the right eye and the other five received C3F8 injection in the left eye. Six out of nine patients that were treated had a complete release of VMT after one week and two more patients had a release of VMT after four weeks. The patients who were treated with C3F8 presented with no side effects following the treatment. The results of four of the patient’s pre and post injection of C3F8 are shown in Figures 1,2,3 and 4.

Case	Sex	Age	Eye	Lens status	Visual acuity pre injection	Visual acuity post injection	Release of VMT	Time
1	F	73	R	phakic	6/24	6/24	no	1 week
2	F	69	L	phakic	6/18	6/12	yes	1 month
3	M	64	L	Pseudo phakic	6/18	6/9	yes	1 week
4	M	72	R	Pseudo phakic	6/12	6/12	yes	N/A
5	F	59	L	Pseudo phakic	6/9	6/9	no	1 week
6	F	54	R	phakic	6/12	6/9	yes	1 week
7	F	67	R	Pseudo phakic	6/12	6/12	no	N/A
8	M	70	L	Pseudo phakic	6/18	6/9	yes	1 week
9	F	73	L	Pseudo phakic	6/36	6/24	yes	1 month

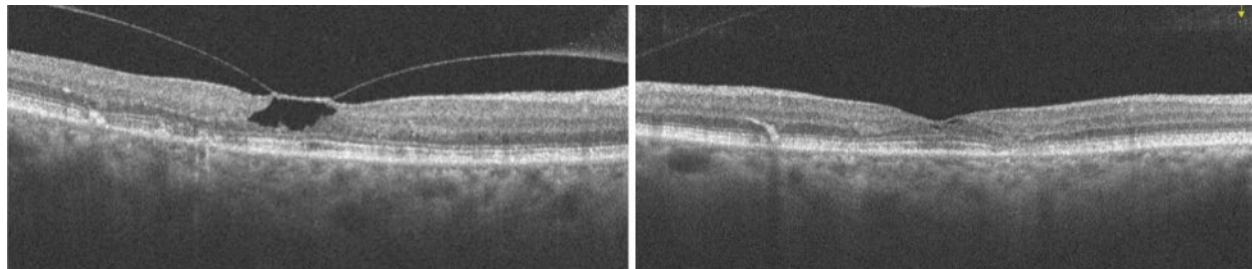


Figure-1: (a, b). Spectral-domain OCT of the case (3) before and after C3F8 injection. (a,b)

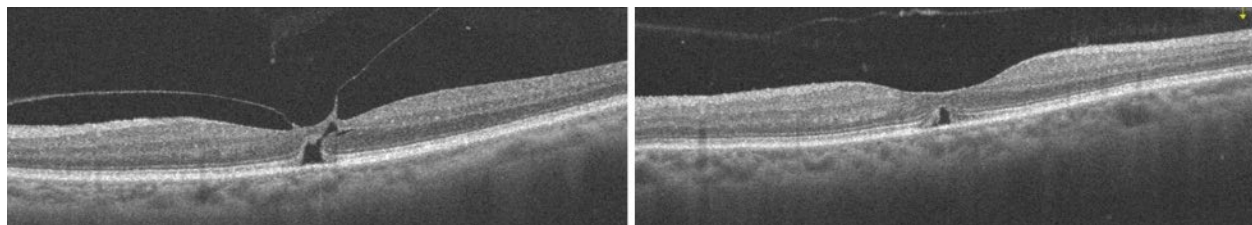
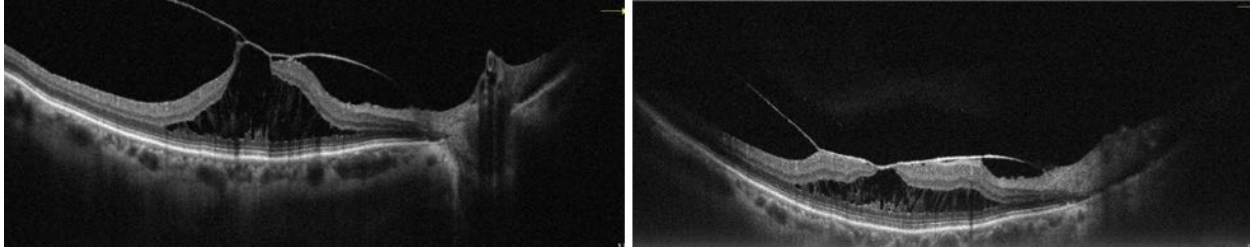
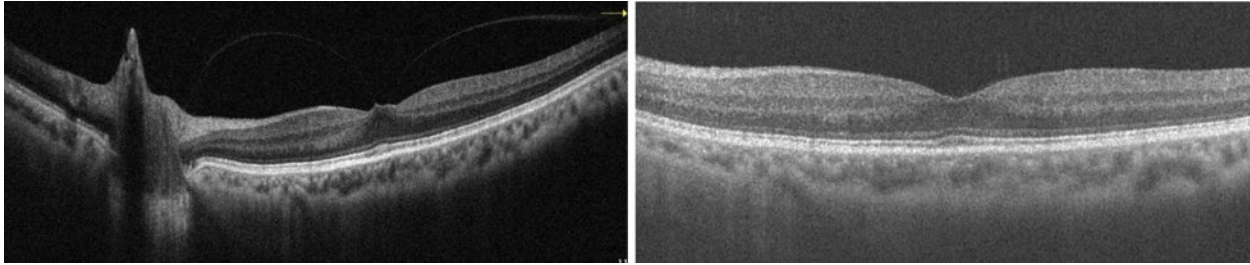


Figure-2: (a, b). Oct of the case (4) with a clear visualization of the procedure. There’s a complete release of vitreous traction with the restoration of normal retinal architecture.



**Figure-3: (a, b). Oct of case (1) preoperative in which extensive VMT was noted with neurosensory retinal detachment along with macular hole. In Figure 3b, although the VMT was not released, there's still evident flattening of the retina along with some restoration of retinal structures.**



**Figure-4: (a, b). OCT of case (8) pre and post C3F8 injection. A complete release of VMT with the restoration of the normal retina is seen post-operatively.**

## DISCUSSION

The use of expansile gas injection to induce the posterior vitreous detachment for the release of VMT was first introduced by Chan in 1995.<sup>14</sup> He concluded in a study of 56 eyes that there was a success rate of 86% in the release of vitreomacular traction along with a closure rate of 60% of stage two macular hole when the patients were injected with intravitreal C3F8. In a retrospective study carried out by MG Claus and Feron *et al* 85% of the patients had a release of VMT within 1 month and 78.9% of the eyes achieved the same results within 3 months.<sup>15,16</sup> *Et al* carried out a double-blind study of 652 eyes 464 eyes were treated with ocriplasmin and 188 were treated with a placebo, 26.5% of the patients who got injected with ocriplasmin achieved the release of VMT and only 10% of the eyes treated with placebo were cured. It was also noted that the eyes treated with ocriplasmin had a higher rate of development of posterior vitreous detachment.<sup>17</sup>

In a similar study to ours, Jorge *et al* reported that six patients that had stage 2 macular holes were injected with C3F8. Five patients had improved visual acuity along with closure of the macular hole whereas one patient didn't determine the efficacy of intravitreal injection for the release of VMT. He had four eyes, all of which were of males and after one-month post injection, there was a complete release of VMT<sup>19,20</sup>. Vitreolysis following the injection of ocriplasmin had a lower success rate as compared to C3F8, SF6.<sup>21</sup> Ocriplasmin is associated with haemorrhages of the

conjunctiva.<sup>22</sup> Moreover, this is an expensive and invasive treatment modality. Ocriplasmin is associated with floaters and haemorrhages of the conjunctiva.<sup>23</sup> Expansile gases are not only the less expensive mode of the treatment but also a single intravitreal injection of C3F6 can solely result in the complete release of VMT.<sup>24</sup> Hence, the use of expansile gases is an alternative treatment for VMT not only because of cost-effectiveness but also due to comparable results. Study limitation includes a relatively smaller group of patients hence further large studies are required to compare different treatment modalities to treat VMT.

## CONCLUSION

Intravitreal C3F8 is cheaper, has markedly low morbidity and is a more effective approach to treat vitreomacular traction as compared to ocriplasmin and pars plana vitrectomy.

Vitrectomy is an expensive procedure which can only be performed in an operation theatre setting. Ocriplasmin on the other hand carries a significant price along with limited availability in the third world and can also result in retinal breaks. It also has a lower success rate than C3F8.

## AUTHORS' CONTRIBUTION

SMG: Literature search, data collection, analysis. KG: Literature search, data collection, analysis, write-up. MB: Literature search, data collection, analysis, write-up. AAB: Literature search, conceptualization of the study, proofreading.

REFERENCES

1. Reese AB, Jones IS, Cooper WC. Vitreomacular traction syndrome confirmed histologically. *Am J Ophthalmol* 1970;69(6):975–7.
2. Steel DHW, Lotery AJ. Idiopathic vitreomacular traction and macular hole: a comprehensive review of pathophysiology, diagnosis, and treatment. *Eye (Lond)* 2013;27(Suppl 1):S1–21.
3. Javed RM, Khan AA, Tayyab H, Chaudhry N. SF6 Assisted Pneumatic Vitreolysis in Cases of Vitreomacular Traction Syndrome. *Pak J Ophthalmol* 2018;34(3):139–44.
4. Jackson TL, Nicod E, Angelis A, Grimaccia F, Prevost AT, Simpson ARH, *et al.* Pars plana vitrectomy for vitreomacular traction syndrome: A systematic review and metaanalysis of safety and efficacy. *Retina* 2013;33(10):2012–7.
5. Do DV, Cho M, Nguyen QD, Shah SM, Handa JT, Campochiaro PA, *et al.* The impact of optical coherence tomography on surgical decision making in epiretinal membrane and vitreomacular traction. *Trans Am Ophthalmol Soc* 2006;104:161–6.
6. Bottós J, Elizalde J, Arevalo JF, Rodrigues EB, Maia M. Vitreomacular Traction Syndrome. *J Ophthalmic Vis Res* 2012;7(2):148–61.
7. Wendel RT, Patel AC, Kelly NE, Salzano TC, Wells JW, Novack GD. Vitreous Surgery for Macular Holes. *Ophthalmology* 1993;100(11):1671–6.
8. Stein JD, Zacks DN, Grossman D, Grabe H, Johnson MW, Sloan FA. Adverse Events After Pars Plana Vitrectomy Among Medicare Beneficiaries. *Arch Ophthalmol* 2009;127(12):1656–63.
9. Smiddy William E. Patient Selection for Ocriplasmin Treatment of Patients with VMT: The honeymoon is over, but the marriage is stable. *Retin Physician* 2015;12:19–20.
10. Quezada Ruiz C, Pieramici DJ, Nasir M, Rabena M, Avery RL. Severe acute vision loss, dyschromatopsia, and changes in the ellipsoid zone on sd-oct associated with intravitreal ocriplasmin injection. *Retinal Cases Brief Rep* 2015;9(2):145–8.
11. Hecht I, Mimouni M, Blumenthal EZ, Barak Y, Charles S. Sulfur Hexafluoride (SF 6 ) versus Perfluoropropane (C 3 F 8 ) in the Intraoperative Management of Macular Holes: A Systematic Review and Meta-Analysis. *J Ophthalmol* 2019;2019:1820850.
12. Team RR. Pneumatic Vitreolysis: The Little Bubble that Could. Interview with Clement Chan, MD [Internet]. Retina Round Up. 2017 [cited 2022 Oct]. Available from: <https://retinaroundup.com/2017/10/20/pneumatic-vitreolysis-the-little-bubble-that-could-interview-with-clement-chan-md/>
13. Day S, Martinez JA, Nixon PA, Levitan M, Dooner JW, Wong RW, *et al.* Intravitreal sulfur hexafluoride injection for the treatment of vitreomacular traction syndrome, National Institutes of Health. *Retina* 2016;36(4):733–7.
14. Chan CK, Wessels IF, Friedrichsen EJ. Treatment of Idiopathic Macular Holes by Induced Posterior Vitreous Detachment. *Ophthalmology* 1995;102(5):757–67.
15. Claus MG, Feron E, Veckeneer M. Pneumatic release of focal vitreomacular traction. *Eye (Lond)* 2017;31(3):411–6.
16. Mori K, Saito S, Gehlbach PL, Yoneya S. Treatment of stage 2 macular hole by intravitreal injection of expansile gas and induction of posterior vitreous detachment. *Ophthalmology* 2007;114(1):127–33.
17. Stalmans P, Benz MS, Gandorfer A, Kampik A, Girach A, Pakola S, *et al.* Enzymatic Vitreolysis with Ocriplasmin for Vitreomacular Traction and Macular Holes. *N Engl J Med* 2012;367(7):606–15.
18. Jorge R, Costa RA, Cardillo JA, Uno F, Bonomo PP, Farah ME. Optical coherence tomography evaluation of idiopathic macular hole treatment by gas-assisted posterior vitreous detachment. *Am J Ophthalmol* 2006;142(5):869–71.
19. Primavera V, Agea L, Cicinelli MV, Centoducati T, Alessio G, Querques G. Intravitreal injection of air for the treatment of vitreomacular traction. *Retin Cases Brief Rep* 2020;14(2):141–5.
20. Gonzalez MA, Flynn HW, Bokman CM, Feuer W, Smiddy WE. Outcomes of Pars Plana Vitrectomy for Patients with Vitreomacular Traction. *Ophthalmic Surg Lasers Imaging Retina* 2015;46(7):708–14.
21. Steinle N, Dhoot D, Pieramici DJ, See RF, Castellarin A, Couvillion S, *et al.* Comparison of Three Non-surgical Treatments for Vitreomacular Traction (VMT). *Invest Ophthalmol Vis Sci.* 2016;57(12).
22. Knudsen VM, Kozak I. A retrospective study of a single practice use of ocriplasmin in the treatment of vitreomacular traction. *Saudi J Ophthalmol* 2014;28(2):139–44.
23. Khan MA, Haller JA. Ocriplasmin for Treatment of Vitreomacular Traction: An Update. *Ophthalmol Ther* 2016;5(2):147–59.
24. Steinle NC, Dhoot DS, Ruiz CQ, Castellarin AA, Pieramici DJ, See RF, *et al.* Treatment of vitreomacular traction with intravitreal perfluoropropane (C3F8) injection. *Retina* 2017;37(4):643–50.

Submitted: November 22, 2022	Revised: April 27, 2023	Accepted: May 13, 2023
------------------------------	-------------------------	------------------------

**Address for Correspondence:**

**Dr. Ali Afzal Bodla**, Bodla Eye Care, District Jail Road, Multan-Pakistan

**Cell:** +92 303 936 3917

**Email:** [aliafzal111@gmail.com](mailto:aliafzal111@gmail.com)