

PICTORIAL

360 DEGREE DEEP CORNEAL VASCULARIZATION IN A CASE OF ENDOPHTHALMITIS WITH CORNEAL ABSCESS

Anmol Ulhas Naik, Shveta Bhimashankar Gadewar*

Department of Ophthalmology, BMC Eye Hospital, Mumbai-India, *Lokmanya Tilak Municipal Medical College & General Hospital, Sion, Mumbai-India

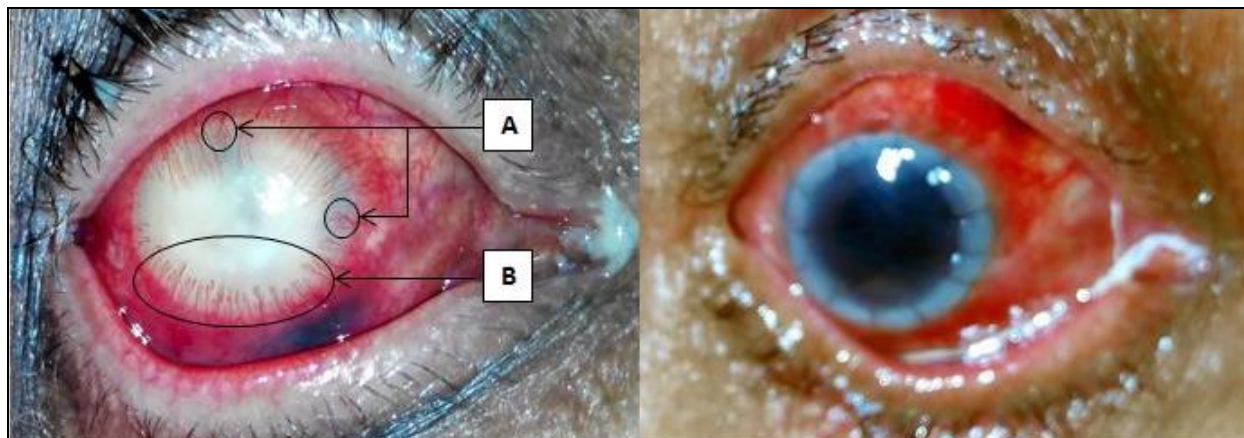


Figure 1: Deep corneal vascularization in a case of post-operative endophthalmitis with corneal abscess
(A: Terminal loops B: Brush)

Figure 2: Ocular status after peritomy and therapeutic penetrating keratoplasty

J Ayub Med Coll Abbottabad 2017;29(2):368

A 65-year-old male presented to us with symptoms of severe pain in right eye with loss of vision for 1 week. He had undergone a manual small incision cataract surgery elsewhere 2 weeks back. 48–72 hours post-surgery, his vision started decreasing and he presented to us in a state shown in the figure 1. On examination, a provisional diagnosis of post-operative endophthalmitis was made. The anterior segment showed ciliary congestion, 360° corneal vascularization with corneal abscess. Corneal neovascularization (or simply corneal vascularization) results from the growth of new vessels from the limbal vasculature into the normally avascular cornea.¹ Corneal vascularization may be superficial or deep. In superficial variety, the vessels are arranged in an arborizing pattern beneath the corneal epithelium and their continuity with conjunctival vessels can be traced.² In deep vascularization, vessels are usually straight, do not anastomose and their continuity beyond limbus cannot be traced.² Deep vessels can be arranged as terminal loops (type A), brush (type B), parasol, umbel, network or as interstitial arcade.² Common causes of deep vascularization are interstitial keratitis, disciform keratitis, deep corneal ulcer, chemical burns, etc.²

Treatment options include topical corticosteroids, radiation, diathermy and peritomy but none is satisfactory for the deep variety. Our patient underwent a 360° peritomy followed by therapeutic penetrating keratoplasty (TPK) and vitrectomy. The status post-management is shown in figure-2. This pictorial aims to demonstrate two types of deep corneal vascularization seen in same patient, which is quite rare. Corneal vascularization can lead to loss of corneal transparency and hence needs management energetically.

REFERENCES

1. Giulio F, Chiara G, Paolo R. Corneal Neovascularization: A Translational Perspective. J Clin Exp Ophthalmol 2015;6(1):387.
2. Khurana AK. Diseases of the Lens. Comprehensive ophthalmology 4th ed. New Delhi: New Age International; 2007.

Received: 26 June, 2016

Revised: --

Accepted: 27 January, 2017

Address for Correspondence:

Anmol Ulhas Naik, Department of Ophthalmology, BMC Eye Hospital, Maulana Shaikat Ali Road, Mumbai-400 008, Maharashtra-India

Email: dranmolnaik@gmail.com