

## ORIGINAL ARTICLE

## COMPARISON OF FAILURE RATE OF TEMPORARY ANCHORAGE DEVICES PLACED WITH PLATELET RICH PLASMA AND PLACEBO OVER SIX MONTHS: A SPLIT MOUTH RANDOMIZED CLINICAL TRIAL

Nofil Ahmad<sup>1</sup>, Owais Khalid Durrani<sup>2</sup>, Faiza Ijaz<sup>3</sup>, Zuhaa Mushtaq<sup>4</sup>, Iram Abbas<sup>3</sup>

<sup>1</sup>Frontier College of Dentistry, Abbottabad-Pakistan

<sup>2</sup>Department of Orthodontics, School of Dentistry, SZAMBU, Islamabad-Pakistan

<sup>3</sup>Ayub College of Dentistry, Abbottabad-Pakistan

<sup>4</sup>Abbottabad International Dental College, Abbottabad-Pakistan

**Background:** The aim of this in vitro research was to compare and evaluate the stability of TADs coated with PRP over 6 months. TAD stability is essential for the long-term success of orthodontic treatment. PRP has become a valuable adjunct to promote healing in many procedures of oral surgery. The use of PRP in combination with bone grafts in dental treatments yields positive results in terms of improving the handling properties of the grafts and enhancing the quantity and quality of the newly formed bone. **Methods:** This study was conducted at Islamic International Dental College, Orthodontic Department for 6 months from April 2018 to February 2019. It was a triple-blinded study using split-mouth randomized clinical trial. Comparison of Failure of Temporary Anchorage Devices inserted with Platelet Rich Plasma and Platelet Poor Plasma (placebo) was done on 25 patients with TADs placed on the right and left sides (total of 50 TADs). Patients who had visited for comprehensive orthodontic treatment were screened according to inclusion and exclusion criteria to be included in the study. The consent form was designed in which the procedure and the reason for the study were explained to every patient selected. Each patient was given the consent form which was signed by the patient. Injection of a few drops of PRP into the pilot hole by an 18 gauge needle syringe and similarly PPP (Placebo) onto the opposing site was done. The operator was blinded during the procedure. Patients were advised to report if there was any failure of TAD. TADs were assessed on every orthodontic visit (monthly) for 6 months. **Results:** The total number of patients was 25, each with TAD on both the right and left sides. In a total of 50 TADs, 5 (10%) failed, 4 (8% of the total) of the left side and 1 (2% of the total) of the right side. Out of these 25, 14 (56%) were males and 11 (44%) were females. In 25 patients only 1 (4%) patient showed both left and right side failure while 4 (16%) patients showed only left side failure. In terms of PPP (placebo) and PRP, the rate of failure were 3 (12%) of PPP and 2 (8%) for PRP. The mean days of failure were  $46.00 \pm 3.22$  and  $6.50 \pm 9.192$  for PPP and PRP respectively. **Conclusion:** From this study, it was noticed that there was no significant difference in the stability of TADs injected with PRP or PPP (placebo). Other factors such as gender, and patient or operator handedness were also not significant.

**Keywords:** Platelets-rich Plasma; Platelet-Poor Plasma; Temporary Anchorage Devices

**Citation:** Ahmad N, Durrani OK, Ijaz F, Mushtaq Z, Abbas I. Comparison of Failure Rate of Temporary Anchorage Devices Placed with Platelet Rich Plasma and Placebo over Six Months: A Split Mouth Randomized Clinical Trial. J Ayub Med Coll Abbottabad 2024;36(1):98–104.

DOI: 10.55519/JAMC-01-12852

### INTRODUCTION

Orthodontic mini-screws also known as temporary anchorage devices (TADs) once were rare, however now commonly used in orthodontics. They are worthwhile for a variety of complex orthodontic movements with a significant advantage of reducing the treatment time and decreasing the dependency on patient compliance.

Anchorage augmentation is the main goal for which TADs are placed in the oral cavity. They provide absolute skeletal anchorage and the desired dento alveolar movements can be achieved. For TADs,

mechanical retention is the determining factor for their primary stability and osseointegration is not required as it is needed for conventional dental prosthetic implants.<sup>1</sup>

Orthodontic mini-screws comprising different lengths (usually 4.0–10.0 mm) and different diameters (ranging usually from 1.2 mm to 2.5 mm) are available (Figure-5). Mostly, larger diameter screws deliver more anchorage resistance as compared to the smaller diameters and in addition to that give lower fracture risk under torque loads.<sup>2</sup> However, TADs with a smaller diameter are comparatively more easily inserted in narrow spaces with less chance of

radicular damage. TADs that are most commonly used in clinical practice have a diameter of 1.5 mm.<sup>3</sup> TADs are mostly made of titanium which is tissue-friendly and has good osteointegration. Palatal TADs are mostly larger in length and diameter as compared to the ones that are used at the buccal bone surfaces.<sup>4</sup>

Platelet-rich plasma (PRP) acquired from cloistering and gathering freshly obtained venous blood is an analogous source of different factors for growth. Every such factor which could enhance and amplify the osseous reclamation can be fruitful for early bone mending surrounding the implants. Plasma consisting of factors for growth is proposed to increase regeneration of epithelial and osseous tissues thus enhancing the stability of TADs.<sup>5</sup> Various growth factors released from platelets include transforming growth factors 1 and 2 (TGF-1 and TGF- 2), vascular endothelial growth factor, platelet-derived growth factors from platelets, basic platelet and fibroblast factors for growth and activating platelet factor which is essential in any healing of the wound. The peripheral blood is composed of 94%, 6% and less than 1% of platelets, white blood cells and red blood cells respectively.<sup>6</sup>

Mostly, PRP is utilized in the form of a gel manufactured by mixing thrombin and calcium chloride with PRP (formed by petrification of analogous blood). PRP gel consists of an increased amount of fibrinogen and platelets. Platelets are pioneer cells to react at the site of the wound and are involved in the angiogenic cascade as a result assisting in soft and hard tissue healing.<sup>7</sup>

In recent times, PRP has emerged as an adjunct and a beneficial entity to enhance healing in various manoeuvres related to facio maxillary surgery. These consist of surgical rehabilitation of the alveolar cleft, mandibular reconstruction, correction of periodontal infrabony defects along with plastic surgery manoeuvres dealing with periodontal issues and procedures related to the successful induction of prosthetic implants with more stable flap adaptation, haemostasis and treatment of necrosis of vessels which can also be induced by multiple other etiological factors (e.g. radio-osteonecrosis).<sup>8</sup>

Application of PRP after extraction of 3rd molar teeth has been shown to accelerate bone repair. PRP has beneficial results in the treatment of temporomandibular joint disorders and pain reduction.<sup>9</sup> PRP accelerates the healing of wounds and reduces healing time as well as results in significant clinical improvements in intraosseous periodontal defects.<sup>10</sup> The utilization of PRP along with tissue grafts offered beneficial results by promoting the handling qualities of the grafts and

improving the quality and quantity of freshly manufactured bone.<sup>11</sup>

The study was done to assess whether the injection of platelet-rich plasma improves the stability of TADs in bone as compared to the TADs injected with placebo (platelet-poor plasma) during retraction of upper anterior segments after the extractions of maxillary first premolars.

Improvement in the stability of TADs due to PRP which is a rich source of growth factors can have a positive impact on orthodontic treatment outcomes as a decreased rate of TAD failure (loosening) due to enhanced stability in bone will lead to a reduction in overall treatment time, reduction in cost of treatment to the patient (as less TAD failure) and reduction of morbidity to the patient due to procedure and increased predictability regarding treatment plan can be considered as benefits to both the orthodontist and the patients.

The objective of this study was to compare the stability of Temporary Anchorage Devices injected with PRP and placebo (PPP).

## **MATERIAL AND METHODS**

A triple-blinded parallel arm randomized clinical trial using split-mouth technique was conducted at Islamic International Dental College, Orthodontic Department Islamabad, starting from April 2018 till February 2019. The sample size was 25 patients with 50 TADs, 2 in each patient. An ethical approval certificate from the board of studies of the university was received before the commencement of the research. All the patients from the OPD of the Orthodontic Department of Islamic International Dental Hospital who had visited for orthodontic treatment were screened as per inclusion criteria. Patients were diagnosed and planned based on history and clinical examination as well as radiographic interpretation. Informed consent was obtained from every patient willing to participate in the study.

Patients maintaining good oral hygiene, Class II Division I malocclusion, normal angle maxilla to mandibular plane MMA ( $25\pm 4$ ) requiring extraction of maxillary 1st premolars for retraction of incisal segments, mild to moderate crowding and no previous placement of TADs were included in the study.

Patients who were medically compromised or on any immunosuppressive drugs which may affect the treatment outcome had infection surrounding the TAD site and with a history of parafunctional habits/ bruxism were excluded from the study.

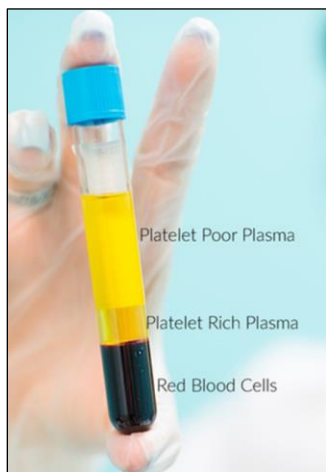Initially, alignment and levelling were done in all patients and when the treatment

progressed to (0.019" x 0.025") stainless steel wires, the patients were referred for extractions of maxillary 1st premolars. Immediately on the successive appointment after extractions of maxillary 1st premolars, TADs were inserted on a total of 25 patients on both right and left sides in the maxillary arch on the same appointment between the roots of 2nd premolar and 1st molars. TAD was directly loaded for retraction of interiors with a nickel-titanium coil spring (Ortho Care, Saltaire, United Kingdom) and the spring was extended between the hook of the canine bracket of the corresponding TAD.

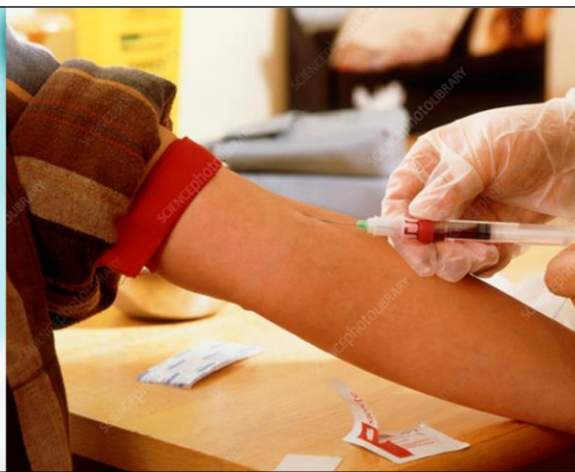All of the personal information of the participants and data related to the research was

stored in a departmental computer/desktop which could only be assessed by the researcher with a specific password and user name strictly known to the researcher.

Later 4 ml of venous blood was withdrawn by trained paramedical staff in the pathology lab of Islamic International Dental Hospital. Venous blood was withdrawn with a 21 gauge needle syringe from the antecubital region and was collected in a glass container (Vaculab) which contained the anti-coagulant Calcium Phosphate Dextrose A. The tube was placed into the centrifuge (SERICO:80-2) (Figures 1 and 3).



**Figure-1: Drawing of blood sample to produce PRP**



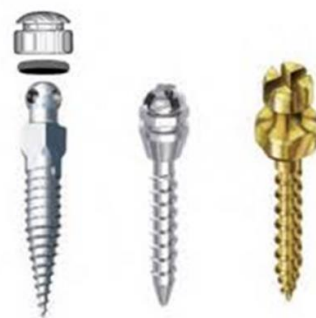**Figure-2: Test tube showing separated layers of platelet-poor plasma (PPP), PRP and RBCs**



**Figure-3: Centrifuge Machine**



**Figure-4: Orthodontic TAD**



**Figure-5: TADs of different lengths and diameters**



**Figure-6: Orthodontic force gauge (en-Orthodontic-Dontrix-Force-Gauge-1)**

The first centrifugation was done in the pathology lab for 10 minutes at 2,400 rpm. Three layers were formed because of differences in density. (Figure 2). The bottom layer consists of RBCs (red), the middle layer consists of mostly platelets and WBCs (straw-

coloured) and the top PPP (platelet-poor plasma) layer (light yellow).

The top PPP layer was removed from the glass tube and was taken in an 18-gauge needle syringe by the dental assistant and named X/Y for randomization. The Buffy coat layer (PRP) was then

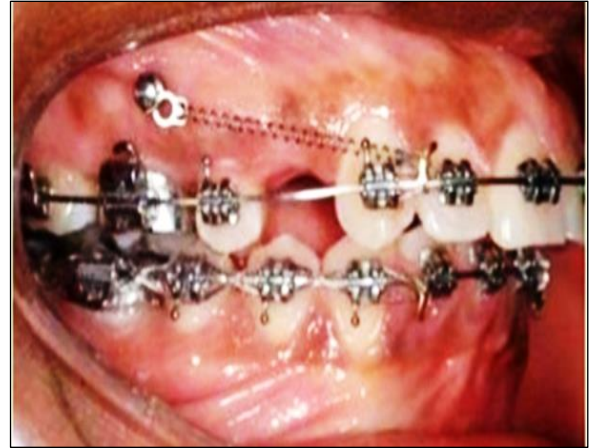transferred to another sterile tube containing 0.25 grams of calcium chloride with the help of an 18-gauge needle syringe. The second centrifugation was then done for 15 minutes at 3600 rpm to concentrate platelets (PRP) and then taken in an 18-gauge needle named X/Y by the assistant. (Figure 2)

TADs used were Titanium-aluminium Vanadium Alloy (Protect Orthodontic Mini Screw System) of length 8 mm and diameter of 1.6mm with a round tip, taper of 3 degrees and head of external hexagonal design (Figure 4 and 5). Other armamentarium used consisted of 18-gauge needle syringes, manual implant driver, nickel-titanium coil spring (Ortho Care, Saltaire, United Kingdom), orthodontic force gauge (en-Orthodontic-Dontrix-Force-Gauge-1) (Figure 6)

A few drops of local anaesthesia at TAD site were injected and a pilot hole of 2mm was drilled on both sides with the help of a manual implant driver just occlusal to the mucogingival junction in the maxilla on both left and right side of the patient between the roots of 2nd premolar and 1st molar with the help of the TAD tip at 90-degree angle to the long axis of the teeth. TADs were then removed anticlockwise.

Injection of PRP (Y) 0.25 ml which was a few drops was administered into the pilot hole by 18-gauge needle syringe and similarly injection of 0.25 ml of PPP (platelet poor plasma) (x) on the opposing side. TAD (Protect Orthodontic Mini Screw System) on both sides was inserted on the same day of PRP, PPP preparation and injection into the pilot hole. TADs were reinserted at an angulation of 45 degrees to the long axis of teeth into the same pilot holes. Periapical radiographs were then taken on both sides to make sure that there is no contact with the roots of adjacent teeth. Patients were advised to apply 0.25 percent chlorhexidine gel three times a day on and around the TAD.

TAD was directly loaded for retraction of interiors with a nickel-titanium coil spring (Ortho Care, Saltaire, United Kingdom) and the spring was extended between the hook of the canine bracket of the corresponding TAD. Incisors and canines were retracted by en masse retraction. (Figure7). After completion of en masse retraction, the maxillary incisors were tied together by long steel wires to prevent any midline deviation. The stability of TADs on both sides was compared by applying a force of 300gms on both sides with the help of a force measuring gauge (en-Orthodontic-Dontrix-Force-Gauge-1) to assess its stability on monthly appointments for 6 months. If any movement/loosening of TADs were noticed during the application of force, it was considered unstable. The patients were called for monthly appointments and TADs were assessed for stability.



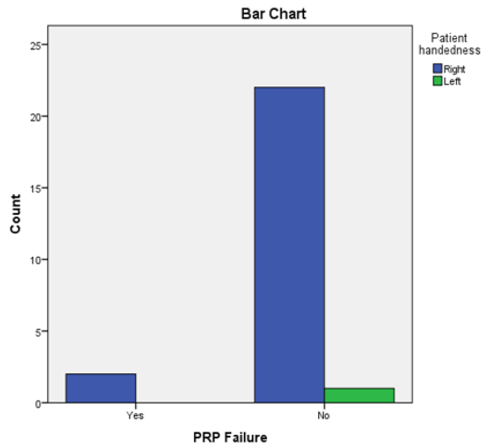
**Figure-7: TAD and Nickel-titanium coil spring for en masse retraction.**

Patients were also allowed to report back when he/she noticed any problem including the feeling of mobility of TADs. Those who were infected were excluded as per the criteria. Any loosening/mobility of TAD (that it cannot bear the loading forces of the retraction spring or the force gauge) was noted in the data. The duration from the date of insertion of TAD and the exact date of loosening was noted in several days. TADs that were not loosened were removed after 6 months of insertion.

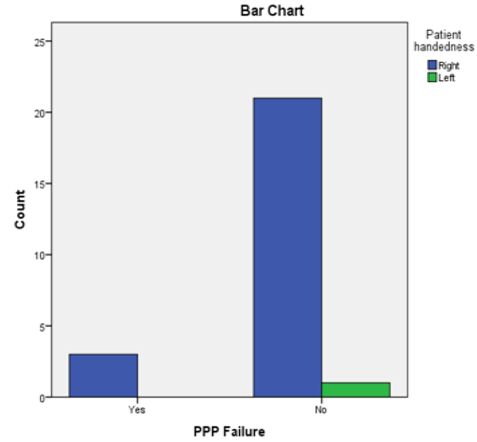
Data was put into a statistical Software called SPSS version 23(IBM, Armonk, NY) for Windows in which an arbitrary value of  $p \leq 0.05$  was considered significant. Frequency and percentage of gender and handedness were calculated. Being categorical variables the frequencies of failure rate in both PRP and PPP were calculated using the chi-square test and the mean standard deviation was calculated for the duration of TAD failures in each group of PPP and PRP. The difference between groups was calculated using an Independent T-test with confidence intervals of 95%. A  $p$ -value of  $\leq 0.05$  was taken as significant.

## RESULTS

The total patients were 25 with each patient receiving TAD on both right and left sides. Out of these 25 participants, 14 (56%) were males and 11 (44%) were females. Only one patient (4%) was left-handed and 24 (96%) were right-handed. Out of a total of 50 TADs, 5 (10%) failed in total .4 (8% of the total) on the left side and 1 (2% of the total) on the right side. In a total of 25 patients, only 1 (4%) patient showed both left and right-side failure while 4 (16%) patients showed only left side failure. Out of PPP and PRP groups, the rate of failure was 3 (12%) in PPP and 2 (8%) in PRP. The mean days of failure were  $46 \pm 3.2187$  and  $6.50 \pm 9.192$  for PPP and PRP respectively. (Figure 8, 9)



**Figure-8: TAD failure in right and left in the injection of PRP**



**Figure-9: TAD failure in the injection of PPP**

Two (8%) patients had only PPP (Placebo) failure, 1 (4%) patient had PRP failure and one had both PPP and PRP failure (Figure 12) (Table 1). There was no significant difference in terms of onset of failure in both PPP and PRP failure ( $p$ -value 0.15).

Out of the total injections of 50 of PPP/PRP, 3 (12.0%) failed in PPP and 2 (8.0%) failed in PRP. (22 in PPP (88%) and 23 (92%) in PRP did not show any failure. Statistical analysis showed no significant difference in TAD failure and injection of any PPP/PRP ( $p$ -value 0.6) (Table 1).

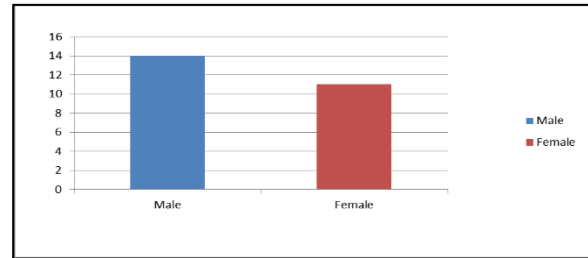
Out of 4 TAD failures, 3 (75%) were males and one (25%) was female ( $p$ -value 0.39). One female showed the failure of both-sided TADs (at 0- and 76-days intervals) while 3 males showed left TAD failure only after TAD insertion with mean days of  $25.00 \pm 21.65$  (Figure 10).

Out of 14 males, the rate of PPP failure was 14.3% (2 patients) while that of PRP was 7.1% (1 patient), In 11 female patients PPP failure was 9.1% (1 patient) and that of PRP was also 9.1% (1 patient).

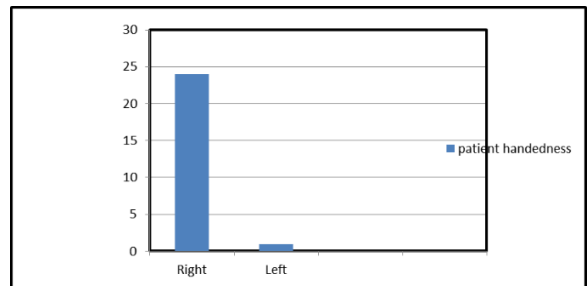
In males' the percentage of rate of failure between TADs injected with PRP and PPP was significant (difference of one patient, i.e., 7% but in females it was not statistically significant, i.e., 9.1% each ( $p$ -value of 0.68 and 0.86 respectively).

The mean failure in days of PPP TADs was  $46.00 \pm 32.187$  days and that in PRP were  $6.50 \pm 9.192$  =days (table 2). Our sample contained only 1 left-handed patient and that did not show any failure. All 4 TADS failed (16.7% in total handedness) were right-handed (table 4.8 and figure 4). Patient handedness was observed to notice any effect on the daily brushing forces which acted on the surface of TADs that can be a factor in TADs loosening. However, this variable proved to be insignificant as 24 out of a total 25 patients were right-handed.

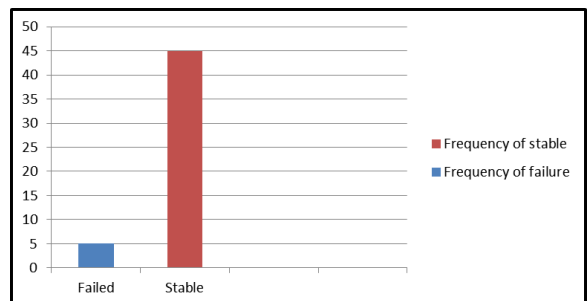
An Independent T-test was applied to show any difference in the groups. By comparing the mean of both failures in days, there are no significant differences between the two groups ( $p$ -value of 0.205).



**Figure-10: Frequency of Gender**



**Figure-11: Patient handedness**



**Figure-12: Frequency of Failure and stable TADs**

**Table-1: Overall failure of TADs with injections of PPP/PRP:**

			Injection of PPP/PRP		Total	p-value
			PPP	PRP		
TAD Failure	Yes	Count	3	2	5	0.636
		% within TAD Failure	60.0%	40.0%	100.0%	
		% within Injection of PPP/PRP	12.0%	8.0%	10.0%	
		% of Total	6.0%	4.0%	10.0%	
	No	Count	22	23	45	
		% within TAD Failure	48.9%	51.1%	100.0%	
		% within Injection of PPP/PRP	88.0%	92.0%	90.0%	
		% of Total	44.0%	46.0%	90.0%	

**Table 2. Independent Sample T-test; failure of TADs (Days)**

	Mean No of days(failed)	p-value
PRP	44.50±31.50	0.59
PPP	21.00±14.84	
Mean difference	23.50±30.31	

**DISCUSSION**

Reinforcing anchorage with the help of TADs in situations requiring large magnitude of forces for a variety of complex movements, dire need of different techniques needed to be introduced to enhance the stability of TADs. A variety of ongoing research has been carried out across the globe to enhance the stability of TADs. However, the utilization of growth factors in the form of PRP to enhance TAD stability has not been used till now. This research involved a comparison of the stability of TADs injected with PRP and placebo (PPP) at the site of TAD placement over six months.

Different variables were observed and hence recorded that can influence the outcomes of the study which included gender, number of days for failure of TADs and patient handedness. The study done on 25 patients with a total of 50 TADs resulted in 5(10%) TADs failing over 6 months. In PRP group number of TADs that failed was 2 (8%) and in the placebo (PPP) group it was 3 (12%). Whereas 22 in PPP (88%) and 23 (92%) in PRP did not show any failure. Statistical analysis showed no significant difference in TAD failure and injection of any PPP/PRP (p-value 0.6).

These results are consistent with the findings of the study carried out on humans by Monov in a split-mouth sketch clinical trial in which he observed no significant impact on bio-activated prosthetic implants with PRP in contrast to the control group.<sup>12</sup> No significant differences were found between the stability of implants measured between the 2 groups. Similarly, Wei-brich and Garcia in two alternate animal studies discovered no significant differences between prosthetic implants bioactivated with the help of PRP (test group) and control group in the level of bone-to-implant contact (BIC).<sup>13</sup>

Birang additionally in an interesting animal study showed no significant variations in the type of bone regeneration and trabeculae between implants treated with PRGF and the control group.<sup>14</sup>

Research was carried at the Department of Oral and Maxillofacial Surgery at Liaquat University of Medical and Health Sciences, Jamshoro/ Hyderabad to

evaluate the influence of platelet-rich plasma gel in bone regeneration after periapical cystic lesions. It was an experimental case series. PRP gel application was done on 45 patients having periapical cystic lesions. The size of the lesion was measured from radiographs with the help of a ruler at the 1st, 4th, 12th and 24th week respectively. It was observed that bone regeneration was approximately 95% after 24 weeks of PRP therapy. So it was concluded that platelet-rich plasma was very effective in the regeneration of cystic bony defect caused by enucleation of the periapical cyst.<sup>15</sup>

Research carried out on the rate of tooth movement by Eric J. W. Liou at the Department of Craniofacial Orthodontics, Chang Gung University, Taoyuan, Taiwan was done by administering sub mucosal injection of PRP for increasing the rate of orthodontic tooth movement along with preserving the pressure side of alveolar bone. It was observed clinically that PRP decreased the period for mandibular or maxillary alignment around 1.7 times faster on average and the increase in tooth movement was dose dependent on PRP. If PRP is administered in an optimal amount can lead to about 2 times (double) acceleration of orthodontic alignment which can range from 9.5 to 12.5 folds. It was also seen that PRP when injected on the pressure side reduced to about 71–77% of alveolar bone loss and this was also dose-dependent.<sup>16</sup>

Patient handedness was also noticed as this can affect the brushing technique, and the number of forces generated on the surfaces of left and right TADs and can influence TADs stability. Besides this, the differences in oral hygiene on the left and right side can also affect TAD stability. The right-handed person daily can have more aggressive brushing forces on the TADs placed on the left side than the TADs on the right side as compared to the left-handed person and vice versa. However, this variable proved to be insignificant as 24 out of a total 25 patients were right-handed.<sup>17</sup> The composition of PRP can vary from patient to patient and this variation in composition is also attributed to the different devices used to make it, the time factor and the most significant factor is the



technique of storage until used and its interaction with other materials during storage and preparation.

However, the evidence of the beneficial impacts of PRP in oral surgical procedures especially in orthodontics is considered to be insufficient. There is a huge room and requirement for many studies in the subject of orthodontics and specifically on the stability of TADs in future to explore what is not found.

The sample of the population was low<sup>25</sup> and thus the resulting failure rate in both cases of the PPP or PRP was low. All necessary data to obtain statistically significant results cannot be acquired with a small sample size.

Most of the patients undergoing orthodontic treatment were not willing to take part in the study due to fear of pain and anxiety and the selection of patients specifically requiring TADs in class II div I cases were also rare to find, financial restraints on the cost of TADs on a large sample size were the reasons of sample size being low. Differences in oral hygiene on the left and right side as well as the magnitude of brushing forces can affect TAD stability on the respective sides. As most of the patients were right-handed, this can also be considered as a limitation in this research.

Our results showed similarity with many other studies and also in contrast with others. There are slight drawbacks in the use of PRP however it can be used in many procedures and provide desired results. Further research is necessary to prove PRP as an effective adjunct to enhance TADs stability.

## CONCLUSION

It was concluded from this study that the sample size being small, no significant difference was found in the stability of TADs injected with PRP or placebo (PPP). Other factors such as gender, and patient or operator handedness were also found not significant.

## AUTHORS' CONTRIBUTION

NA: Write-up, data collection. OKD: Conceptualization and design. FI: Data analysis and proofreading. ZM: Literature search. IA: Critical review

## REFERENCES

1. Kravitz ND, Kusnoto B, Tsay TP, Hohlt WF. The use of temporary anchorage devices for molar intrusion. *J Am Dent Assoc* 2007;138(1):56–64.
2. Markic G, Katsaros C, Pandis N, Eliades T. Temporary anchorage device usage: a survey among Swiss orthodontists. *Prog Orthod* 2014;15(1):29.

3. Leo M, Cerroni L, Pasquantonio G, Condò S, Condò R. Temporary anchorage devices (TADs) in orthodontics: review of the factors that influence the clinical success rate of the mini-implants. *Clin Ter* 2016;167(3):70–7.
4. Takaki T, Tamura N, Yamamoto M, Takano N, Shibahara T, Yasumura T, *et al.* Clinical study of temporary anchorage devices for orthodontic treatment. *Bull Tokyo Dent Coll* 2010;51(3):151–63.
5. Fennis J, Stoelinga P, Jansen J. Mandibular reconstruction: a histological and histomorphometric study on the use of autogenous scaffolds, particulate cortico-cancellous bone grafts and platelet rich plasma in goats. *Int J Oral Maxillofac Surg* 2004;33(1):48–55.
6. Tripodi A. Thrombin Generation Assay and Its Application in the Clinical Laboratory. *Clin Chem* 2016;62(5):699–707.
7. Menezes LM, Rao J. Long-term clinical evaluation of platelet-rich plasma in the treatment of human periodontal intraosseous defects: A comparative clinical trial. *Quintessence Int* 2012;43(7):571–82.
8. Kumar KJ, Rao JB, Kumar BP, Mohan A, Patil K, Parimala K. A prospective study involving the use of platelet rich plasma in enhancing the uptake of bone grafts in the oral and maxillofacial region. *Int J Oral Maxillofac* 2013;12(4):387–94.
9. Bousnaki M, Bakopoulou A, Koidis P. Platelet-rich plasma for the therapeutic management of temporomandibular joint disorders: a systematic review. *Int J Oral Maxillofac* 2018;47(2):188–98.
10. Harnack L, Boedeker R, Kurtulus I, Boehm S, Gonzales J, Meyle J. Use of platelet-rich plasma in periodontal surgery—a prospective randomised double blind clinical trial. *Clin Oral Investig* 2009;13(2):179–87.
11. Marukawa E, Oshina H, Iino G, Morita K, Omura K. Reduction of bone resorption by the application of platelet-rich plasma (PRP) in bone grafting of the alveolar cleft. *J Craniomaxillofac Surg* 2011;39(4):278–83.
12. Monov G, Fuerst G, Tepper G, Watzak G, Zechner W, Watzek G. The effect of platelet-rich plasma upon implant stability measured by resonance frequency analysis in the lower anterior mandibles: A pilot study. *Clin Oral Implants Res* 2005;16(4):461–5.
13. Garcia RV, Gabrielli MAC, Hochuli-Vieira E, Spolidorio LC, Filho JGP, Neto FAD, *et al.* Effect of platelet-rich plasma on peri-implant bone repair: a histologic study in dogs. *Oral Implantol* 2010;36(4):281–90.
14. Birang R, Torabi A, Shahabooei M, Rismanchian M. Effect of plasma-rich in platelet-derived growth factors on peri-implant bone healing: An experimental study in canines. *J Dent Res* 2012;91(1):93–9.
15. Nankani S, Punjabi SK, Khawaja N, Shams S. Efficacy of Platelet Rich Plasma (PRP) Gel in Bone Regeneration of Periapical Cystic Lesion. *J Bio Sci* 2020;2(3):379–83.
16. Liou EJ. The development of submucosal injection of platelet rich plasma for accelerating orthodontic tooth movement and preserving pressure side alveolar bone. *APOS Trends Orthod* 2016;6(1):5–11.
17. Tezel A, Orbak R, Çanakçı V. The effect of right or left-handedness on oral hygiene. *Int J Neurosci* 2001;109(1-2):1–9.

Submitted: January 15, 2024

Revised: February 19, 2024

Accepted: February 26, 2024

## Address for Correspondence:

Owais Khalid Durrani, Department of Orthodontics, School of Dentistry, SZAMBU, Islamabad-Pakistan

Cell: +92 333 911 4500

Email: drowais@szambu.edu.pk