

CASE REPORT

ANGIOFIBROMA IN A 50-YEAR-OLD PATIENT

Syed Shahmeer Raza, Syed Muhammad Owais, Salman Zahid**, Ihtisham Ul Haq***, Haris Manan, Syeda Fizza Qasim*, Farhan Ullah**, Asfandiar Shahrukh Hijazi*, Osamah Riaz Khan

Department of Medicine, *Department of Surgery, Hayatabad Medical Complex, Peshawar, **Department Medicine, ***Department of ENT, Khyber Medical College, Peshawar-Pakistan

Juvenile Angiofibroma (JNA) is a benign tumour that tends to bleed and occur in the nasopharynx with most cases occurring in pre-pubertal and adolescent males 10–20 years. We present the case of a 50-year-old male shopkeeper who consulted the ENT out patients' department (OPD) of Khyber Teaching Hospital (KTH) with the chief complaint of right sided nasal obstruction for the last 2.5 months which was associated with two episodes of epistaxis and diplopia which started 2 months back. He complained of right sided frontal and periorbital pain for the last 15 days. Past medical and surgical history was insignificant. Computerized Tomography (CT) scan without contrast and magnetic resonance imaging (MRI) showed finding consistent with a pedunculated tumour like growth. After baseline investigations, surgery was done and a Wilson's incision was given and the mass was excised and sent to the lab for histopathological report which showed angiofibroma. The age of the patient shows that this is a very rare case of angiofibroma. Dissection of such tumours is important as they have propensity to bleed. Excision along with biopsy is the method of choice. Proper surgical techniques and use of better medical technology are required to make and early diagnosis. Further studies/case reports around the world would assert our findings that a nasopharyngeal angiofibroma can also be found in middle aged men.

Keywords: Nasopharyngeal Angiofibroma; Nasopharynx; Nasal obstruction; Wilson's Incision

J Ayub Med Coll Abbottabad 2017;29(3):499–501

INTRODUCTION

The Benign tumour JNA accounts for 0.05% of all head and neck tumours. A frequency of 1:5,000–1:60,000 in otolaryngology patients have been reported. JNA occurs exclusively in males. Females with JNA should undergo genetic testing. Onset is most commonly in the second decade; the range is 7-19 years. JNA is rare in patients older than 25 years.¹⁻³

CASE REPORT

A 50-year-old male shopkeeper who consulted the ENT out patients' department (OPD) of Khyber Teaching Hospital (KTH) with the chief complaint of right sided nasal obstruction for the last 2.5 months which was associated with two episodes of epistaxis and diplopia which started 2 months back. He complained of right sided frontal and periorbital pain for the last 15 days. Past medical and surgical history was insignificant. There was no associated pain, fever, dysphagia, dyspnoea, hoarseness, difficulty in chewing, and epistaxis.

There was no history of Hypertension, Diabetes, smoking and chewing tobacco. His family history was negative for tumours of head and neck.

Computerized Tomography (CT) scan without contrast of the paranasal sinuses, brain and orbits showed a large polypoid soft tissue density mass obscuring the right posterior nasal cavity as well as bulging into the medial aspect of right maxillary sinus. The mass is also projecting in the

posterior nasal sinus on the right side. Obliteration of Eustachian tubes was noted on both sides which was more on the right side. (Figure-1a & 1b) A contrast enhanced MRI brain with paranasal sinuses was recommended for detailed evaluation.

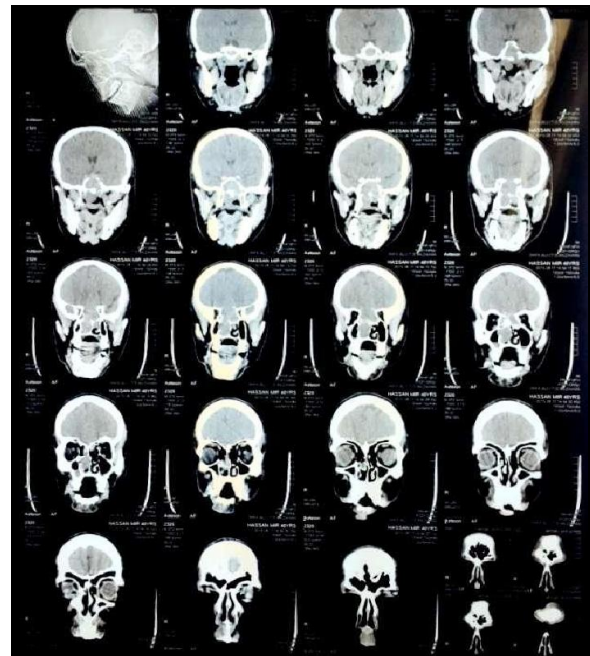


Figure-1a: Computerized Tomography (CT) scan without contrast of the paranasal sinuses, brain and orbits.

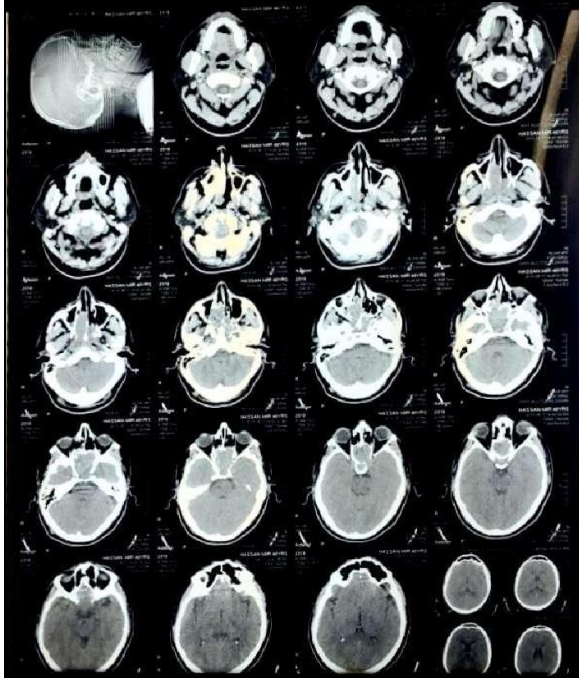

Figure-1b: Computerized Tomography (CT) scan without contrast of the paranasal sinuses, brain and orbits

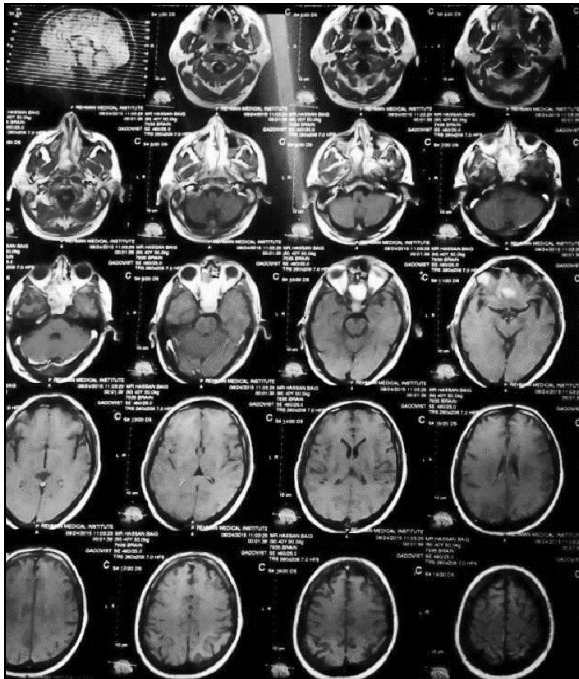


Figure-2: The magnetic resonance imaging (MRI) showed a significantly enhancing lobulated mass lesion filling sphenoidal sinus, nasopharynx, nasal cavity and posterior ethmoidal air cells

The magnetic resonance imaging (MRI) showed a significantly enhancing lobulated mass lesion filling sphenoidal sinus, nasopharynx, nasal cavity and

posterior ethmoidal air cells with extension into pituitary fossa, clivus, left pterygoid compartment and small extension up to right orbital apex and superiorly extending up to anterior cranial fossa floor – neoplastic lesion. Report was to be correlated with Histopathological findings. (Figure-2)

After baseline investigations, surgery was carried out and a Wilson’s incision was given, Palatal mucosa and Periosteum were elevated, extension of the mass could be seen into the cranium, intracranial mass was also plucked out, palate was sutured in layers and excised mass was sent to the lab for histopathological report which showed findings consistent with JNA.

DISCUSSION

Nasopharyngeal angiofibroma also called juvenile nasopharyngeal angiofibroma-JNA is a histologically benign but locally aggressive vascular tumour that grows in the back of the nasal cavity. It most commonly affects adolescent males. The disease was exclusive to adolescent males hence it was also called juvenile nasopharyngeal angiofibroma.^{4,5}

Unilateral nasal obstruction and epistaxis are usual symptoms encountered in these patients raise the suspicion of this tumour. Secondary to the blockage of sinuses, headache may ensue. Alterations in the vision may also be seen.¹

Bleeding is one of the serious complications encountered during surgery for tumour resection for which Preoperative embolization is recommended. Onyx, Polyvinyl-alcohol particles and Microcatheters have been used in recent past to reduce bleeding.⁶⁻⁹

Surgical Resection is the mainstay of treatment. different surgical approaches ranging from endoscopic techniques, Trans-palatal, transpharyngeal, trans-facial through lateral rhinotomy, midfacial degloving to Le Fort I osteotomy are proposed. the advances in the field of surgery have made it possible for surgeons to use better endoscopic techniques.¹⁰

Our patient is the first case according to our knowledge which has defied the age bracket mentioned for angiofibroma and the biopsy report confirmed our findings. Further studies/case reports around the world would assert our findings that a nasopharyngeal angiofibroma can also be found in middle aged men.

REFERENCES

1. Lund VJ, Stammberger H, Nicolai P, Castelnuovo P, Beal T, Beham A, *et al.* European position paper on endoscopic management of tumours of the nose, paranasal sinuses and skull base. *Rhinol Suppl* 2010;(22):1–143.
2. Schiff M, Gonzalez AM, Ong M, Baird A. Juvenile nasopharyngeal angiofibroma contain an angiogenic growth factor: basic FGF. *Laryngoscope* 1992;102(8):940–5.

3. Martin H, Ehrlich HE, Abels JC. Juvenile nasopharyngeal angiofibroma. *Ann Surg* 1948;127(3):513–36.
4. Sivanandan R, Fee WW. Benign and malignant tumors of the nasopharynx. In: Cummings CW, Haughey BH, Harker LA, editors. *Cummings Otolaryngology: Head and Neck Surgery*. Philadelphia, PA: Mosby; 2004. p.1669–84.
5. Jacobsson M, Petruson B, Svendsen P, Berthelsen B. Juvenile nasopharyngeal angiofibroma: A report of eight cases. *Acta Otolaryngol* 1988;105(1-2):132–9.
6. Midilli R, Karci B, Akyildiz S. Juvenile nasopharyngeal angiofibroma: analysis of 42 cases and important aspects of endoscopic approach. *Int J Pediatr Otorhinolaryngol* 2009;73(3):401–8.
7. Enepekides DJ. Recent advances in the treatment of juvenile angiofibroma. *Curr Opin Otolaryngol Head Neck Surg* 2004;12(6):495–9.
8. Khan MN, Raza SS, Zaidi SA, Hussain AK, Nadeem MD, Farid K. Pleomorphic adenoma of minor salivary glands. *J Ayub Med Coll Abbottabad* 2016;28(3):620-2.
9. Herman B, Bublik M, Ruiz J, Younis R. Endoscopic embolization with onyx prior to resection of JNA: a new approach. *Int J Pediatr Otorhinolaryngol* 2010;75(1):53–6.
10. Yiotakis I, Eleftheriadou A, Davilis D, Giotakis E, Ferekidou E, Korres S, *et al.* Juvenile nasopharyngeal angiofibroma stages I and II: a comparative study of surgical approaches. *Int J Pediatr Otorhinolaryngol* 2008;72(6):793–800.

Received: 19 December, 2016

Revised: 26 January, 2017

Accepted: 14 February, 2017

Address for Correspondence:

Syed Shahmeer Raza, House Officer, Medicine B Ward, Hayatabad Medical Complex, Peshawar-Pakistan

Cell: +92 305 900 6082

Email: shamir.raza@gmail.com