

## ORIGINAL ARTICLE

## ANTI-ARTHRITIC EFFECT OF THYMOQUINONE IN COMPARISON WITH METHOTREXATE ON PRISTANE INDUCED ARTHRITIS IN FEMALE SPRAGUE DAWLEY RATS

Rizwan Faisal, Nisar Ahmad\*, Yahya Saleem Fahad\*\*, Sadia Chiragh\*\*\*

Pharmacology department, Rehman Medical College, Peshawar, \*Pharmacology Department, Ayub Medical College, Abbottabad, \*\*Govt. Saidu Hospital, King Edward Medical University, Lahore, \*\*\*Pharmacology Department, Post Graduate Medical Institute Lahore-Pakistan

**Background:** Rheumatoid arthritis inflammatory joint disease which is chronic in nature. Since long various researches are carried out to find the remedy of this disease but still a lot of work needed to be done. **Methods:** This comparative study was performed from March to August 2013 at Postgraduate Medical Institute, Lahore. A total of thirty-two female Sprague-Dawley rats were randomly divided into four equal groups (n=8); group A was kept as healthy control, group B was kept as positive control, group C was treated with thymoquinone and group D was treated with methotrexate. Arthritis developed within two weeks in group B, group C and group D after giving a single shot of pristane intradermally. Treatment was started on day 15. At day 30 (time of dissection) paw weight and histopathological sections of ankle joints of all the animals were taken. **Results:** The results shown significant rise in paw weight and score of histopathological parameters in group B, group C and group D when compared with healthy control rats. Thymoquinone and methotrexate treated groups shown reduction in paw weight and score of histopathological parameters when compared to positive control rats with *p*-value 0.001 each. The difference between groups C and D was insignificant (*p*-value 0.062). **Conclusion:** Study results supported the anti-inflammatory and disease modifying activities of thymoquinone as it significantly reduces both paw weight and histological parameters of joint inflammation.

**Keywords:** Thymoquinone; Pristane; Paw weight; Joint histopathology; Rheumatoid arthritis; Methotrexate

**Citation:** Faisal R, Ahmad N, Fahad YS, Chiragh S. Anti-arthritis effect of thymoquinone in comparison with methotrexate on pristane induced arthritis in female Sprague dawley rats. J Ayub Med Coll Abbottabad 2018;30(1):3-7

### INTRODUCTION

Rheumatoid arthritis (RA) is an inflammatory disorder which mainly involves joints of the body especially the foot or ankle (90%). Mostly it affects toes and forefeet initially followed by hind feet or back of the feet and lastly the ankles.<sup>1</sup> Usually joints of both sides are involved equally.<sup>2</sup> Symptoms related to foot and ankles are the initial signs of RA in about 20% of the cases.<sup>3</sup>

The exact etiology of RA is still unclear but association of various factors are shown to play an important role. Some people may suffer from the disease because of their genetic predisposition. Others have shown stimulation of the disease due to environmental and chemical triggers.<sup>1</sup> Its linkage with hormonal changes have also proved.<sup>3</sup> Most of the researches believe that in RA the culprit is the immune system of the body which starts attacking the joints itself rather than providing protection.<sup>1</sup>

Rheumatoid arthritis being an inflammatory disorder leads to inflammation of the synovium of joints especially those of hands and feet. Inflammatory signs can include tenderness, swelling, reddish discoloration, and warmth around the affected joints. Certain cases with chronic inflammation may result in bone and cartilage destruction, ultimately leading to joint

destruction permanently. Deformity and disability could be the other outcomes of chronic inflammation.<sup>4</sup>

Now a day's various medication is available for the treatment of RA like non-steroidal, steroidal anti-inflammatory (NSAIDs), disease modifying anti-rheumatic (DMARDs), immunomodulators and immunosuppressant drugs. Among DMARDs, methotrexate (MTX) remains the corner stone for treating rheumatoid arthritis. These drugs where provide relief to patients, also produce certain adverse effects including disorders of gastrointestinal system, suppression of immune system, loss of hairs and increase chances of infections. Even after getting the treatment, the disease pattern after certain years in patients of RA is as follows; complete remission in 25% of patients, moderate impairment in 40% of patients, severe disability in 25% of patients and 10% of patients are severely crippled.<sup>5</sup> Thymoquinone (TQ), which is an active principal of a plant named *Nigella Sativa* has been used since long for the cure of several disorders. In Southern Asia, its name is *Kalonji*, in Arabic it is known as *Habat-ul-sauda* and in its English name is Black Cumin.<sup>6</sup> It has antioxidant effects<sup>7</sup>, has anti-bacterial activity<sup>8</sup>, anti-inflammatory action<sup>9</sup>, anti-tussive effect<sup>10</sup>, anti-asthmatic effect<sup>11</sup>, and antidiabetic effect<sup>12</sup>. TQ has

shown to reduce clinical score of inflammation and inflammatory cell count in blood of pristane induced arthritic rats.<sup>13</sup> The aim of this study was to explore the disease modifying action of TQ by observing paw weight and histopathological parameters. Methotrexate was taken as standard for comparison.

**MATERIAL AND METHODS**

This comparative study was performed from March to September 2013 at Post Graduate Medical Institute Lahore, after the approval from the ethical committee and is an extension of our previously published article which focused on joint inflammation and presence of inflammatory cells in blood.<sup>13</sup> Now we focused on paw weight and histopathological changes in joints of same animals. Thirty-two female Sprague Dawley rats (120–220 g in weight) were kept under standard conditions in the animal house of P.G.M.I, Lahore. They were given free access to water and food and acclimatized for 7 days. Four groups of rats as group A, group B, group C and group D were made, each group comprising of eight rats after randomization. Power and precision 3.0 software was used for calculating sample size.<sup>14</sup>

Arthritis was produced within 15 days in all the animals of groups B, C and D after a single shot of 0.5ml of pristane at tail base.<sup>15</sup> From day 15 till day 30; group A and B were given 1ml/kg of distilled water, group C and D received 2 mg/ml/kg of thymoquinone and 0.5 mg/ml/kg of methotrexate respectively by intraperitoneal injections.<sup>16</sup> Both thymoquinone (Sigma-USA) and methotrexate (GSK) were taken from local market.

Body weight and clinical score of inflammation were accessed on alternate days. Animals were euthanized on 30<sup>th</sup> day of study and both hind paws were removed and weighed. Ankles were embedded in paraffin after fixing in formalin solution (10% neutral buffered). Sections were cut in various slices having thickness of 6 um and examined under microscope after staining with hematoxylin-eosin for perivascular inflammatory cell infiltrate in synovium, morphological changes including synovial cell hyperplasia and proliferation, villous hyperplasia and pannus formation. The scores of four histological criteria were:

- (1) Inflammatory cells infiltrate as the degree of infiltration by mononuclear cells categorized as 0 to 3; 0 = normal, 1 = mild, 2 = moderate, 3 = severe
- (2) Synovial lining hyperplasia categorized as 0–2 (the layers being counted from the surface of the membrane to the sub-synovial tissue); 0 = 1–3 layers of cells, 1 = 4–6 layers of cells, 2 = 7 or more layers of cells
- (3) Villous hyperplasia graded from 0–3; 0 = not present, 1 = few, scattered and short, 2 = marked and finger like, 3 = marked and diffuse
- (4) Pannus formation graded from 0–3; 0 = absent, 1 = mild to moderate synoviocyte

proliferation and invasion into cartilage or bone, 2 = severe synoviocyte and some inflammatory cell invasion into cartilage or bone, 3 = marked synoviocyte and inflammatory cell invasion into cartilage or bone.<sup>17</sup> Zero was the minimum and 3 was maximum score for one limb, the score of 2 limbs was collectively taken so it became as minimum score = 0 and maximum = 6. It was then graded as 0 = normal, 1-2 = mild, 3 = moderate, 4–6 = severe. Data was analyzed by using SPSS 20.0 software. Data following normal distribution and having homogeneity of variances (paw weight) was compared by one-way ANOVA, and *post hoc* analysis was done by Tukey’s test. Data which deviates from normality and homogeneity (histological parameters) was compared by Kruskal Wallis Test, *post hoc* analysis in this case was done by Mann Whitney U test. A p-value of less than 0.05 was considered statistically significant.

**RESULTS**

Results of clinical score of inflammation and body weight were published in our previous article. Inflammation increased in pristane treated rats reaching maximum till 15 days and it was reduced at end of experiment in both treatment groups (Table-1). Body weight decreased in pristane treated rats till day 15. It continued decreasing in placebo treated group and increased in drug treated groups.

The weight of both hind paws was compared when the study was ended. It was lowest in group A (negative control) and highest in group B (positive control). Paw weight of both group C (TQ treated) as well as D (MTX treated) was in between healthy and positive control. (Table-2).

**Table-1: Effect of thymoquinone and methotrexate on clinical score of inflammation (mean±SD) of pristane induced arthritic rats**

Group Day	A	B	C	D
Day 0	0±0	0±0	0±0	0±0
Day 15	0±0	16±0	16±1	16±0
Day 30	0±0	15±1	5±2***	4±1***

\*\*\* p- value < 0.001 vs group B (data published previously)<sup>13,15</sup>

**Table-2: Effect of thymoquinone and methotrexate on weight of both hind paws (grams) of pristane induced arthritic rats (n=8) and p-value calculated by ANOVA.**

Group	Mean±SD	p-value
A	3.03±0.08	< 0.001
B	4.37±0.47	
C	3.75±0.16***###	
D	3.65±0.40*** ##	

\*\*\*p ≤ 0.001, \*\*p ≤ 0.01 vs group B, ###p ≤ 0.001, ##p ≤ 0.01 vs group A (Tukey’s test)

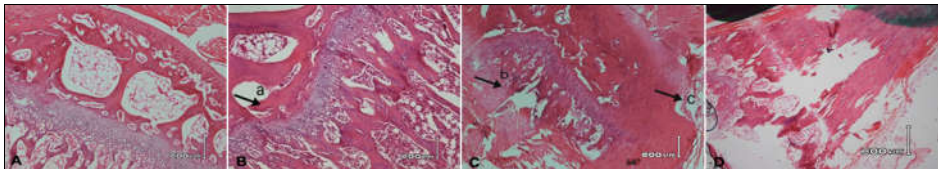
Histologically there was no inflammation in group A, marked in group B, moderate in group C and mild in

group D. (Figure-1) Inflammatory cells were absent in group A. In group B; 12.5% cases were mildly, 12.5% were moderately and 75.0% were severely inflamed. Most of the cases (62.5%) in group C were mildly while 37.5% were moderately inflamed. In group D 12.5% had no inflammation, 75.0% had mild and 12.5% had moderate inflammation. Synovial hyperplasia was absent in group A. 12.5% cases in group B had mild, 62.5% had moderate and 25.0% had severe synovial hyperplasia. Group C had 87.5% cases with mild and 12.5% with moderate synovial hyperplasia. Group D had none (12.5%) to mild (87.5%) synovial hyperplasia. Villous hyperplasia was also absent in group A. In group B, 12.5% cases were having mild, 75.0% moderate and 12.5% were having severe villous hyperplasia. Most of the cases (62.5%) of group C had villous hyperplasia of mild nature with (12.5%) of moderate and 25% cases without hyperplasia. In group D majority 75.0% had mild hyperplasia with 25% cases without hyperplasia. Pannus formation was also absent in group A. In group B, 12.5% cases were having mild, 50.0% were having moderate and 37.5% were having severe pannus formation. Although both in group C and D all (100.0%) cases had mild pannus formation but it was a bit more reduced in group C than group D. Comparison of the histological parameters among groups shown significant difference for inflammatory cells, synovial hyperplasia, villous hyperplasia and pannus formation with  $p$ -value  $<0.001$  each. Multiple comparisons of inflammatory cells score among groups showed that groups B, C and D had significantly high

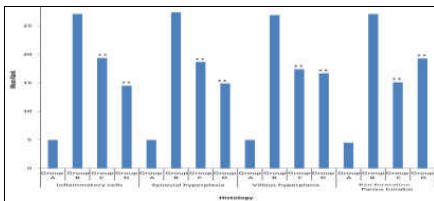
score when compared with group A having  $p$  values  $<0.001$ ,  $<0.001$  and  $0.001$  respectively. Similarly, groups C and D had significantly low score when comparison was made with group B with  $p$ -values  $0.006$  and  $0.003$  respectively. The difference between groups C and D was insignificant ( $p$ -value  $0.062$ ).

Comparison of the score of synovial hyperplasia among various groups revealed significant difference of groups B, C and D when compared with group A with  $p$ -values  $<0.001$ ,  $<0.001$  and  $0.001$  respectively. Groups C and D had significantly low score when compared with group B ( $p$ -values  $0.004$  and  $0.001$  respectively). However, the difference was insignificant between groups C and D with  $p$ -value  $0.158$ . Multiple comparisons of score of villous hyperplasia among groups showed that groups B, C and D had significantly high score when compared with group A with  $p$ -values  $0.001$ ,  $0.004$  and  $0.046$  respectively. The difference between groups C and D was found to be insignificant however these two groups had significantly less score of villous hyperplasia when compared with group B with  $p$ -value  $0.004$  each.

Comparison of the score of pannus formation among various groups showed that groups B, C and D had significantly high score when compared with group A, all with  $p$ -values  $<0.001$ . Group C had significantly low score of pannus formation when compared with group D ( $p$ -value  $0.046$ ) but these two groups had significantly low score when compared with group B with  $p$ -values  $0.002$  and  $0.006$  respectively (Figure-2).



**Figure-1: A (Negative Control) Normal joint of healthy control rats. B (Positive control) PIA rats showing (a) pannus formation. C (TQ treated group) PIA rats after treating with TQ showing reduced (b) inflammatory cell infiltration and (c) synovial hyperplasia. D (MTX treated group) PIA rats after treating with MTX showing approach towards normal histology**



**Figure-2: Graphical presentation of histological parameters among four groups (n=8)**

$p$ -value for all four histological parameters is  $< 0.01$  group C and D Vs B, \*\*  $p$ -value =  $0.04$  group C Vs D

## DISCUSSION

Pristane induced arthritis is a useful model to study effect of anti-arthritis drugs. It involves large joints, causes severe inflammation and disease closely resembles rheumatoid arthritis.<sup>17</sup> In the present study arthritis was monitored by paw weight and histological parameters. The induction of arthritis was associated with increase in paw weight and changes in histological parameters. Both the standard drug methotrexate and test compound TQ significantly suppressed inflammation as seen from

the significant decrease in paw weight and improvement in histological parameters. As compared to pristane group paw weight was less in TQ treated rats with  $p$ -value  $<0.01$  and in methotrexate treated rats with  $p$ -value  $<0.001$ . Alam and Galav administered 5 mg/kg of TQ to Freund's adjuvant induced arthritic rats and observed significant decrease in paw volume with  $p$ -value  $<0.001$ .<sup>18</sup> Histological parameters in this study were presence of inflammatory cells, synovial and villous hyperplasia and pannus formation. They were markedly reduced by treatment with both drugs. When comparison was made between TQ and methotrexate it was observed that changes in histological parameters were statistically insignificant in both groups except pannus formation where the comparison was found significant between the two groups. Many studies have been carried out on TQ in order to explore its anti-inflammatory effects.

Umar and co-workers assessed the anti-inflammatory effect of TQ in arthritic rats. The efficacy of TQ in arthritic rats were evaluated by inflammatory mediators (IL-1 $\beta$ , TNF- $\alpha$ , IL-6, IL-10, IFN- $\gamma$  and PGE<sub>2</sub>), biochemical (articular elastase, LPO, MPO, GSH, catalase, SOD and NO), and histological studies in joints. TQ was found to be effective in producing significant changes in almost all the parameters. Histologically cellular infiltration, cartilage erosion, pannus formation and bone resorption were studied and they were restored markedly by TQ treatment<sup>19</sup>, supporting the present study.

In another study the preventive effects of TQ against joint damage and inflammatory mediators in rat model of RA were evaluated. Arthritis was monitored by the presence of mononuclear cells, pannus formation, and elevation of clinical scoring, IL-1 $\beta$ , and TNF- $\alpha$ . Induction of arthritis significantly elevated almost all the parameters. TQ significantly reduced the presence of mononuclear cells, pannus formation and reduction in clinical scoring, IL-1 $\beta$ , and TNF- $\alpha$ .<sup>20</sup>

Sajjad and colleagues studied the anti-inflammatory effects of TQ in rat model of RA. The anti-inflammatory effects were monitored by various inflammatory mediators, clinical scoring of inflammation and histological studies in joints. Levels of inflammatory mediators were significantly reduced after oral administration of TQ. Decrease in bone histology and clinical scoring also verified the protective effects of TQ against RA.<sup>21</sup>

In summary thymoquinone has got disease modifying and anti-inflammatory effects

comparable to methotrexate in pristane induced arthritis in rats.

## CONCLUSION

Results confirm the anti-arthritic effect of thymoquinone as it is found effective in reducing paw weight and improving histological changes in rat model of rheumatoid arthritis. Our results might contribute to treatment of rheumatoid arthritis if followed by human studies

**Conflict of interest:** No conflict of interest exists

## Acknowledgments

The study was financed by Post Graduate Medical Institute Lahore. We are highly grateful to the staff of animal house and Histopathology Department for their cooperation and guidance in making this study feasible.

## AUTHORS' CONTRIBUTION

RF & SC conceived, designed and did statistical analysis, editing & critical review of manuscript. RF, NA and YSF did data collection, manuscript writing and critical review. SC did review and drafting and final approval of manuscript.

## REFERENCES

- Anish R. Rheumatoid Arthritis of the Foot and Ankle [Internet]. Orthoinfo. American Academy of Orthopaedic Surgeons [cited 2017 Feb 12]. Available from: <https://orthoinfo.aaos.org/en/diseases--conditions/rheumatoid-arthritis-of-the-foot-and-ankle>
- Gordon A. Rheumatoid arthritis: MedlinePlus Medical Encyclopedia [Internet]. [cited 2017 Feb 12]. Available from: <https://medlineplus.gov/ency/article/000431.htm>
- Rheumatoid Arthritis of the Foot and Ankle. [Internet]. American Orthopaedic Foot & Ankle Society. [cited 2017 Feb 12]. Available from: <http://www.aofas.org/footcarerem/conditions/ailments-of-the-midfoot/Pages/Rheumatoid-Arthritis.aspx>
- Anonymous. Rheumatoid Arthritis in the Foot and Ankle. What is rheumatoid arthritis. [Internet]. Foot Health Facts, American College of Foot and Ankle Surgeons. [cited 2017 Feb 12]. Available from: <https://www.foothealthfacts.org/conditions/rheumatoid-arthritis-in-the-foot-and-ankle>
- Danish I, editor. Medical Diagnosis and Management. 8<sup>th</sup> ed. Karachi: Johar Publications; 2010.
- Gillani AU, Jabeen Q, Khan MA. A review of medicinal uses and pharmacological activities of *Nigella sativa*. Pak J Biol Sci 2004;7(4):441–51.
- Ragheb A, Attia A, Eldin WS, Elbarby F, Gazarin S, Shoker A. The protective effect of thymoquinone, an anti-oxidant and anti-inflammatory agent, against renal injury: a review. Saudi J Kidney Dis Transpl 2009;20:741–52.
- Chaieb K, Kouidhi B, Jrah H, Mahdouani K, Bakhrouf A. Antibacterial activity of thymoquinone, an active principle of *Nigella sativa* and its potency to prevent bacterial biofilm formation. BMC Complement Altern Med 2011;11:29.
- El-Mezayen R, El-Gazzar M, Nicolls MR, Marecki JC, Dreskin SC, Nomiyama H. Effect of thymoquinone on cyclooxygenase expression and prostaglandin production in a mouse model of allergic airway inflammation. Immunol Lett 2006;106(1):72–81.

10. Hosseinzadeh H, Eskandariz M, Ziaeez T. Antitussive effect of thymoquinone, a constituent of *Nigella Sativa* seeds, in guinea pigs. *Pharmacologyonline* 2008;2:480-4.
11. Amira E, Abdel A, Nesrine S, El-Sayed, Laila G, Mahran. Anti-asthmatic and anti-allergic effects of thymoquinone on airway-induced hypersensitivity in experimental animals. *Pak J Pharm Sci* 2011;1:109-17.
12. Pari L, Sankaranarayanan C. Beneficial effects of thymoquinone on hepatic key enzymes in streptozotocin-nicotinamide induced diabetic rats. *Life Sci* 2009;85(23-26):830-34.
13. Faisal R, Chiragh S, Popalzai AJ, Khalil Ur Rehman. Anti-inflammatory effect of thymoquinone in comparison with methotrexate on pristane induced arthritis in rats. *J Pak Med Assoc* 2015;65(5):519-25.
14. Faisal R, Imran U. Comparative evaluation of thymoquinone and methotrexate in lung inflammation in murine model of rheumatoid arthritis. *J Postgrad Med Inst* 2015;29(2):88-92.
15. Faisal R, Gul M, Anwar A. Low doses of pristane in comparison with high doses in induction of arthritis in female-sprague dawley rats. *Khyber Med Univ J* 2016;8(4):185-8.
16. Faisal R, Shinwari L, Jehangir T. Comparison of the therapeutic effects of thymoquinone and methotrexate on renal injury in pristane induced arthritis in rats. *J Coll Physicians Surg Pak* 2015;25(8):597-601.
17. Vingsbo C, Sahlstrand P, Brun JG, Jonsson R, Saxne T, Holmdahl R. Pristane-induced arthritis in rats: A new model for rheumatoid arthritis with a chronic disease course influenced by both major histocompatibility complex and non-major histocompatibility genes. *Am J Pathol* 1996;149(5):1675-83.
18. Alam M, Galav V. Anti-inflammatory effect and toxicological evaluation of thymoquinone (volatile oil of black seed) on adjuvant-induced arthritis in Wistar rat. *Indian J Life Sci* 2013;2(2):17-22.
19. Umar S, Zargan J, Umar K, Ahmad S, Katiyar C, Khan H. Modulation of the oxidative stress and inflammatory cytokine response by thymoquinone in the collagen induced arthritis in wistar rats. *Chem Biol Interact* 2012;197(1):40-6.
20. Tekeoglu I, Dogan A, Ediz L, Budancamanak M, Demirel A. Effects of thymoquinone (volatile oil of black cumin) on rheumatoid arthritis in rat models. *Phytother Res* 2007;21(9):895-7.
21. Sajad M, Asif M, Umar S, Zargan J, Rizwan M, Ansari SH, *et al.* Amelioration of inflammation induced oxidative stress and tissue damage by aqueous methanolic extract of *Nigella sativa* Linn. in arthritic rats. *J Complement Integr Med* 2007;7(1):1-21.

Received: 3 June, 2017

Revised: --

Accepted: 12 November, 2017

**Address for Correspondence:**

**Dr. Rizwan Faisal**, Associate Professor, Pharmacology Department, Rehman Medical College, Peshawar-Pakistan

**Cell:** +92 333 912 0587

**Email:** Rizwan.faisal@rmi.edu.pk