

CASE REPORT

TUBERCULOUS GRANULOMA ON BONE MARROW TREPINE

Farheen Karim, Hira Qadir

Department of Pathology and Laboratory Medicine, Aga Khan University Hospital, Karachi-Pakistan

Bone marrow examination is a useful tool for diagnosis of many diseases. The utility of bone marrow examination in workup of pyrexia of unknown origin cannot be undermined. Bone trephine of patients presenting with pyrexia of unknown origin must be carefully looked upon for granulomas for evaluation of tuberculosis. In this case, bone marrow trephine aided in timely diagnosis of tuberculosis in a patient.

Keywords: Bone trephine; Granulomas; Tuberculosis; Bone marrow

Citation: Karim F, Qadir H. Tuberculous Granuloma on Bone Marrow Trephine. J Ayub Med Coll Abbottabad 2018;30(4 Supple 1):671-2.

INTRODUCTION

Tuberculosis is still a common health problem in many developing countries. Bone marrow trephine is a useful tool for diagnosis of tuberculosis.¹ Bone marrow of patients presenting with pyrexia of unknown origin must carefully be looked upon for any granulomas for evaluation of tuberculosis.² Here, we report an interesting case of a middle-aged female whose bone marrow trephine biopsy showed collection of Langhan giant cells and greatly aided in her diagnosis.

CASE REPORT

A 54 years old woman presented with history of weight loss and low-grade fever for one year. Examination revealed mild hepatosplenomegaly.

Complete blood count showed Haemoglobin: 12.7 gm/dl, WBC: $2.9 \times 10^9/L$ and Platelets: $59 \times 10^9/L$. Bone marrow biopsy was done for workup. Bone marrow aspirate was cellular with trilineage haematopoiesis. Bone trephine showed normal cellularity for age. The significant feature on trephine was focal collection of epithelioid macrophages with some Langhans giant cells. On immunohistochemistry these cells stained positive with CD 68 (as shown in image) and were negative for CD 1a. ZN stain for acid fast bacilli and PAS stain were negative.

Based on clinical suspicion and bone marrow findings, patient was suspected of having tuberculosis and culture was done. She was started on Anti-Tuberculosis treatment after taking culture sample. The patient responded well to it. Later, the culture results came out to be positive and confirmed the diagnosis.

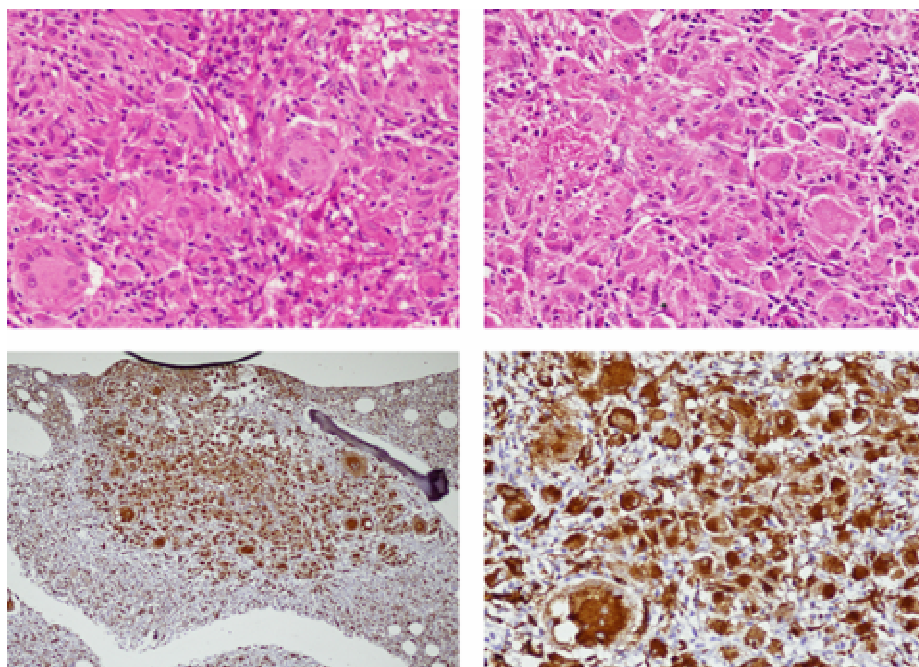


Figure-1: Collection of Langhan Giant cells on Bone trephine (Above) with positive staining for CD 68 (Below)

DISCUSSION

Granulomas in bone marrow are an uncommon feature and are related to various disorders.³ A granuloma is a site of chronic inflammation showing collection of macrophages that are surrounded by a rim of lymphocytes and plasma cells.⁴ Granulomas are seen on bone marrow trephine in 15–40% of patients with miliary tuberculosis. Tuberculous granulomas usually have Langhans type of giant cells.⁴ Caseation is seen in around 50% of cases. Acid fast bacilli cannot be demonstrated in most cases.⁵ In this case, we observed marrow granuloma with Langhan giant cells. Bone marrow examination in this case helped in timely diagnosis and treatment of patient while culture was awaited. This shows the importance of bone marrow examination and the valuable information it provides.

Conflict of Interest: There is no conflict of Interest

REFERENCES

1. Toi PCh, Varghese RG, Rai R. Comparative evaluation of simultaneous bone marrow aspiration and bone marrow biopsy: an institutional experience. *Indian J Hematol Blood Transfus* 2010;26(2):41–4.
2. Lin SH, Lai CC, Huang SH, Hung CC, Hsueh PR. Mycobacterial bone marrow infections at a medical centre in Taiwan, 2001–2009. *Epidemiol Infect* 2014;142(7):1524–32.
3. Brackers de Hugo L, Ffrench M, Broussolle C, Sève P. Granulomatous lesions in bone marrow: clinicopathologic findings and significance in a study of 48 cases. *Eur J Intern Med* 2013;24(5):468–73.
4. Kumar SN, Prasad TS, Narayan PA, Muruganandhan J. Granuloma with langhans giant cells: An overview. *J Oral Maxillofac Pathol* 2013;17(3):420–3.
5. Li JY, Lo ST, Ng CS. Molecular detection of *Mycobacterium tuberculosis* in tissues showing granulomatous inflammation without demonstrable acid-fast bacilli. *Diagn Mol Pathol* 2000;9(2):67–74.

Received: 19 Jun, 2017

Revised: --

Accepted: 25 Nov, 2018

Address for Correspondence:

Farheen Karim, Department of Pathology and Laboratory Medicine, Aga Khan University, Karachi-Pakistan

Email: farheen.mahar@aku.edu