

## ORIGINAL ARTICLE

## HISTOLOGICAL COMPARISON OF TWO STAINING METHODS IN IDENTIFICATION OF MYCOBACTERIUM TUBERCULOSIS IN GRANULOMATOUS LYMPHADENITIS

Fiaz Ahmad, Abdur Rehman\*, Omair Jadoon\*\*

Department of Pathology, \*Oral Pathology, \*\*Forensic Medicine Ayub Medical College, Abbottabad-Pakistan

**Background:** Tuberculosis, among human bacterial infections is very important disease of modern world and disease has forensic importance. Extra pulmonary infection is also very common. Histopathology of effected tissue is an important diagnostic modality. Demonstration of mycobacterium tuberculosis in granulomas is necessary for definitive diagnosis of tuberculosis, as many different granulomatous diseases may mimic tuberculosis. Study was conducted to see the positivity of mycobacterium tuberculosis in tuberculous lymphadenitis and comparative difference in two stains. **Method:** A correctional study on tuberculosis was performed in PGMI Lahore in collaboration with pathology department Ayub medical college Abbottabad. Fifty cases of formalin fixed paraffin embedded tissue block previously diagnosed as tuberculous lymphadenitis on histopathology were selected. Three-micron thick section were taken and stained with Zn stain and Auramin/ Rhodamin stain. The results were compared; statistical analysis was done using 2×2 table. **Results:** Out of 33(66%) female and 17 (34%) male patients ranging from 9–80 years 9 (18%) were positive for Mycobacterium Tuberculosis with Zn stain and 21 (42%) were positive in Auramine/ Rhodamine staining procedure. **Conclusion:** Auramine/ Rhodamine staining procedure was superior to Zn staining method for tissue staining of Mycobacterium Tuberculosis. **Keywords:** *Mycobacterium tuberculosis*; Auramin/Rhodamin stain; ZN stain

**Citation:** Ahmad F, Rehman A, Jadoon O. Histological comparison of two staining methods in identification of mycobacterium tuberculosis in granulomatous lymphadenitis. J Ayub Med Coll Abbottabad 2018;30(2):159–62.

### INTRODUCTION

Tuberculosis is an important infectious disease of human beings from the time immemorial.<sup>1</sup> In the modern times it has been seen to re-emerge with drug resistance.<sup>2</sup> Mycobacterium tuberculosis is responsible for infecting 10 million cases each year. Approximately 2 million people die of tuberculosis each year.<sup>3</sup> In Pakistan; it is a major health problem. According to WHO report.<sup>4</sup> It shows a total prevalence of 376/lack/year for the year 2012.

Mycobacterium tuberculosis commonly infects human lung but extra-pulmonary tuberculosis is not less common and infects almost all tissues of the body. Importantly tuberculosis in all locations is equally serious and even fatal.<sup>5</sup>

Mycobacterium tuberculosis is a member of M. tuberculosis complex which comprises of 9 closely related strains that infect humans in different parts of the world.<sup>6</sup> It is a non-motile rod first discovered in 1882 by Robert Koch.<sup>7</sup> It stains with difficulty but once stained it resists decolorization with weak acids and alcohols. Due to this property it is termed as acid fast bacillus (AFB).<sup>8</sup> This property of alcohol fastness and acid fastness is due to its special cell wall.<sup>9</sup> Recent techniques like nuclear magnetic resonance (NMR) and mass spectral analysis have resulted in thorough understanding of this structure along with interpretation of M. Tuberculosis genome.<sup>10</sup> The wall as understood

today comprises of a peptidoglycan covalently attached via a linker unit to a linear galactofuran which in turn is attached to several strands of highly branched arabinofurans. The arabinofurans are then attached to mycolic acids.<sup>10,11</sup> Within this lipid environment provided by mycolic acid are other lipids like cord factor and sulphatides etc which are responsible for pathogenicity of this organism.<sup>10</sup> Mycolic acids are  $\alpha$  alkyl  $\beta$  hydroxyl fatty acids with exceptional long chains. Chain lengths may vary but may be up to 80 carbon atoms. In M tuberculosis, they are characterized by very hydrophobic C<sub>54</sub> to C<sub>63</sub> fatty acids with C<sub>22</sub> to C<sub>24</sub>  $\alpha$  side chains.<sup>12</sup> Mycolic acid content of M. Tuberculosis determines its pathogenicity and drug resistance.<sup>13</sup>

Due to this especial cell wall M. tuberculosis has special staining properties. The do not take gram stain like most other bacteria. It was the work of Paul Ehrlich, Friedrich Neelsen and Franz Ziehl that a reliable method of staining was developed after discovery of this bacillus by Robert Koch.<sup>14</sup> Staining of M. Tuberculosis in tissue is a great challenge and staining yield of this bacteria in tissue is very low.<sup>15,16</sup> Nonetheless it is more important to demonstrate M. tuberculosis in granulomas to make a definitive diagnosis of tuberculosis because of its treatable nature. Importance of demonstration of M tuberculosis in tissue is further increased by the fact that TB granulomas may

mimic leprosy, sarcoidosis and a number of fungal conditions.<sup>17</sup>

**MATERIAL AND METHODS**

This was a cross-sectional comparative study. The study was conducted in Department of Pathology PGMI Lahore in collaboration with Pathology Department Ayub Medical College Abbottabad. Samples were collected from 27<sup>th</sup> Dec 2011 to 29<sup>th</sup> Jan 2014. It was a multi-faceted study and was concluded on 18<sup>th</sup> April 2014. A total of 50 histopathologically diagnosed cases of tuberculous lymphadenopathy were included in the study. It was a non-probability purposive sampling. Patient history was taken and recorded on a proforma. Those patients with proven tuberculosis on histopathology and without any concomitant disease were selected. Tissues were routinely processed and wax embedded. Three-micron thick sections were taken and stained for H & E Zn and Auramin/ Rhodamin stain. H & E and Zn stained sections were studied under light microscope Olympus model CH. Auramin/ rhodamin stained section was studied under BHS-BH<sub>2</sub> Olympus with florescent attachments. Sections were studied under ultraviolet excitation frequency of 490° A.

Both Zn & Auramin /Rhodamin stained sections were visualized with 100X oil emersion lens in their respective microscopes. Presence of *M. tuberculosis* as red rods in ZN stain and Greenish yellow fluorescence in Auramin/Rhodamin stain was taken as positive for staining.

**RESULTS**

Out of the 50 diagnosed cases 17 were males and 33 were females (Figure-1). Patients had an age range of 9–80 (Figure-2) years with a mean age of 26–86±13 years. Eighteen presents (18%) of the cases were positive for AFB on ZN Staining and 42% were positive by Auramin/Rhodamin stain (Figure-3).

All the cases detected by ZN stain were picked up by Auramin/Rhodamin stain. Statistical analysis was done by using 2×2 table. Results of two stains were compared and calculated and was seen that Auramin/Rhodamin stain was significantly better than ZN stain. The *p*-value calculated was 0.0008 was less than .05 hence was significant.

	+iv	-iv	
ZN stain	9	41	50
Auramin/ Rhodamin stain	21	29	50
	30	70	

As we have two rows and two columns, calculated degree of freedom is 1. Taking *p* value at less than

0.05 the expected chi square value should be above 3.84. Our calculated value is 6.88 giving a *p* value of 0.00088. This value is less than 0.05 hence highly significant. It proves that Auramine/Rhodamine is a better stain then ZN stain for tissue staining of *M. Tuberculosis*.

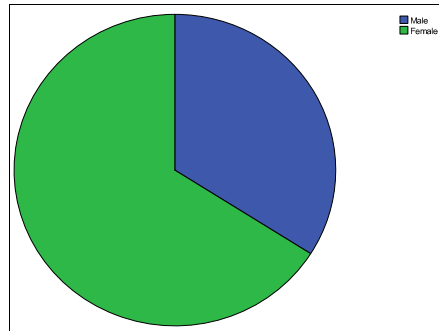


Figure-1: Sex of the patient

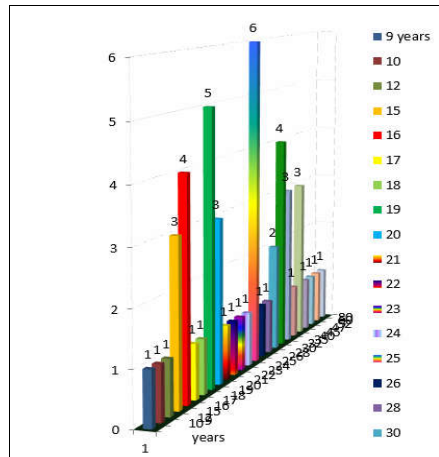


Figure-2: Age of the patients

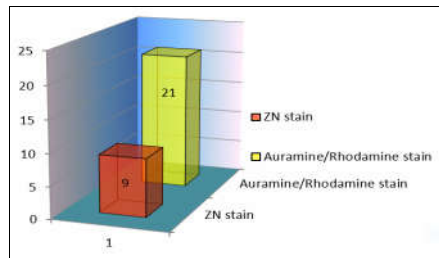


Figure-3: Stain positivity

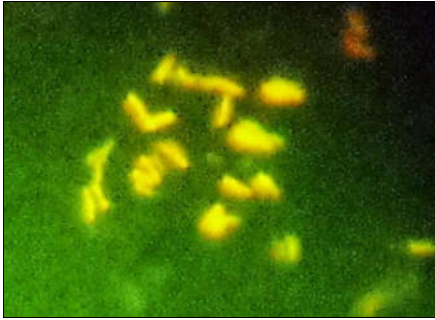


Figure-4: M. Tuberculosis Auramin/Rhodamin stain

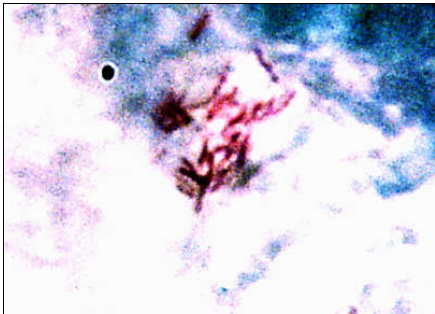


Figure-5: M. Tuberculosis in ZN Stain

## DISCUSSION

Tuberculosis is an important disease of past and modern times.<sup>18</sup> It is an important problem of developing countries and becomes more important when coexists with AIDS.<sup>19</sup> Extra pulmonary TB is common in Pakistan. Among other diagnostic modalities biopsy is a slandered procedure and test. For definitive diagnosis, it is essential to demonstrate M. tuberculosis in tissue sections and tuberculous lesion (granulomas) because of very large differential for tuberculosis.<sup>17</sup> Staining of AFB in tissue is difficult and positive yield is low.<sup>16</sup> To overcome this difficulty different stains have been tried with variable success. Current study focuses on Routine zn stain and Auramin/ Rhodamin stain.

Results of our study shows that 86% of the patients were below the age of 40 years this in consistence with many previous studies as Muynck *et al.*<sup>20</sup> This also shows more trend of spread in younger people. Our study shows a higher preponderance in female (66%). this is in accordance with regional study conducted by Mukherjee *et al.*<sup>16</sup> in India. However, the WHO report<sup>4</sup> contradicts the findings of our study by narrating a lower prevalence of TB in

females in Pakistan but admits that it may be underestimated because of local customs.

Our study shows a 18% positivity of AFB in ZN staining method. Pawal *et al.*<sup>21</sup> have shown 22% positivity which is close to the findings of our study. Karimi *et al.*<sup>22</sup> has shown that ZN stain is a low sensitivity low specificity stain and further narrated that results in different case series are variable ranging from zero to 40%. These results are consistent with the results of our study. Mukherjee *et al.*<sup>16</sup> in his study shows a positivity rate of 44% which are higher in comparison to our study. This could be because of immunosuppression prevalent in India due to poverty and higher prevalence of AIDS in India but he himself admits that it varies between 23–65 in different age groups.

Our study shows 42% positivity for Auramine/Rhodamin stain. Results of our study are lower than Sherestha *et al.* who claims 71% positivity with Auramin/Rhodamin stain. It is remarkable that the cases he considered were all culture positive. His gross positivity disregarding culture was 36% close to the findings of our study. Ghenaat *et al.*<sup>23</sup> has claimed a positivity of 26% with Auramine/Rhodamine stain in his study. His sample size was 40 cases 20% less than our study this might be the cause of low yield in his study.

During the study period, I visited many centres of histopathology in the country and have observed that inspite of the importance of demonstration of AFB in granulomas, staining for the same is not a standard practice. This may be because of low sensitivity of AFB in ZN staining procedure and lack of florescent microscope facility or poisonous nature of Auramine/ Rhodamin stain<sup>24</sup> that requires strict safety protocol.

## AUTHORS' CONTRIBUTION

FA: Data collection, data analysis. OJ: Data Analysis, Discussion. AR: Staining procedure, Tissue processing.

## REFERENCES

1. Zink AR, Sola C, Reischl U, Grabner W, Rastogi N, Wolf H, *et al.* Characterization of Mycobacterium tuberculosis complex DNAs from Egyptian mummies by spoligotyping. J Clin Microbiol 2003;41(1):359–67.
2. Espinal MA, Laszlo A, Simonsen L, Boulhalal F, Kim SJ, Reniero A, *et al.* Global trends in resistance to antituberculosis drugs. World Health Organization-International Union against Tuberculosis and Lung Disease Working Group on Anti-Tuberculosis Drug Resistance Surveillance. N Engl J Med 2001;344(17):1294–303.
3. El-Kebir M. Modeling Tuberculosis in Lung and Central Nervous System; Vrije Universiteit Amsterdam; 2010.
4. Organization WH. Global tuberculosis report 2013: World Health Organization; 2013.
5. Ozvaran MK, Baran R, Tor M, Dilek I, Demiryontar D, Arinc S, *et al.* Extrapulmonary tuberculosis in non-human

- immunodeficiency virus-infected adults in an endemic region. *Ann Thorac Med* 2007;2(3):118–21.
6. Sebban M, Mokrousov I, Rastogi N, Sola C. A data-mining approach to spacer oligonucleotide typing of *Mycobacterium tuberculosis*. *Bioinformatics* 2002;18(2):235–43.
  7. Sakula A. Robert Koch: centenary of the discovery of the tubercle bacillus, 1882. *Can Vet J* 1983;24(4):127–31.
  8. Allen JL. A modified Ziehl-Neelsen stain for mycobacteria. *Med Lab Sci* 1992;49(2):99–102.
  9. Chandrasekhar S, Ratnam S. Studies on cell-wall deficient non-acid fast variants of *Mycobacterium tuberculosis*. *Tuber Lung Dis* 1992;73(5):273–9.
  10. Brennan PJ. Structure, function, and biogenesis of the cell wall of *Mycobacterium tuberculosis*. *Tuberculosis (Edinb)* 2003;83(1–3):91–7.
  11. Bhamidi S, Scherman MS, Jones V, Crick DC, Belisle JT, Brennan PJ, *et al.* Detailed structural and quantitative analysis reveals the spatial organization of the cell walls of in vivo grown *Mycobacterium leprae* and in vitro grown *Mycobacterium tuberculosis*. *J Biol Chem* 2011;286(26):23168–77.
  12. Takayama K, Wang C, Besra GS. Pathway to synthesis and processing of mycolic acids in *Mycobacterium tuberculosis*. *Clin Microbiol Rev* 2005;18(1):81–101.
  13. Yuan Y, Mead D, Schroeder BG, Zhu Y, Barry CE 3rd. The biosynthesis of mycolic acids in *Mycobacterium tuberculosis*. Enzymatic methyl(ene) transfer to acyl carrier protein bound meromycolic acid in vitro. *J Biol Chem* 1998;273(33):21282–90.
  14. Sakula A. Robert Koch: centenary of the discovery of the tubercle bacillus, 1882. *Thorax* 1982;37(4):246–51.
  15. Kohli R, Punia RS, Kaushik R, Kundu R, Mohan H. Relative value of immunohistochemistry in detection of mycobacterial antigen in suspected cases of tuberculosis in tissue sections. *Indian J Pathol Microbiol* 2014;57(4):574–8.
  16. Mukherjee A, Kalra N, Beena K. Immunohistochemical detection of mycobacterial antigen in tuberculous lymphadenitis. *Indian J Tuberc* 2002;49(4):213–6.
  17. Mukhopadhyay S, Gal AA. Granulomatous lung disease: an approach to the differential diagnosis. *Arch Pathol Lab Med* 2010;134(5):667–90.
  18. Gutierrez MC, Brisse S, Brosch R, Fabre M, Omais B, Marmiesse M, *et al.* Ancient origin and gene mosaicism of the progenitor of *Mycobacterium tuberculosis*. *PLoS Pathog* 2005;1(1):e5.
  19. Agudelo CA, Restrepo CA, Molina DA, Tobon AM, Kauffman CA, Murillo C, *et al.* Tuberculosis and histoplasmosis co-infection in AIDS patients. *Am J Trop Med Hyg* 2012;87(6):1094–8.
  20. De Muynck A, Siddiqi S, Ghaffar A, Sadiq H. Tuberculosis control in Pakistan: critical analysis of its implementation. *J Pak Med Assoc* 2001;51(1):41–7.
  21. Pawal J, Puranik R, Kulkarni MH. A histopathological study of granulomatous inflammations with an attempt to find the aetiology. *J Clin Diagn Res* 2011;5(2):301–6.
  22. Karimi S, Shamaei M, Pourabdollah M, Sadr M, Karbasi M, Kiani A, *et al.* Histopathological findings in immunohistological staining of the granulomatous tissue reaction associated with tuberculosis. *Tuberc Res Treat* 2014;2014:858396.
  23. Ghenaat J, Omid A, Ghazvini K, Ayatollahi H, Hossein Jafarian A. Comparison of Multiplex PCR and Acid fast and Auramine-Rhodamine staining for detection of *Mycobacterium tuberculosis* and nontuberculous *Mycobacteria* in Paraffin-Embedded pleural and bronchial tissues with granulomatous inflammation and caseous necrosis. *Internet J Microbiol* 2006;4:4–7.
  24. Apan TZ, İşeri L, Köksal F. The Comparison between the Modified Auramine Rhodamine Fluorochrome Staining and Ziehl-Neelsen Staining Method from Sputum Specimens in the Presence with Radiometric Bactec Tb System. *KU Tip Fak Derg* 2011; 13(1):24–9.

Received: 14 July, 2017

Revised: 4 March, 2018

Accepted: 11 March, 2018

**Address for Correspondence:**

**Fiaz Ahmad**, Asstt. Prof. Department of Pathology, Ayub Medical College, Abbottabad-Pakistan

**Email:** tanolilion@yahoo.com