

## CASE REPORT

# MALIGNANT SACROCOCCYGEAL YOLK SAC (ENDODERMAL SINUS) TUMOR

Tariq Mufti\*, M.Saeed Khan\*\*\*, Muzher-U- Dua\*\* and Farah Waqar\*\*

Departments of Surgery\* and\*\*Oncology Ayub Teaching Hospital, Abbottabad and \*\*\*Institute of Nuclear Medicine Oncology & Radiotherapy (INOR), Abbottabad

We report a 2 ½ years old female child who presented with Malignant Sacrococcygeal Yolk sac (Endodermal Sinus) tumor as presacral mass with ulceration of overlying skin. Her ultrasonography (USG)abdomen revealed a huge preseacral mass with irregular margins extending in to the pelvis, pushing the rectum antero-laterally. CT scanning of abdomen confirmed USG finding with out enlargement of retroperitoneal lymph nodes and no involvement of the liver. Serum AFP was abnormally elevated. The tumor was excised along with Coccyx in-toto through posterior approach dividing the sacrum and 3-Drugs (VAC) Chemotherapy started post-operatively i.e. 2-weeks after surgery. Here we discuss our experience with this extremely rare malignant extra-gonadal germ-cell tumor and review of literature.

*'We can say with some assurance that although children may be victims of fate, they will not be the victims of our neglect (John F Kennedy)<sup>(1)</sup>'*

## INTRODUCTION

Malignant sacrococcygeal Yolk sac (Endodermal Sinus) tumor is an extremely rare extra-gonadal germ cell tumor found in infants and children. Although, most yolk sac tumors present as infantile testicular tumors yolk sac tumors occurring as pure or mixed germ cell tumors are rather common in the ovaries of young girls and in several extra-gonadol sites including the sacro-coccygeal area, pelvis, mediastinum, stomach, retro-peritoneum, vagina and brain<sup>2</sup>.

Sacro-coccygeal yolk sac tumors of infant and children reflect the transformation of primordial cells that have failed to migrate to their pre-destined location. Toti-potent germ cells normally arise from the Yolk sac of the 04 weeks old human embryo and migrate along the Gonadal ridge before their final decent in to the pelvis. During embryogenesis, some of these cells fail to complete migration and come to rest along the dorsal mid-line of the embryo. The primordial germ cells give rise to an un-differentiated germ cell line. The un-diff-germ cell undergoes differentiation into embryonic (somatic cells) or extra –embryonic cells of Yolk sac, chorion & allantoin cells.<sup>3,8</sup>

Malignant transformation of these cells give rise to tumors that reflect their embryonic features. Tumors of extra-embryonic cells have trophoblastic features as in chorio-carcinoma or characteristic of yolk sac endoderm etc. as shown in Fig-1.<sup>3</sup>

## CASE REPORT

The parents of this young baby gave history of appearance of painless swelling over sacral region with gradual increase in size of 5-6 months duration. The child was taken to the nearest doctor. A biopsy piece was taken for laboratory diagnosis. The histopathology report (AFIP) revealed Malignant Yolk sac (endodermal sinus) tumor. The patient was referred to Ayub Teaching Hospital Complex (ATHC), Abbottabad for necessary treatment. Where she got admitted in Surgical-A unit. Her USG abdomen revealed a huge (solid) presacral mass with irregular margins extending into the pelvis pushing the rectum antero-laterally. CT scanning of abdomen also confirmed these findings. Retro-Peritoneal lymph nodes were not enlarged, no metastases in liver were reported in C.T scan. Her x-ray chest was clear. Her AFP was raised. Patient was staged as stage-II according to St. Jude Children research hospital staging system and operated i.e removing the tumor in one piece along with coccyx after dividing the sacrum through posterior approach. No serious complications occurred during surgery and her post- operative recovery was excellent.

A 3-drugs (VAC) chemotherapy was started in following dosage schedule.

1. Inj. Vincristine (VCR) 1.4 mg/m<sup>2</sup>I/V wkly. Planned for 10 X-12 doses.
2. Inj. Actinomycin-D (Cosmegen) 0.5mg i/v day 1-5 and
3. Inj. Cyclophosphamide (Endoxan) 5-7mg/kg day1-5

No. 2 & 3 to be continued at monthly interval for 1 ½ - 2 years

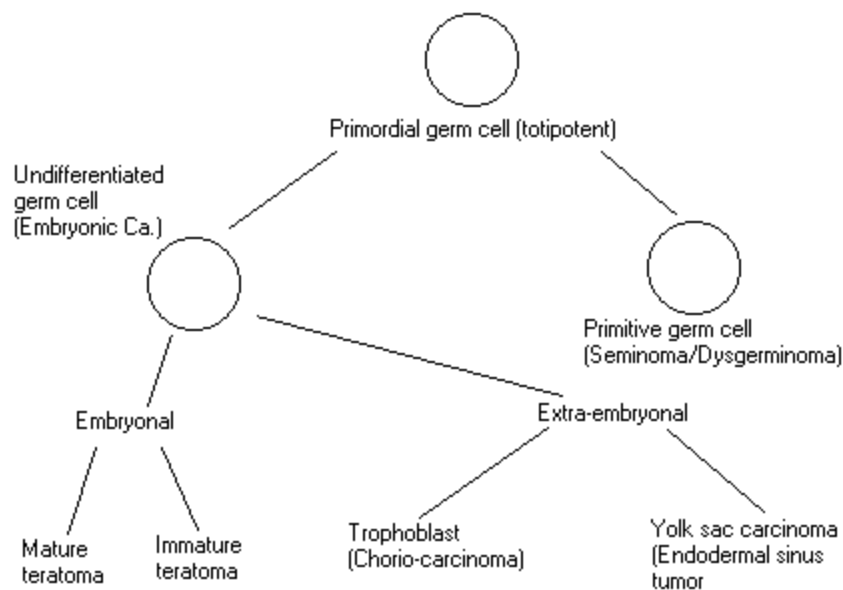


Fig-1: Schematic representation of germ cell maturation and the corresponding malignant germ cell tumors<sup>3</sup>

## DISCUSSION

Malignant extra-gonadal germ cell tumors are uncommon neoplasm accounting for approx. 3% of childhood tumors that may arise in a variety of anatomic sites<sup>3</sup>. The incidence of malignant yolk sac carcinoma is less than 1 per million per year<sup>4</sup>. The Male to Female ratio is about 1:2.5<sup>5</sup>. In a reported series by Gross-field et al<sup>6</sup> 58 of 85 (68%) patients were girls and 27(30%) were boys. The sites of origin benign and malignant in decreasing frequency were sacro-coccygeal in 55 (64.8%), mediastinal in 10 (11.7%), Gonadal in 10 (11.7%), Presacral in 4 (4.8%), retro-peritoneal in 3 (3.5%) and neck in 3(3.5%) of cases. Of the total 67 (78.8%) were benign and 18(21.2%) malignant. Site of malignant tumors were sacro-coccygeal 11 of 55 (20%), mediastinal 2 of 10(20%) , ovarian 3 of 8 (37.5%), testicular 2 of 2 (100%)<sup>5</sup>.

Sacro-coccygeal yolk sac tumors can be external or internal i.e presacral and intra-pelvic or intra-abdominal extension. Tumors that are predominantly external have a lower malignant potential than presacral that are always malignant<sup>2</sup>. For infant with external masses in the sacro-coccygeal area, the differential diagnosis must include Menin-gomyelocoele, chordoma, neurogenic tumors, Lipoma, vestigial tail and Hemingioma etc.<sup>2</sup>

In infants without external masses, a careful rectal examination is essential in the evaluation of these infants. Presacral or intra-abdominal extension of tumors occurs in 27% of patients<sup>6</sup>. Symptoms of Urinary tract or colonic obstruction are associated more often with malignant than benign tumors. Rarely, invasion of the lumbo-sacral plexus or spinal cord may result in lower extremity weakness and pain.

In Sacro-coccygeal lesions when malignancy is suspected, abdominal and chest x-rays plus sacral film are taken to look for tumor invasion or metastasis. IVP, Ba-enema, USG & CT scanning of the abdomen are obtained in patients who have malignant lesion. Patients with sacro-coccygeal lesions may have an elevated AFP which can indicate malignancy and also should predict recurrence<sup>8</sup>.

Complete surgical excision should be attempted in malignant lesion. Since complications with sacro-coccygeal lesions usually involve haemorrhage, control of the tumor vasculature is important. Failure to excise malignant lesions completely had always resulted in death from the disease. Prior to 1950, only patients with completely removed tumors survived the disease<sup>9</sup>. The outlook is improving with the use of combination chemotherapy and long-term responses are being noted<sup>7</sup>. Adjuvant VAC chemotherapy (vincristine, actinomycin-D and Cyclophosphamide) has been most extensively used in children with endodermal sinus yolk sac tumors.

The incidence of re-growth of the tumor at the primary site is extremely high in the absence of radiation<sup>10</sup>. However, in a more common yolk sac tumor of extra gonadal origin, the role of radiotherapy is less certain<sup>7</sup>. Metastatic lesions may require palliative treatment with local radiation. Patients with Sacro-coccygeal tumors have a greater probability for survival than those with tumors at other sites (50 versus 13%)<sup>11-18</sup>.

## CONCLUSION

Malignant Yolk sac (endodermal sinus) tumors are highly malignant and lethal germ cell tumors which can kill by early metastasis and rapid invasion of abdominal and pelvic structures. There is growing body of evidence documenting complete responses of metastatic and primary disease to chemotherapy with long term survival.

Therefore, it appears reasonable to conclude that all patients even those with completely resectable tumors should receive adjuvant chemotherapy.

The role of retro-peritoneal lymph nodes dissection and post-operative irradiation is not fully defined in these more common malignant yolk sac (endodermal sinus) tumors of extra-gonadal origin.

## REFERENCES

1. Straus MB. Familiar Medical quotations. Boston, Little Brown and Co. 1968.
2. Philip A, Pizzodevaid G, Poplack , Daniel, Harris and Larry Ed: In Germs cell tumors. Devita principle and practice of Oncology (4<sup>th</sup> ed ) JB Lippincott. Co. 1976
3. Reaman GH, Cohan LF: Less frequently encountered malignant neoplasms. In Levine AS (ed) cancer. Young. New-Yark Masson publ. 1982; pp 707-727.
4. Young JL, Miller RW. Incidence of malignant tumors in US children. J Pediatr 1975;86:254-258.
5. Altman RP, Reudolph JG, Lilly OR. Sacro coccygeal teratoma American academy of Paediatric. Surgical section survey. J Pediatr Surg 1974;9:389-398.
6. Grosfield JL, Ballantine TVN, Lowed AU. Benign and malignant teratomas in children. Analysis of 85 patients. Surg 1975;80: 297-305.
7. Donnellan WA, Swenson O. Benign and malignant sacro-coccygeal teratomas. Surg 1968;64: 834-846.
8. Tsuchiday, Urano Y, Eudo Y. A study of AFP in endodermal sinus tumor. J Pediatr Surg 1975;10: 501-506.
9. Albin AJ. Malignant germs cell tumors in children. Watth JM (ed) Childhood cancer frontier of Radiation and Oncology Vol. 16. Basel.S Karger 1981 pp 141-149.
10. Ein SH, Mancor K, Adeyemi SD. Malignant sacro coccygeal teratoma, endodermal sinus (yolk sac) tumors in infants in children. J Pediatr Surg 1985; 20: 473-477.
11. Albin AJ, Ramsay N, Krailo M, Atkin J, Isaacs H. Effective therapy of malignant germs cell tumors in children. A study by the children's cancer study group-1985 Asco. Abstracts :C-419.
12. Cushing BA, Phillipart AI, Brough AJ, Dass I. Eextra- gonadal endodermal sinus tumors in early childhood. Treatment responses and long term effects. Proceed. Asco 1985; 4: 242.
13. Etcubanas E, Thompson E, Rao B, Hastu. Treatment of childhood germs cell tumors (GCT). Results of prospective study. Proceed Asco 1981;4: 238.
14. Faun IG, Sampson NK, Stephen SR. PVB therapy in disseminated extra-gonadal germs cell tumors. A SWOG study. Cancer 1980;45: 2543-2549.
15. Flament F, Sechwartz I, Delons E, Cailliaud JM. Non-Seminomatous germs cell tumors in children. Multi drug therapy in stage-III-IV. Cancer 1984;54:1687-1691.
16. Grosfield JL, Billimire DF (1985): teratomas in infancy and childhood. Current problems in cancer. 1985; 9: 1-53.
17. Logothetis CJ, Samoel ML, Selig DE. Chemotherapy extra-gonadal germs cell tumors. J Clin Oncol 1981;3:316-325.
18. Thomas WJ, Dewal AB. Successful treatment of metastatic extra-gonadal yolk sac tumors in childhood. Cancer1981;48: 2371-2374.