

ORIGINAL ARTICLE

DIVERSE ANATOMICAL CONFIGURATION OF RECURRENT LARYNGEAL NERVE IN RELATION TO INFERIOR THYROID ARTERY, AN EXPERIENCE WITH 51 THYROIDECTOMIES

Nadeem Ahmed Sheikh, Shahid Farooq Khattak*, Adil Aleem, Kanwal Nadeem**

ENT Department, Combined Military Hospital, Abbottabad. *Combined Military Hospital, Multan, **Army Burn Hall College (for girls), Abbottabad-Pakistan

Background: Objective of the study is to elaborate the anatomical variants of recurrent laryngeal nerve in relation to inferior thyroid artery, encountered during thyroidectomy operation. It is descriptive, case series, conducted at the Department of Ear Nose & Throat, Combined Military Hospital, Abbottabad. The study was conducted from January 2016 to September 2017. **Methods:** Fifty-one patients underwent extra-capsular thyroidectomy in general anaesthesia. The dissection was carried out in a standard way in all patients. Recurrent laryngeal nerves were identified and exposed in every patient, and their anatomical relations were recorded in database. **Results:** Recurrent laryngeal nerve was seen over riding the ramification of inferior thyroid artery in majority of left sided dissected specimen, however on the right side the principal nerve was found to be ascending through the branches of inferior thyroid artery. **Conclusion:** Iatrogenic vocal cord paralysis has sinister implication on quality of life of the patient undergoing thyroidectomy. Anatomic variants of recurrent laryngeal nerve are well known and frequent. The disastrous outcome of inadvertent recurrent laryngeal nerve trauma can be adequately prevented by thoroughly knowing its anatomical variants, and intra-operatively identifying and exposing the principal nerves.

Keywords: Thyroidectomy; Recurrent laryngeal nerve; Anatomy; Iatrogenic; Vocal cord paralysis

Citation: Sheikh NA, Khattak SF, Aleem A, Nadeem K. Diverse anatomical configuration of recurrent laryngeal nerve in relation to inferior thyroid artery, an experience with 51 thyroidectomies. J Ayub Med Coll Abbottabad 2019;31(2):168–71.

INTRODUCTION

The history of goitre ages back to pictorial accounts from ancient highlands of the Roman empire.¹ First anatomical elaboration of the thyroid was coined in 16th century AD by Leonardo da Vinci and Andreas Vesalius. As the surgical treatment of thyroid disease evolved over centuries the related mortality and co-morbidities became obvious and called for more effective strategies to avert and manage them. It was however, in the 6th century AD, that we find earliest documented narration of voice disorder consequent to operative intervention relating the recurrent laryngeal nerve trauma.¹ Iatrogenic vocal fold paralysis has a deleterious impact on patient's quality of life. Besides excruciating respiratory embarrassment and dysphonia, it is a foremost reason of psycho-social distress for the patient.

Prevalence of recurrent laryngeal nerve trauma varies from 1.5–14%.^{2–4} Recovery is reported to take place in more than 80% in over a year.^{5,6} Local literatures also conforms to the global prevalence of iatrogenic injury to recurrent laryngeal nerve.^{7,8}

Conservation of the principal nerve during thyroidectomy exclusively relies on knowing its course, anatomical relations and its meticulous identification. Most text books merely describe recurrent laryngeal nerve to be lying either superficial or deep to the inferior thyroid artery.

However, up to twenty isolated anatomical variants have been reported.⁹

Concurrently, much work has been done in our region on describing the incidence of temporary and permanent iatrogenic vocal cord paralysis, however only sparse documentation of structural and developmental variants of recurrent laryngeal nerves in the neck has been portrayed so far. Our study aims toward highlighting the diversity in normal anatomical course and configuration of recurrent laryngeal nerve in the neck, once encountered during thyroidectomy operation. It will help the surgeons performing thyroidectomy operations to better understand the anatomy and thus carry out meticulous intervention to avoid lifelong morbidity in patients.

MATERIAL AND METHODS

Abbottabad is the capital city of Hazara division of Khyber Pakhtunkhwa. This region has an average elevation of 4500 feet above sea level. Thyroid disorders are endemic in these areas mainly due to dietary iodine deficiency. We performed extra-capsular thyroidectomy in 51 patients, who belonged to both genders and all ages.

Surgeries were performed through standard Kocher's incision. We raised the skin flaps as the dissection continued sub-platysmal till the level of thyroid notch superiorly, and till the jugular notch inferiorly. Middle thyroid veins and the superior

pedicles were ligatured and transfixed. We exposed the recurrent laryngeal nerves and defined their anatomical relation to the inferior thyroid artery, invariably in every case before dissecting through the Berry's ligament.

A record of the anatomical presentation was maintained in database. Post-operative status of both vocal cords was assessed at the time of discharge from hospital with the aid of flexible fibre optic trans-nasal laryngoscope. IBM-SPSS version-24 was used and descriptive statistics were applied to establish the frequency of each variant. Pearson bivariate correlation was applied to analyse the association between the anatomical topography of the principal nerves on either side with any incidence of post-operative ipsilateral vocal cord paralysis. *p*-value was kept at 0.05.

RESULTS

Out of our 51 patients, 82.4% (n=42) patients were females and 17.6% (n=9) were males. Mode of age was 45 years (SD±10.42), with minimum age being 24 years and maximum being 66 years. 1.9% patients (n=1) had preoperative unilateral cordal hypomotility. Chief complaints were multinodular goitre (56.9%, n=29), right sided solitary thyroid nodule (23.5%, n=12), left sided solitary thyroid nodule (9.8%, n=5), diffused goitre (7.8%, n=4), and revision thyroidectomy for malignancy (2.0%, n=1) (Figure-1).

54.9% (n=28) patients underwent total thyroidectomy. 31.4% (n=16) patients underwent subtotal thyroidectomy, 5.9% (n=3) patients had their lobectomy performed, 5.9% (n=3) had near total thyroidectomy and 2.0% (n=1) patient had undergone revision thyroidectomy. Post-operative vocal cord paralysis (if any) was not found to be associated with any of the anatomical variant on either side. Pearson bivariate correlation between the anatomical arrangement of different anatomical variants of the right and left recurrent laryngeal nerves with their corresponding inferior thyroid arteries did not carry any significant association (*p* value 0.671 and 0.839, respectively), (Tables-1 and 2).

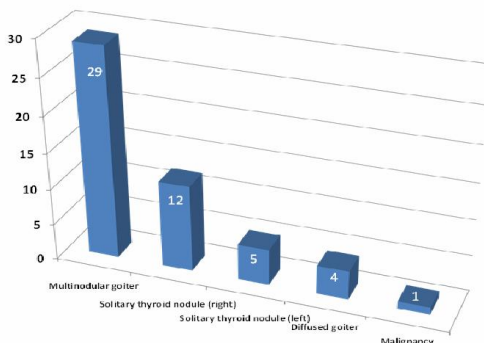


Figure-1: Indication for surgery

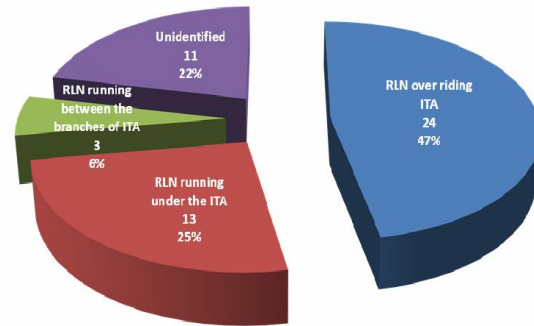


Figure-2: Left RLN relation with left inferior thyroid artery

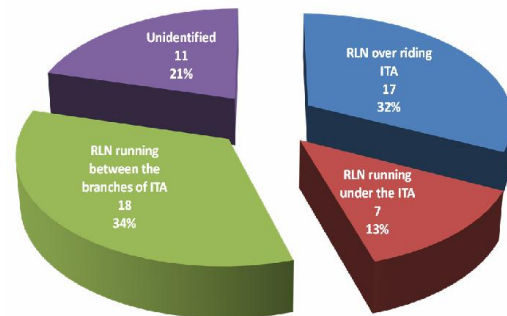


Figure-3: Right RLN relation with right inferior thyroid artery

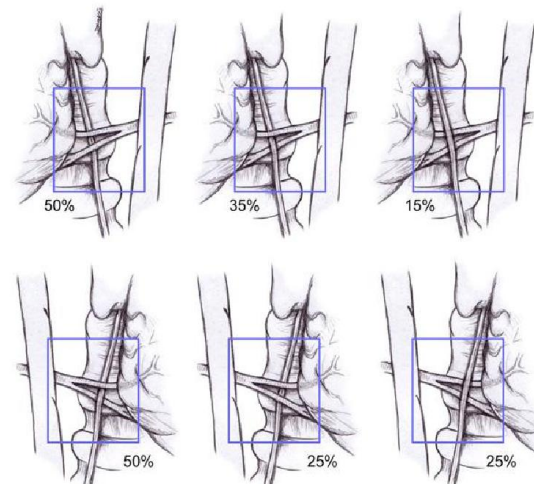


Figure-4: Normal variance in anatomy of recurrent laryngeal nerve in relation to inferior thyroid artery

Recurrent laryngeal nerve could not be identified in 22% (n=11) cases on the left, and in 21% (n=11) cases on the right side. In our majority of the operated specimens the left recurrent laryngeal nerve was found to be over riding the ramification of the left inferior thyroid artery 47% (n=24) (Figure-2). However, in most of the right sided dissected

specimens the nerve was revealed to be running between the branches of the right inferior thyroid artery 34% (n=18) (Figure-3).

On the left, in decreasing order of frequency, the recurrent laryngeal nerve was seen running under the ramification of ipsilateral inferior thyroid vessel 25% (n=13), and next, running between the branches of the left inferior thyroid artery 6% (n=3).

And further in decreasing order of frequency, the right recurrent laryngeal nerve was over riding the right inferior thyroid artery 32% (n=17), and next, the principal nerve was passing under the inferior thyroid vessel 13% (n=7).

Table-1: Statistical correlation of aberrant right recurrent laryngeal nerve with post-operative right vocal cord palsy

Correlations			
		Right RLN relation to ITA	Post-operative right vocal cord palsy
Right RLN relation to ITA	Pearson Correlation	1	.061
	Sig. (2-tailed)		.671
	n	51	51
Post-operative right vocal cord palsy	Pearson Correlation	.061	1
	Sig. (2-tailed)	.671	
	n	51	51

Table-2: Statistical correlation of aberrant left recurrent laryngeal nerve with post-operative left vocal cord palsy

Correlations			
		Left RLN relation to ITA	Post-operative left vocal cord palsy
Left RLN relation to ITA	Pearson Correlation	1	-.029
	Sig. (2-tailed)		.839
	n	51	51
Post-operative left vocal cord palsy	Pearson Correlation	-.029	1
	Sig. (2-tailed)	.839	
	n	51	51

DISCUSSION

Embryologically, at 6th gestational week, the larynx ascends cephalad, so do the recurrent laryngeal nerves. The recurrent laryngeal nerve is closely associated with the 6th branchial arch. On right the 6th arch degenerates, while on left it persists in the form of ductus arteriosus, hence the principal nerve on left turns at a lower level than its right counterpart, before ascending into tracheo-oesophageal groove. The nerve on right loops around the subclavian artery, while on left it hooks around aortic arch.

The left nerve runs parallel to the groove, while the right recurrent laryngeal nerve angles toward the groove before running parallel to it. Both nerves follow inferior thyroid artery, to lie either anterior to, posterior to or in between the branches of the latter. (Figure-4). Non-recurrent laryngeal nerve is relatively common finding on right side, where due to regression of 4th aortic arch the right subclavian artery takes a direct origin from the left side of aortic arch (since there is virtually no brachio-cephalic trunk), running retro-oesophageally to arrive on the right side at the root of the neck. Such non-recurrent right laryngeal nerve is placed high in the neck with a rather transverse course from the right vagus. Left sided non-recurrent laryngeal nerve is extremely rare and is related with situs inversus, dextrocardia or an aberrant left subclavian artery.

Thyroidectomy is usually performed to treat thyroid nodules, compression effects of multinodular goitres, endocrinal thyroid dysfunction and cosmetic reasons. In a most frequently performed surgical operation worldwide, the commonest cause of litigation is iatrogenic vocal cord palsy.¹⁰ Various mechanisms of intra-operative recurrent laryngeal nerve damage include division, laceration, stretch, pressure, crush, electrical, heat, ligature entrapment, ischemia and manipulation. Although routine identification and exposing recurrent laryngeal nerve during thyroidectomy may not pose a significant impact on post-operative hoarseness, however, the need for the surgeon to be conversant with the anatomical variants must never be underrated.^{8,11-13}

Lack of adequate plain of dissection caused by fibrosis and scarring consequent to previous operation is well known reason for iatrogenic insult to the nerve. Revision surgery of the thyroid gland leaves the operation more challenging for the surgeon in a way to prevent traumatic insult to the nerve. As an outcome 12.5% patients would suffer from temporary vocal cord paralysis and 3.8% would experience permanent cord paralysis.¹⁴ Even though achieving better theoretical understanding, preoperative laryngoscopy, refining the surgical techniques, and intra-operative nerve monitoring have declined the incidence of morbidity, yet iatrogenic recurrent laryngeal nerve trauma constitutes 46% of all thyroidectomy associated malpractice lawsuits in developed countries. Less frequent reasons are inadequate surgery (9%), hematoma formation, unclear diagnosis, delayed diagnosis (6% each) and parathyroid injury (3%).¹⁵

Foregoing in view, this may well be inferred that to pre-empt at all levels and to avoid needless per-operative damage perhaps remains the cornerstone in sparing the patient from lifelong misery. Acquaintance with theoretical knowledge, pre-operative and intra-operative evaluation and meticulous dissection whereupon, exposing the principal nerves must be exercised in all cases undergoing thyroidectomy.

CONCLUSION

Thorough awareness of anatomy, principal nerve searching, identification and exposure lessen the risk of vocal fold palsy, and must always be conducted scrupulously in all cases of sub-total and total thyroidectomy.

Acknowledgement: We deeply acknowledge the tremendous contribution of our patients, without whom we would not have been able to accomplish the objective of this project.

Conflict of interest: 'None'.

Funds: 'None'.

AUTHORS' CONTRIBUTION

NAS: Conceptualization, data collection, data analysis, data interpretation, write-up, proof reading. SFK & AA: Surgeries performed. KN: Proof reading.

REFERENCES

- Giddings AE. The history of thyroidectomy. *J Royal Soc Med* 1998;91(33 suppl):3–6.
- Friedrich T, Steinert M, Keitel R, Sattler B, Schonfelder M. The incidence of recurrent laryngeal nerve lesions after thyroid gland surgery—a retrospective analysis. *Zentralbl Chir* 1998;123(1):25–9.
- Hayward NJ, Grodski S, Yeung M, Johnson WR, Serpell J. Recurrent laryngeal nerve injury in thyroid surgery: a review. *ANZ J Surg* 2013;83(1-2):15–21.
- Zakaria HM, Al Awad NA, Al Kreedes AS, Al-Mulhim AMA, Al-Sharway MA, Hadi MA, *et al.* Recurrent laryngeal nerve injury in thyroid surgery. *Oman Med J* 2011;26(1):34–8.
- Chiang FY, Wang LF, Huang YF, Lee KW, Kuo WR. Recurrent laryngeal nerve palsy after thyroidectomy with routine identification of the recurrent laryngeal nerve. *Surgery* 2005;137(3):342–7.
- Jatzko GR, Lisborg PH, Müller MG, Wette VM. Recurrent nerve palsy after thyroid operations—principal nerve identification and a literature review. *Surgery* 1994;115(2):139–44.
- Chaudhary IA, Samiullah MR, Masood R, Majrooh MA, Mallhi AA. Recurrent laryngeal nerve injury: an experience with 310 thyroidectomies. *J Ayub Med Coll Abbottabad* 2007;19(3):46–50.
- Khan JS. Recurrent laryngeal nerve in thyroid surgery: Is routine identification necessary? *J Rawal Med Coll* 2008;12(1):16–8.
- Yalxin B. Anatomic configurations of the recurrent laryngeal nerve and inferior thyroid artery. *Surgery* 2006;139(2):181–7.
- Ready AR, Barnes AD. Complications of thyroidectomy. *Br J Surg* 1994;81(11):1555–6.
- Bergamaschi R, Becouarn G, Ronceray J, Arnaud JP. Morbidity of thyroid surgery. *Am J Surg* 1998;176(1):71–5.
- Wagner HE, Seiler C. Recurrent laryngeal nerve palsy after thyroid gland surgery. *Br J Surg* 1994;81(2):226–8.
- Rathi PK, Shaikh AR, Shaikh GA. Identification of recurrent laryngeal nerve during thyroidectomy decreases the risk of nerve injury. *Pak J Med Sci* 2010;26(1):148–51.
- Barczyński M, Konturek A, Pragacz K, Papier A, Stopa M, Nowak W. Intraoperative nerve monitoring can reduce prevalence of recurrent laryngeal nerve injury in thyroid reoperations: results of a retrospective cohort study. *World J Surg* 2014;38(3):599–606.
- Abadin SS, Kaplan EL, Angelos P. Malpractice litigation after thyroid surgery: the role of recurrent laryngeal nerve injuries, 1989–2009. *Surgery* 2010;148(4):718–23.

Submitted: 23 February, 2018

Revised: 20 December, 2018

Accepted: 30 December, 2018

Address for Correspondence:

Nadeem Ahmed Sheikh, Classified ENT Specialist, Head of ENT Department, Combined Military Hospital, Abbottabad-Pakistan.

Cell: +92 300 970 3507

Email: nadeem_ent75@yahoo.com