

## CASE REPORT

## FUNGAL INFECTION: A RARE CAUSE OF GASTRIC PERFORATION

Rohan Habib, Muhammad Waqas Afzal, Fahad Ahmed\*

Department of Surgery, \*Department of Medicine, Ayub Teaching Hospital, Abbottabad-Pakistan

Gastric perforation is among one of the common indications for a laparotomy. It can occur as a result of an erosive ulcer, long term usage of NSAIDs and malignancy among other causes. Here we report a case of a 70-year-old man with an invasive fungal infection as a cause of his gastric perforation based on histopathological evidence. Although very rare it should be kept in mind as an etiological factor of upper GI perforation especially in old age patients. To the best of our knowledge no previous data on such an association has been reported in our country.

**Keywords:** Gastric perforation; Laparotomy; Ulcer; NSAIDs; Malignancy; Fungal infection

**Citation:** Habib R, Afzal MW, Ahmed F. Fungal infection: A rare cause of gastric perforation. J Ayub Med Coll Abbottabad 2020;32(1):139-40.

## INTRODUCTION

Gastric perforation is a common cause of peritonitis leading to an emergency laparotomy.<sup>1</sup> It is a serious condition that has significant mortality and morbidity of up to 30% and 50% respectively.<sup>2</sup> According to a study 2.3% of the laparotomies due to peritonitis are because of a gastric perforation in our country.<sup>3</sup> Gastric ulceration due to *H. pylori* infection,<sup>4</sup> chronic use of NSAIDs and malignancy are considered to be the common causes of gastric perforation, while an invasive fungal infection can be an etiological factor in 10.64% of these cases.<sup>5</sup> Here we will discuss a case of a man who presented with acute peritonitis, laparotomy was performed that revealed a 2\*2cm perforation on the greater curvature of stomach and the perforation margins sent for histopathology showed growth of fungal hyphae and spores, which are considered to be a very rare cause of this disease.<sup>6</sup> The significance of reporting this case is to consider this rare etiological factor as a cause of gastric perforation, as it carries a very high mortality and needs a prompt and vigilant management plan.

## CASE REPORT

A 70-year-old male patient presented to the surgical unit with sudden onset of generalized pain abdomen since last night. The pain was more intense in the epigastrium. There was no history of peptic ulcer disease, diabetes, use of NSAIDs, antacids or any other illness. He was not weak neither immunocompromised and there was no history of tuberculosis. On examination his vitals were as follows BP 80/60, pulse rate 110/minute, temperature 100F, respiratory rate 19/minute. On performing an abdominal examination generalized guarding and rigidity were present suggesting peritonitis. His X-ray chest showed gas under right hemidiaphragm indicating a pneumo-peritoneum. Decision to perform an exploratory laparotomy was made after starting the patient on IV fluids and antibiotics. His

surgery revealed a perforation on the greater curvature of the stomach measuring 2×2 cm. Omental patch repair was performed and a sample from the margin of the perforation was taken for histopathology. The patient was shifted to the ward and was started on IV cefoparazone 2g BD, IV analgesics, maintenance fluids and was kept NPO for three days. The report of his biopsy specimen showed gastric mucosa with serosal exudates and fungal pseudo hyphae with spores with a positive PAS stain, it was negative for malignancy thus suggesting an invasive fungal infection to be the cause of this perforation. The patient was started on IV fluconazole 200 mg per day initially for five days and after an uneventful recovery he was discharged on oral fluconazole for two weeks.

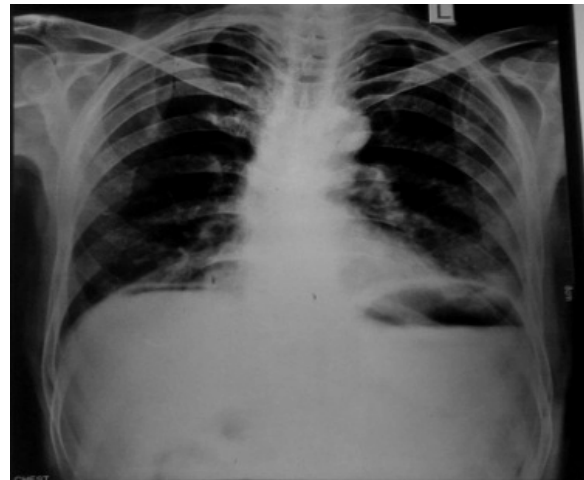


Figure-1: Pneumoperitoneum

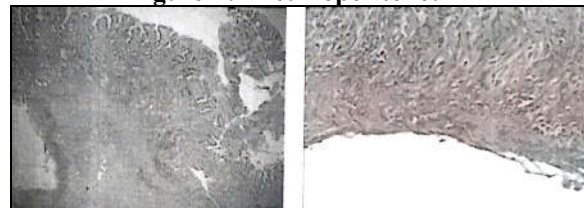


Figure-2: Fungal hyphae and spores

## DISCUSSION

Gastric perforation is usually associated with peptic ulcer disease, malignancy, smoking, alcoholism, chronic use of NSAIDs but very rarely attributed to an invasive fungal infection. It has been previously reported to be a cause of gastric perforation in diabetics, immunocompromised, debilitated patients and individuals on long term antacid use.

Apart from these factors it can occur in apparent healthy old individuals as well. It should be kept in mind as an etiological factor of gastric perforation hence efficient treatment can be administered in such cases starting with resuscitation, surgical repair, antibiotics and antifungals, as it has poor prognosis with a mortality reaching up to as high as 60%.<sup>5</sup>

## REFERENCES

1. Soreide K, Thorsen K, Harrison EM, Bingener J, Moller HM, Ohene-Yeboah M, *et al.* Perforated peptic ulcer. *Lancet* 2015;386(10000):1288–98.
2. Moller MH, Adamsen S, Thomsen RW, Moller AM. Multicentre trial of a preoperative protocol to reduce mortality in patients with peptic ulcer perforation. *Br J Surg* 2011;98(6):802–10.
3. Afridi SP, Malik F, Rahman S, Shamim S, Samo KA. Spectrum of perforation peritonitis in Pakistan: 300 cases Eastern experience. *World J Emerg Surg* 2008;3(1):31–6.
4. Huang J, Sridhar S, Hunt R. Role of Helicobacter pylori infection and non-steroidal anti-inflammatory drugs in peptic-ulcer disease: A meta-analysis. *Lancet* 2002;359(9231):14–22.
5. Minj AA, Kerketta ZH, Bakey SC, Murari K, Bodra P, Malua S. A prospective study of gastric perforation due to fungal infection in RIMS Ranchi Jharkhand. *J Dent Med Sci* 2018;17(4):32–5.
6. Bakhshi GD, Borisa AD, Shaikh AS, Thadeshwar NR, Kher Y, Kapadnis LA, *et al.* Invasive gastric candidiasis with perforation. *Bombay Hosp J* 2011;53(2):264–65.
7. Gupta N. A Rare Cause of Gastric Perforation-Candida Infection: A Case Report and Review of the Literature. *J Clin Diagn Reg* 2012;6(9):1564–5.

*Submitted: April 30, 2019*

*Revised: October 16, 2019*

*Accepted: October 31, 2019*

### Address for Correspondence:

**Rohan Habib**, Surgical A unit, Ayub Teaching Hospital Abbottabad-Pakistan

**Email:** rohan\_habib199@yahoo.com